

Xiaojin Pill with natural musk in the treatment of plasma cell mastitis

Li Peng¹, Hao Zhang¹, Xiao Xiao¹, Weijie Yang², Ruidie Li³, Xin Chen*

¹Department of Endocrine and Breast Surgery, The First Affiliated Hospital, Chongqing Medical University, Chongqing, China

²Department of Breast and Thyroid Surgery, GuiQian International General Hospital, Guizhou, China

³Department of General Surgery, The Sixth People's Hospital of Chengdu, Sichuan, China

*Corresponding author

Xin Chen, Department of Endocrine and Breast Surgery, The First Affiliated Hospital, Chongqing Medical University, Chongqing, China.

Submitted: 04 Oct 2021; Accepted: 11 Oct 2021; Published: 20 Oct 2021

Citation: Li Peng, Hao Zhang, Xiao Xiao, Weijie Yang, Ruidie Li and Xin Chen (2021) Xiaojin Pill with natural musk in the treatment of plasma cell mastitis. *Int J Cancer Res Ther*; 6 (3):87-90.

Abstract

Introduction: Plasma cell mastitis is a rare benign suppurative disease of the breast based on the dilatation of mammary ducts and infiltration of plasma cells. Modern medicine focuses on surgical treatment. It is easy to recur after operation. Xiaojin Pill with natural musk is a oral traditional Chinese medicine and plays a role in benign breast diseases. There are very few reports on the use of Xiaojin Pill with natural musk in treating plasma cell mastitis yet.

Cases: This paper reports 3 cases of plasma cell mastitis who received Xiaojin Pill with natural musk treatment. Patients were successfully treated after accepting Xiaojin Pill with natural musk for several weeks.

Keywords: plasma cell mastitis, Xiaojin Pill with natural musk, traditional Chinese medicine, treatment

Introduction

Plasma cell mastitis (PCM) is an aseptic inflammation breast disease is and characterized by the duct dilation and plasma cell infiltration [1]. The etiology of PCM remains unclear, including congenital nipple malformation, infection, endocrine disorders, autoimmune diseases, etc [2]. The main symptoms are pain and palpable mass [3, 4]. In China, ultrasound is widely used to diagnose PCM for it is convenience, safe and cheap. The accuracy is 82.0% [5]. The most common ultrasonographic were heterogeneous hypoechoic irregular mass with posterior acoustic enhancement [4].

The treatments of PCM are surgery and conservative therapies. Drainage of abscess, local excision and even total resection are chosen as initial therapy or further intervention after conservative treatment [6]. Although the treatment period is shortened, surgery makes a unsatisfied breast shape and cause physical and mental harm for patients. The conservative therapies contain antibiotics, hormones, immunotherapy and traditional Chinese medicine (TCM). Empiric anti-infectious therapy is used for patients with suspicious infection [7]. But the effective rates are low rang-

ing from 6 to 21% [8]. When antibiotics failed, patients may benefit from anti-tuberculous therapy due to atypical mycobacteria infection [9, 10]. Glucocorticoid also contributes to PCM treatment by reducing inflammatory exudation [11]. However, long-term and high-dose using of drugs above-mentioned have adverse reactions [8]. Recently, Sinomenine hydrochloride is reported as an immunotherapy by inhibiting IL-6/JAK2/STAT3 cascades [6, 12]. But further research is needed.

It is proved that oral Chinese medicine combined with western medicine is effective and safe for PCM [13]. Xiaojin Pill has been reported to treat benign breast diseases. It can dissolve masses, remove blood stasis and relieve pain [14]. Nevertheless there are few reports on Xiaojin Pill with natural musk of PCM treatment.

We present 3 cases of PCM that have been effectively treated.

Case 1

A 40-year-old woman was found redness of the right breast skin and clinical diagnosed with mammary abscess in August 2020. Durative pain and palpable mass in the right breast appeared later.

Outpatient follow-up was applied after incision and drainage of breast abscess in October 2020, ultrasound showed mammary duct ectasia, several anechoic areas, low-echo content, posterior acoustic enhancement, irregular shape, the largest lesion is 21x13mm in size towards the 12 o'clock position in the right breast (Figure 1). The diagnosis was the local recurrence of plasma cell mastitis with abscess formation.

The patient started taking Xiaojin Pill with natural musk to apply 14 days as a course of treatment (dose of 1.2g, twice a day). Re-examination of ultrasound in January 2021 after a course of treatment.

It showed a anechoic area, 33x10mm in size towards the 12 o'clock position under the right breast skin (Figure 2). She continued the second course, and ultrasound performed in April 2021 showed a lesion of mainly low echo, striped moderately strong echo content, irregular contour, 6.4 x 5.7mm in size towards the 12 o'clock position in the right breast (Figure 3). She continued the third and fourth course of Xiaojin Pill with natural musk. Ultrasound in August 2021 showed a anechoic lesion, echo heterogeneity content, irregular contour, poorly-defined border, 9.4 x 6.0mm in size towards the 12 o'clock position in the right breast (Figure 4). The patient is still taking Xiaojin Pill with natural musk and intends to continue outpatient follow-up.

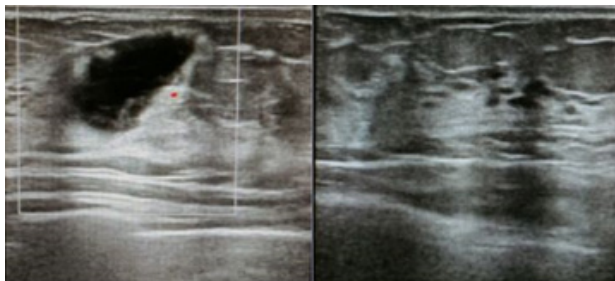


Figure 1: The image shows several circumscribed heterogenous, predominantly cystic areas, 21 x 13mm in size.

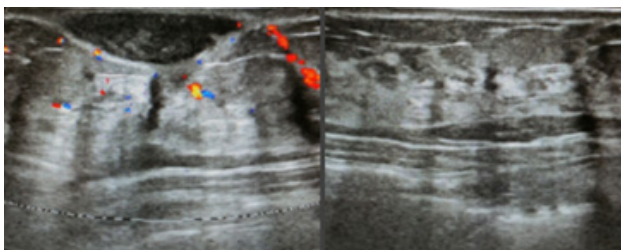


Figure 2: The image shows a circumscribed heterogenous, predominantly cystic area, 33 x 10mm in size.

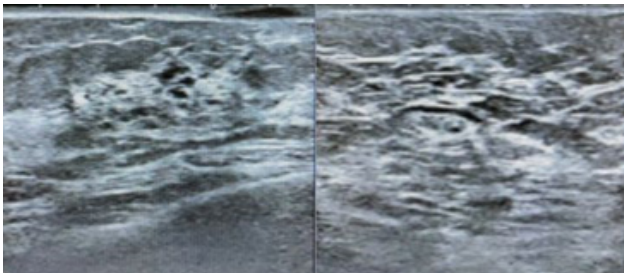


Figure 3: The image shows a circumscribed heterogenous, pre-

dominantly solid with cystic area, 6.4 x 5.7mm in size.

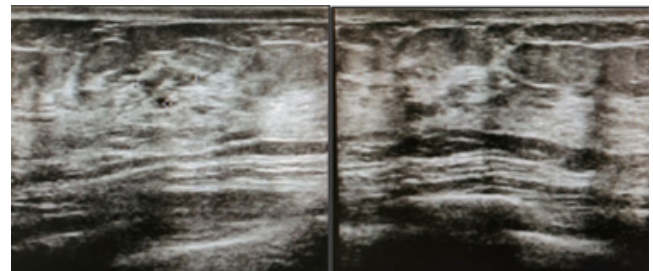


Figure 4: The image shows a circumscribed heterogenous, predominantly solid with cystic area, 9.4 x 6.0mm in size.

Case 2

A 47-year-old woman diagnosed with PCM during routine examination. She had no obvious symptoms. Ultrasound performed in March 2020 showed several lesion of mainly low echo, posterior acoustic enhancement, irregular shape, the largest lesion is 3.7x2.3mm in size below left nipple(Figure 5). She took Xiaojin Pill with natural musk to apply 14 days as a course of treatment (dose of 1.2g, twice a day). Re-examination of ultrasound in April 2020. It performed in April 2020 were normal(Figure 6).

The PCM does not recur so far.

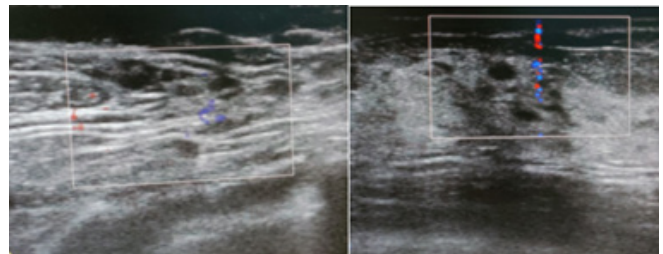


Figure 5: The image shows a circumscribed heterogenous, predominantly solid area, 3.7 x 2.3mm in size.

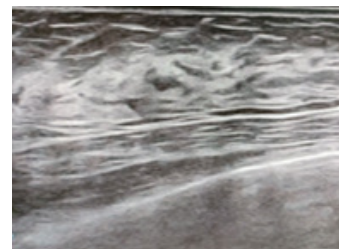


Figure 6: The image shows normal of breast.

Case 3

A 25-year-old woman diagnosed with PCM during clinic following up. She had the history of PCM in 2019, which cured by Xiaojin Pill with natural musk. Ultrasound performed in October 2020 showed a lesion of mainly low echo, striped moderately strong echo content, irregular contour, 16 x 6.7mm in size towards the 10 o'clock position in the right breast (Figure 7). It showed a lesion of mainly low echo, striped moderately strong echo content, irregular contour, 15.0 x 9.0 mm in size towards the 8 o'clock position in the left breast (Figure 7). She took a course of treatment with Xiaojin

Pill with natural musk for 14 days (dose of 1.2g, twice a day). Ultrasound performed in November 2020 were normal (Figure 8). There was no recurrence yet.

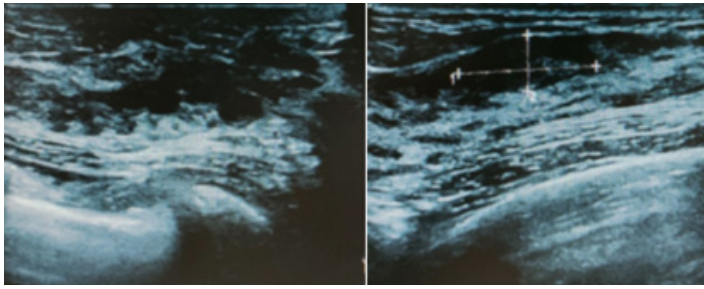


Figure 7: The image shows circumscribed heterogenous, predominantly solid area, 16.0 x 6.7 mm in size in the right breast, 15.0 x 9.0 mm in size in the left breast.

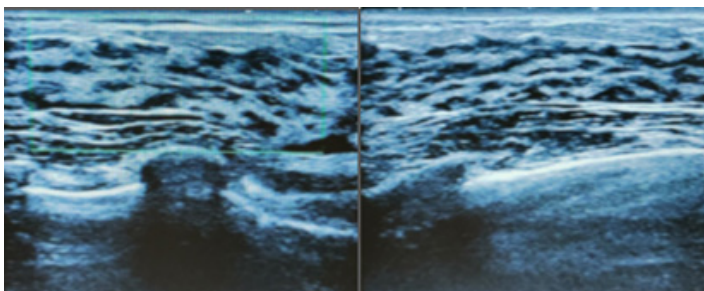


Figure 8: The image shows normal of breast.

Discussion

PCM is a rare breast disease that often occurs among middle aged women at non-lactation stage [15]. PCM is prone to form sinus or fistula and get recurring symptoms. Surgical therapy is the most radical to PCM, but it may be associated with scarring and contour deformities of the breast [16]. Surgical excision may increase the pain and psychological burden of the patients and is not accepted by all patients. Steroid hormones also contribute to PCM treatment by reducing inflammatory exudation.

They may take a 8-week to 6-month period [17]. The antibiotics, anti-tuberculous and hormones are time consuming and even with many side effects of obesity, osteoporosis, chronic gastritis and so on [11].

Immunotherapy is expensive and limited used in clinic. XiaoJin Pill originated from Wang Hongxu's "Collection of Surgical students" in the Qing Dynasty which was accepted by the 2020 edition of Chinese Pharmacopoeia (Version 2020). In recent years, it has been found that Xiaojin Pill has definite curative effect on hyperplasia, mass and abscesses of mammary [18, 19]. Its main ingredients are musk, grass black and soft-shelled turtle seed, maple balsam, myrrh, frankincense, Angelicasinensis, Wuling fat, fragrant ink, ground dragon. Musk, myrrh, earthworm, frankincense, Wulingzhi and Angelica can relieve pain, promote blood circulation and dissipate blood stasis. Natural musk resources are rare and expensive. Artificial musk production was approved by the China Ministry of Health in 1993 and replaced natural musk in 1994. Their main components are similar. But there are many unique unknown components in natural musk which may have their own

biological activity, they may produce new pharmacological active substances when compatible with other drugs [21].

Traditional medicine deems that PCM is caused by the basis of congenital nipple depression deformity and the stagnation of Liver Qi, blood stasis and phlegm-retention, inner heat generates and burns tissue into pustule, then heat poison stays after festering and perforation [22]. PCM cannot be healed for a long time. The key point of treatment is to promote blood circulation and remove blood stasis, reduce swelling and dissipate mass. Xiaojin Pill with natural musk has become the empirical drug for the treatment of PCM in our report. It may avoid unnecessary surgery to damage the breast. This report is controversial given the lack of scientific evidence due to the small number of cases. Regular monitoring is indispensable, take operations in cases with insufficient response to conservative treatment timely. The mechanism of drug action, indications and side effects of drug treatment are still needed to elucidate. Such as the mechanism of natural musk may induce new pharmacological active materials when mixed with others. It is worthy to study in the future.

Conclusion

We have reported 3 cases of PCM successfully treated by Xiaojin Pill with natural musk as primary or recurrence control therapy. We didn't find any obvious side effects. It may be considered as a new drug option for PCM.

References

1. Yang Liu, Jian Zhang, Yu Hui Zhou, Hui Min Zhang, Ke Wang, et al. (2018) Activation of the IL-6/JAK2/STAT3 pathway induces plasma cell mastitis in mice. *Cytokine*, 110:150-158.
2. David S Barreto, Emily L Sedgwick, Chandandeep S Nagi, Ana P Benveniste (2018) Granulomatous mastitis: etiology, imaging, pathology, treatment, and clinical findings. *Breast Cancer Res Treat*, 171: 527-534.
3. E Laas, C Touboul, O Kerdraon, S Catteau Jonard (2015) [Inflammatory and infectious breast mastitis outside of pregnancy and lactation: Guidelines]. *J Gynecol Obstet Biol Reprod (Paris)*, 44:996-1016.
4. Angelika Wolfrum, Sherko Kümmel, Ingo Theuerkauf, Enrico Pelz, Mattea Reinisch, et al. (2018) Granulomatous Mastitis: A Therapeutic and Diagnostic Challenge. *Breast Care (Basel)*, 13: 413-418.
5. Hu J, X Huang (2020) Combining ultrasonography and mammography to improve diagnostic accuracy of plasma cell mastitis. *J Xray Sci Technol*, 28: 555-561.
6. Yang Liu, Yushi Sun, Yuhui Zhou, Xiaojiang Tang, Ke Wang, et al. (2020) Sinomenine hydrochloride inhibits the progression of plasma cell mastitis by regulating IL-6/JAK2/STAT3 pathway. *Int Immunopharmacol*, 81:106025.
7. Muhammad Umair Bashir, Alexius Ramcharan, Sarah Alothman, Sabine Beaugris, Sarosh Ahmad Khan, et al. (2017) The enigma of granulomatous mastitis: A series. *Breast Dis*, 37: 17-20.
8. Samuel Schadt, Mark E Schadt, Thomas R Wojda, Franz S Yanagawa, Stanislaw P Stawicki, et al. (2017) Idiopathic granulomatous mastitis: A diagnostic and therapeutic challenge. *Am J Surg*, 3:336-339.

9. Betal D, F A Macneill (2011) Chronic breast abscess due to Mycobacterium fortuitum: a case report. J Med Case Rep, 5: 188.
10. Hai jing Yu, Qi Wang, Jian min Yang, Zhen qiang Lian, An qin Zhang, et al., Anti-mycobacteria drugs therapy for periductal mastitis with fistula. Chinese Journal of Surgery, (11): 971-974.
11. Tanu S Pandey, Jennifer C Mackinnon, Leah Bressler, Amy Millar, Elizabeth E Marcus, et al. (2014) Idiopathic granulomatous mastitis--a prospective study of 49 women and treatment outcomes with steroid therapy. Breast J, 20:258-66.
12. Katrin Roth, Laura Oehme, Sandra Zehentmeier, Yang Zhang, Raluca Niesner, et al., Plasma cell differentiation and survival. Curr Opin Immunol, 20: 162-169.
13. Jindan Zhang, Jianzhong Xu, Jiao Zhang, Yun Ren (2020) Chinese herbal compound combined with western medicine therapy in the treatment of plasma cell mastitis: A protocol for systematic review and meta-analysis. Medicine (Baltimore), 99:22858.
14. Xi Xiong, Y nan He, Bi Feng, Yuan Pan, Hai zhu Zhang, et al. (2018) Screening for the anti-inflammation quality markers of Xiaojin Pills based on HPLC-MS/MS method, COX-2 inhibition test and protein interaction network. Sci Rep, 8: 7454.
15. Andrea Palmieri, Valerio D orazi, Giovanni Martino, Federico Frusone , Daniele Crocetti, et al. (2016) Plasma Cell Mastitis in Men: A Single-center Experience and Review of the Literature. In Vivo, 30 727-732.
16. Jia Ming, Gang Meng, Qiaoying Yuan, Ling Zhong, Peng Tang, et al. (2013) Clinical characteristics and surgical modality of plasma cell mastitis: analysis of 91 cases. Am Surg, 79: 54-60.
17. Alper Akcan, A Bahadir Oz, Serap Dogan, Hülya Akgün, Muhammet Akyüz, et al. (2014) Idiopathic Granulomatous Mastitis: Comparison of Wide Local Excision with or without Corticosteroid Therapy. Breast Care (Basel), 9: 111-115.
18. Xiaoliang Li, Ping Xin, Changfu Wang, Zhibin Wang, Qihong Wang, et al. (2017) Mechanisms of Traditional Chinese Medicine in the Treatment of Mammary Gland Hyperplasia. Am J Chin Med, 45: 443-458.
19. Cai B (2015) Simultaneous Determination of Seven Components in Xiaojin Pills by UPLC-MS. Chinese Pharmaceutical Journal, 50:718-721.
20. Qi X, Wang X, Cheng T, Wu Q, Mi N, et al. (2019) Comprehensive characterization of multiple components and metabolites of Xiaojin Capsule based on ultrahigh performance liquid chromatography coupled with quadrupole time-of-flight mass spectrometry. J Sep Sci, 42: 2748-2761.
21. Xiao ling Wang, Brian D Mc Garvey, Xiao yin Tang, Yan Chang, Juan Chen, et al. (2017) GC-MS Study on Characteristics of Xiaojin Pills Containing Natural Musk and Artificial Musk. Chinese Journal of Experimental Traditional Medical Formulae, 23: 43-47.
22. Zhang S, Liu S (2016) Gu's Surgery Department's Three Generations in Treatment of Plasma Cell Mastitis. Journal of Zhejiang Chinese Medical University, 40: 747-749.

Copyright: ©2021 Xin Chen, et al. This is an open-access article distributed under the terms of the Creative Commons Attribution License, which permits unrestricted use, distribution, and reproduction in any medium, provided the original author and source are credited.