

## Unique Foreign Bodies in the Aerodigestive Tract

Adekanye AG<sup>1</sup>, Umana AN<sup>1</sup>, Offiong ME<sup>1</sup>, Mgbe RB<sup>1</sup>, Kuni JI<sup>1</sup>, Oku OO<sup>2</sup> and Akintomide AO<sup>3</sup>

<sup>1</sup>Department of Otorhinolaryngology Head and Neck Surgery, University of Calabar Teaching Hospital, Calabar, Nigeria.

<sup>2</sup>Department of Anaesthesiology and intensive care, University of Calabar Teaching Hospital, Calabar, Nigeria.

<sup>3</sup>Department of Radiology University of Calabar Teaching Hospital, Calabar, Nigeria.

### \*Corresponding author

Adekanye Abiola Grace, Department of Otorhinolaryngology Head and Neck Surgery, University of Calabar Teaching Hospital Calabar, Nigeria, Tel+2348050543605; E-Mail: abiolaadekanye@yahoo.com.

Submitted: 10 May 2017; Accepted: 27 May 2017; Published: 31 May 2017

### Abstract

*Aerodigestive tract is the combined organs and tissues of respiratory and upper part of the digestive tract. It includes the lips, mouth, tongue, nose, throat, larynx, pyriform sinus, pharynx and oesophagus. Foreign bodies in these anatomic sites are potential cause of morbidity and mortality. Most frequently occurs in children or adults with mental illness, less common in older children and adult. Clinico-radiological assessment of the patient is vital in making the diagnosis. We reported 3 patients with unique foreign bodies in aero-digestive tract. The first was a 3years 10month old child with non-radiopaque material in the oesophagus. The second was a 45year old farmer with spring of flash- light held in his mouth as source of light while riding a motorcycle in the night. The last case was of a 5year old girl whose tongue was impacted in her school water bottle. These cases highlight diagnostic difficulties and safety concern and awareness in poor resource setting.*

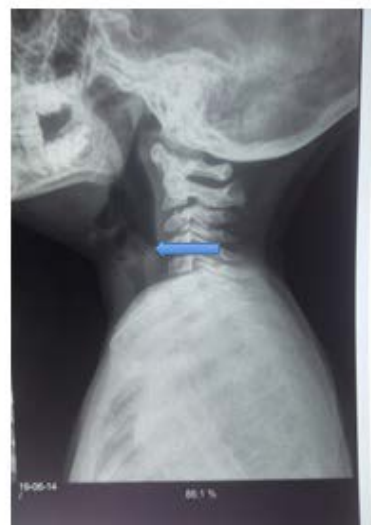**Keywords:** Unique. Foreign bodies. Aero-digestive tract. Spring. Tongue. Plastic water bottle

### Introduction

Aero digestive tract foreign bodies (FB) are known otolaryngological emergencies. They occur commonly in children or adults with mental illness [1]. Clinical presentations depend on the site of FB impaction [2]. Diagnosis is based on clinico-radiological findings [3]. We presented 3 unique foreign bodies in the aerodigestive tracts that were successfully managed. The first case was a child who presented with upper airway obstruction with non-radiopaque FB in the oesophagus of nine months duration. The second case was a man with plastic cover and metallic spring of a flashlight in the hypo pharynx. The third case was a child whose tongue got impacted in her school water bottle.

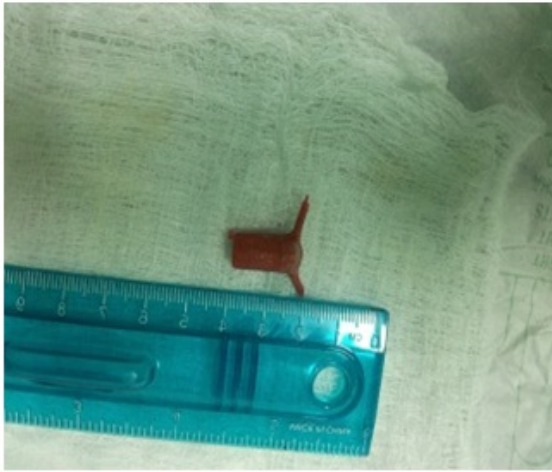
### Case 1

3year 10month old girl referred from children emergency room (CHER) of our hospital with 3months history of initially intermittent noisy difficult breathing but later became persistent with associated cough. Six months before the onset of these symptoms she swallowed a piece of plastic with choking sensation and dysphagia. However, Plain soft tissue neck x-ray did not reveal any FB hence parents were reassured and discharged home. On examination we found a dyspnoeic child with moderate inspiratory stridor. Vital signs were within normal limit. A repeat Plain soft tissue neck x-ray showed suspicious shadow at level of 6<sup>th</sup> cervical Vertebrae with lost of cervical lordosis (Figure. 1).



**Figure 1**

Rigid oesophagoscopy was done under General Anesthesia via endotracheal intubation and a Plastic FB with spikes was seen at the level of the cricopharyngeus. It was extracted successfully (Figure. 2).



**Figure 2**

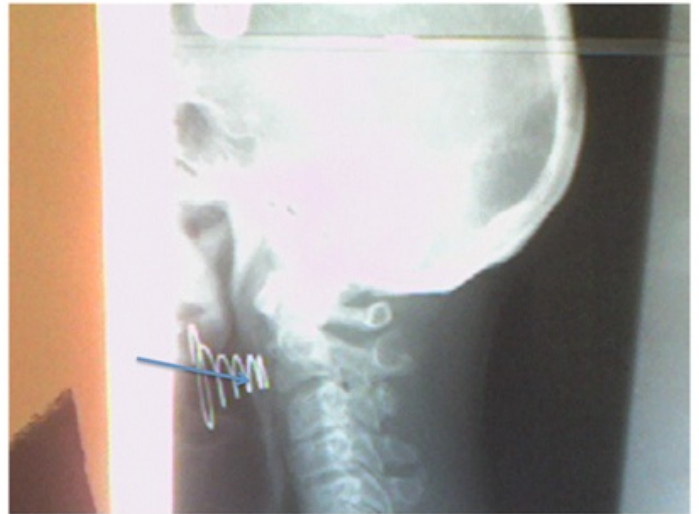
There after, nasogastric tube was passed. Patient did well and discharged home for follow-up.

### Case 2

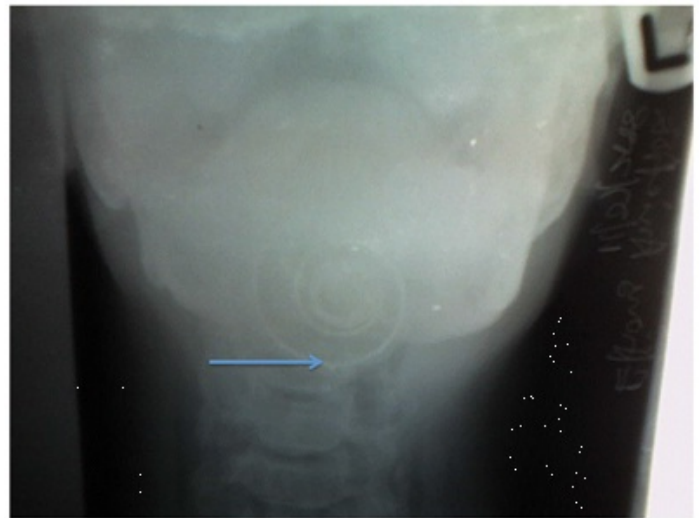A 45-year-old farmer referred from a rural health center to the accident and emergency department of our hospital with a 3-day history of throat pain, dysphagia to liquid and solids and drooling of saliva following road traffic accident. He was riding a motorcycle without a headlamp in the night. He had a flash light held in his mouth to light his path and had head on collision with another motorcyclist. He lost consciousness immediately after the accident for 24 hours and also bled profusely from the mouth. There was an associated deep laceration on the tongue, traumatic extraction of upper incisor teeth and choking sensation whenever he swallowed. He also sustained an abrasion on the right knee. There was no associated nasal obstruction, epistaxis, dyspnea, hoarseness, or stridor. No otological symptoms.

He had been resuscitated with intravenous fluids, the tongue laceration sutured, wound on the knee dressed and antibiotics commenced at rural health center. Our Examination revealed a young man conscious and alert, warm not in respiratory distress, moderately pale and drooling saliva. Oropharyngeal examination revealed bruises on the upper lip, loss of upper incisor teeth, bluish coloration of the tongue, stitches on distal third of tongue. The uvula had been amputated with slough over the soft palate, tonsillar regions and posterior pharyngeal wall. In the neck, there was crepitus over the anterior triangle with tenderness over the thyroid cartilage and submandibular region. The ear, nose and other systems were essentially normal.

Diagnosis of blunt throat injury to rule out foreign body was made. Plain radiograph of soft tissue neck revealed a well-defined coiled object of metallic density suggestive of a spring in the throat at the level of the 2<sup>nd</sup> cervical vertebra. The FB was horizontal in orientation with the wider base anteriorly. The adjacent airway was normal in caliber but cervical lordosis was lost, suggestive of muscle spasm (Figure.3&4).



**Figure 3**



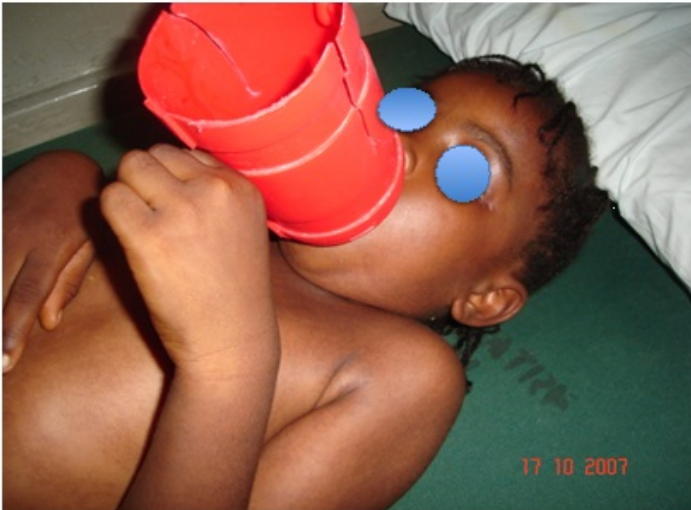**Figure 4**

The plastic cover of the touch was removed by the anesthesiologist during endotracheal intubation while the metallic spring of flash light cover was removed by the otorhinolaryngologist via rigid pharyngoscopy after endotracheal intubation. Postoperatively, he had intravenous ceftriaxone and diclofenac potassium.

Patient did well following surgery but with moderate regurgitation of feeds through the nose. He was counseled on the need for close follow up but he had since defaulted.

### Case 3

A 5-year-old female pupil presented in our CHER with her impacted tongue in a plastic school water bottle of 2 hours duration. She had associated painful swelling of the tongue. She was playing with her water bottle in the school and suddenly she could not remove her tongue from the mouth of the water bottle. Attempts at disimpaction at school failed. On examination, we met child in painful distress, crying, restless, with a water bottle stocked to the mouth (Figure.5).



**Figure 5**

On cutting out base of bottle, the anterior half the tongue was in the water bottle, pale-blue in colour and oedematous(Figure.6).



**Figure 6**

Consent was obtained from the parents for removal under general anaesthesia (GA). Under total intravenous anaesthesia, administered by the anaesthesiologist, the plastic water bottle was cautiously sawed over a metallic plate to protect the tongue and it was disimpacted. Recovery was uneventfully. Parenteral antibiotics (Ceftriaxone), steroids (Hydrocortisone), and analgesics (diclofenac potassium) were administered. She was discharged home the second day post operation.

### Discussion

Aero-digestive FB impaction occurs mostly in children between 6months to 5years [4]. It is less frequently in older children and adults. It is usually accidental, but can be deliberate in patients with mental illness. Case 1 and 3 are children below 5years. The second case was an adult, though not mentally ill, but highlights gross ignorance to safety rules, carelessness and probably poverty.

Common aerodigestive FB in children includes coins, small toys, pens, batteries, safety pins, needles and hairpins. In older children

and adults; food related items like fish bone, chicken bones and dentures [5]. Cases 2 and 3 are unique FB, which to the best of our literature search have not been reported before.

Diagnosis of aero-digestive FB is made from clinico-radiological findings and confirmed at endoscopic [3,6,7]. Case1 had misleading presentations clinically, and the Plain X-ray soft tissue neck was also not helpful. Pavan et al [3] and Umana et al [8] reported similar misleading presentations in children, but, none of the patients was asymptomatic for such a long time. This highlight the value of CT scans when there is challenge in diagnosis of aero-digestive tract foreign bodies.

Treatment of aero-digestive FB varies from watchful waiting to instrumental removal, endoscopic extraction, balloon catheter extraction, and external approaches [3,9].

Cases 1 and 2 had successful endoscopic removal. Case 3 is very unique as to what or who was the foreign body, the child or the bottle? Consequently treatment was adapted to the unique nature of the case.

### Conclusion

Impacted aerodigestive FB are surgical emergencies. Prognosis depends on early diagnosis and appropriate treatment. Most of these Unique FB are preventable by public enlightenment on personal safety and improved diagnostic radiological facilities in poor economies and safety measures in toys or accessories for school children.

### Consent

Informed consent was obtained from the patients and their relatives for the manuscript to be published.

### Conflict of Interests

The authors declare that there is no conflict of interests regarding the publication of this paper.

### Acknowledgement

The authors acknowledge staff nurses, medical record officer others who took part in management of these patients.

### References

1. Gitlin DF, Caplan JP, Rogers MP, Avni-Barron O, Braun I, et al. (2007) Foreign-body ingestion in patients with personality disorders. *Psychosomatics* 48: 162-166.
2. Sridevi MM (2013) Whole fish, an unusual foreign body in the tongue of a child. *Anesth Essays Res* 7: 287-288.
3. Pavan S, Arvind SB, VP Singh, Meeta A (2002) Unusual Foreign Bodies of the Aerodigestive Tract. *Indian Journal of Otolaryngology and Head and Neck Surgery* 54: 2123-126.
4. Adekanye AG, Oku OO, Umana AN, Akintomide AO, et al. (2015) Unique foreign body of the pharynx- Touch light spring and its plastic cover. *Journal of Nursing and Care* 4: 4
5. Haidary A, Leider JS, Silbergleit R (2007) Unsuspected swallowing of a partial denture. *AJNR Am J Neuroradiol* 28: 1734-1735.
6. Braverman I, Gomori JM, Polv O, Saah D (1993) The role of CT imaging in the evaluation of cervical oesophageal foreign bodies. *J Otolaryngol*, 22: 311-314.

- 
7. Marco De Lucas E, Sadaba P, Lastra Garcia-Baron P, Ruiz-Delgado ML, Gonzalez Sanchez F, et al. (2004) Value of helical computed tomography in the management of upper oesopharyngeal foreign bodies. *Acta Radio* 45: 369-374.
  8. Umana AN, Offiong ME, Ewa AU (2011) Foreign body (disk battery) in oesophagus mimicking respiratory problem in 13 month old baby delayed diagnosis. *Journal of Medicine and Medicine Science* 2: 714-717.
  9. Okoye IJ, Imo AO, Okwulehie V. (2005) Radiologic management of impacted coin in the oesophagus--a case report. *Niger J Clin Pract* 8: 56-59.

**Copyright:** ©2017 Adekanye AG et al. This is an open-access article distributed under the terms of the Creative Commons Attribution License, which permits unrestricted use, distribution, and reproduction in any medium, provided the original author and source are credited.