

Unilateral Mooren Ulcer

Elakhdari Meriem*, Akannour Y, Bardi Ch, Mrad Khalil, Hassina Salma, Serghini Louai, El Hassan Abdellah and Berraho Amina

Department of Ophthalmology, Hospital of Specialties, Rabat, Morocco

*Corresponding Author

Elakhdari Meriem, Department of Ophthalmology, Hospital of Specialties, Rabat, Morocco, Tel: 0675028586

Submitted: 10 Apr 2023; Accepted: 19 Apr 2023; Published: 28 Apr 2023

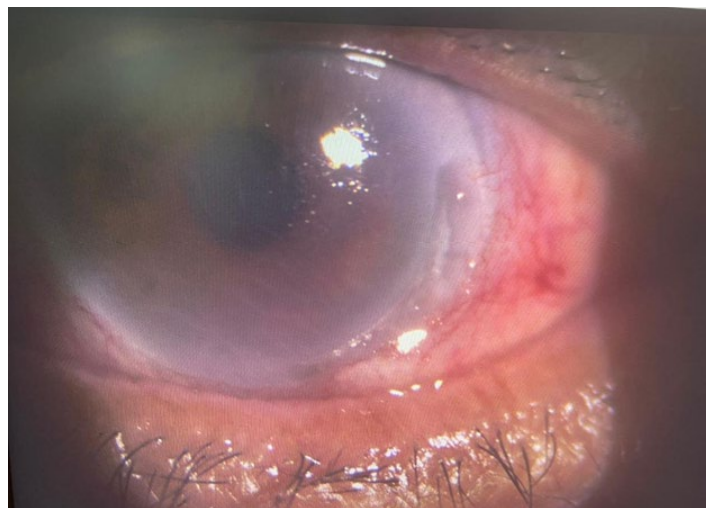
Citation: Elakhdari Meriem, Akannour Y, Bardi Ch, Mrad Khalil, Hassina Salma, et al. (2023) Unilateral Mooren Ulcer. *J Ophthalmol Clin Res* 7(1): 170.

A 57-year-old patient with no pathological history, who consulted urgently for a painful red eye with reduced visual acuity in her right eye, with foreign body sensation, lacrimation, and photophobia, those signs has been started three days before his admission to the emergency room.

Ophthalmological examination revealed a limited visual acuity to 2/10, slit lamp examination showed deepening nasal para-limbal ulcer with a horizontal axis, presenting a promontory edge on the central corneal side, with conjunctival hyperemia, and corneal edema.

The patient has benefited from a paraclinical evaluation which was normal.

The patient received a treatment based on topical prednisolone acetate 1% eye drop four times daily, prophylactic topical antibiotic eye drops, moxifloxacin, with preservative artificial tears.



Slit-lamp photograph of the right eye at showing a marginal corneal ulcer, with conjunctival hyperemia, and corneal edema.

Copyright: ©2023 Elakhdari Meriem, et al. This is an open-access article distributed under the terms of the Creative Commons Attribution License, which permits unrestricted use, distribution, and reproduction in any medium, provided the original author and source are credited.