

Traumatic Subtalar Joint Dislocation: Management and Prognosis

Mohammed Sadougui*, Amine Hamzaoui, Jamal Kerbal, Amine Mechmachi and Abdelkarim Daoudi

Department of Orthopedics and Trauma ,University Hospital Mohammed VI, Oujda, Morocco.

*Corresponding Author

Mohammed Sadougui, Departement of orthopedics and trauma ,university hospital Mohammed VI, Oujda, Morocco.

Submitted: 2023, July 04; Accepted: 2023, July 26; Published: 2023, Oct 05

Citation: Sadougui, M., Hamzaoui, A., Kerbal, J., Mechmachi, A., Daoudi, A. (2023). Traumatic Subtalar Joint Dislocation: Management and Prognosis. *World J Clin Med Img*, 2(2), 68-71.

Abstract

Subtalar dislocation is defined as a separation of the talocalcaneal and talonavicular joints, usually caused by high-energy mechanisms, these are extremely rare injuries, the series of the literature reporting only a few dozen cases spread over several decades, The most common type is the medial dislocation resulting from an injury in inversion, They can be isolated (pure) or associated with a neighboring fracture (tibial pilon, talus, calcaneus) see open or closed, Closed reduction and immobilization remain the mainstay of treatment, X-ray and CT scan should be performed to assess the alignment and fractures, We report the functional results of two cases of a pure subtalar dislocation in two young men of 24 and 26 years on a 2-year delay

Keywords: Talus, Subtalar Joint, Dislocation, Arthritis, Bone Necrosis.

1. Introduction

Subtalar dislocation, often also called perital dislocation,(1) is a very rare injury in which the talocalcaneal and talonavicular joints are dislocated simultaneously (2,3) due to weakness of the ligaments that accord them, It was first described in 1811 by Judcy(4) and Dufauret(5) separately, Medial subtalar dislocations predominate in the literature, representing about 80% of reported dislocations. This injury is also called acquired clubfoot because of the appearance of the foot. We report two cases of this uncommon injury as well as its functional results over 2 years.

2. Case N°1

A 24-year-old man fell from a height with his foot stuck on the ground, causing him pain and deformity of his ankle with total functional importance on clinical examination. The ankle was edematous with shortening of the dorsum of the foot, which was in an equinus position (acquired clubfoot), The head of the talus was palpable under the external malleolus, any active or passive mobilization of her foot was impossible and very painful and presence of signs of skin suffering such as external ecchymosis without opening, with a vascular-nervous examination without particularity (fig1,2)



Figure 1 -2 : Clinical picture on admission, the appearance of an acquired clubfoot with a subtalar dislocation

The radiographic examination revealed an external displacement of the mortise concerning the calcaneus and the navicular, which were internally displaced, resulting in a medial subtalar dislocation without an associated fracture

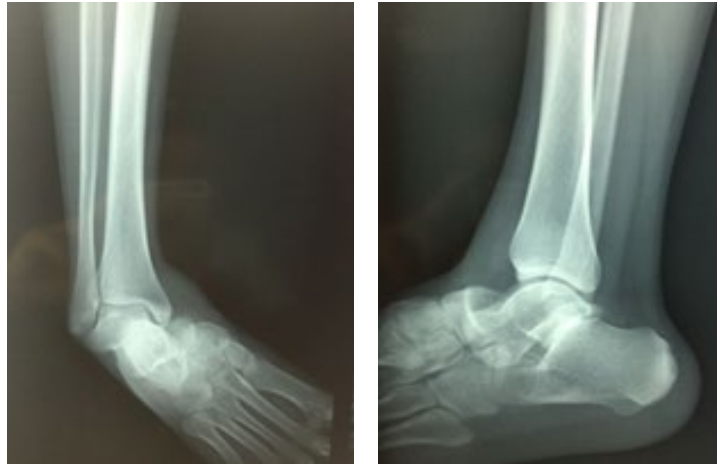


Figure 3 : X-Ray, Front, and Side, Showing The Subtalar Medial Dislocation

The immediate reduction was performed under sedation. The knee flexed to relax the Achilles tendon, reduction was successfully achieved by an external maneuver. Manual traction on the foot with counter traction on the leg combined with direct digital pressure on

the head of the talus allowed for a smooth reduction Post-reduction radiographs showed normal and stable alignment of the subtalar and talonavicular joints, without osteochondral damage (Fig. 4)

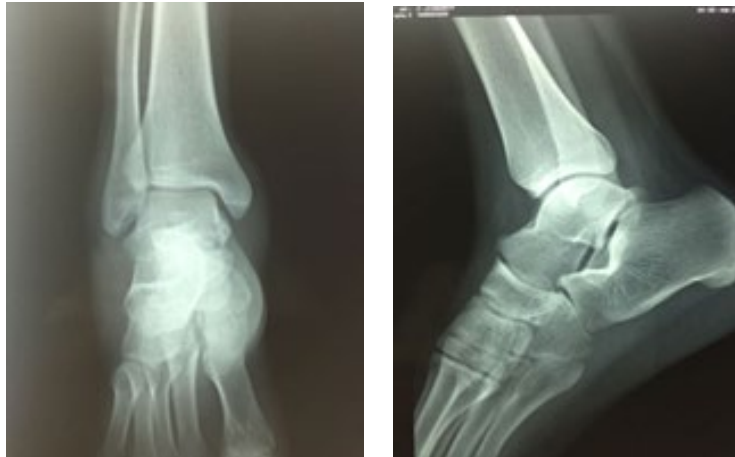

Figure 4: Post-reduction radiograph: alignment of anatomical landmarks without associated lesions

3. Case N°2

A patient aged 26 years who was a victim of a traffic accident whose mechanism is a pedestrian hit by a car, on admission the patient presents with excruciating pain in his right ankle which was deformed with an aspect of acquired clubfoot, he presents a

graze under external malleolar (Fig. 5), the vascular and nervous examination is without particularity, the radiological assessment to objectify a medial subtalar dislocation without other bone injuries, (Fig. 6)

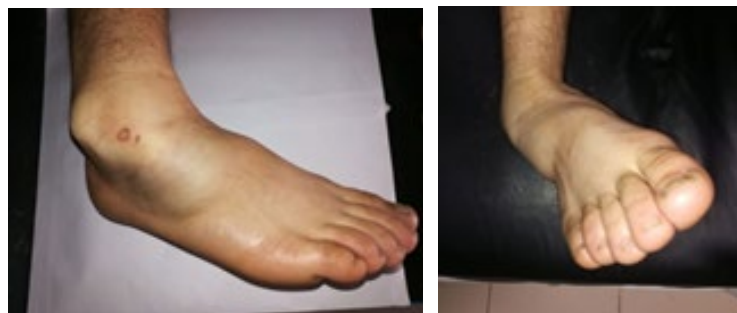

Figure 5: Clinical Aspect of A Medial Subtalar Dislocation

The patient underwent a reduction of his dislocation under sedation, the post-reduction radiograph confirmed the stabilization of the reduction concerning the anatomical-radiological criteria of

the ankle and without associated lesions, followed by mobilization with a circular cast to be kept on for 8 weeks, followed by active and passive rehabilitation, with satisfactory results for the patient

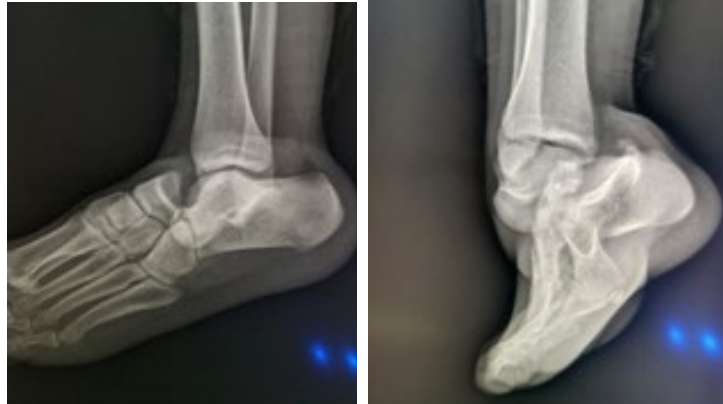

Figure 6: X-ray of the ankle showing a medial subtalar dislocation

4. Discussion

Subtalar dislocations are very rare lesions, the series in the literature reports only a few dozen cases spread over several decades, representing about 1% of total joint dislocations (6), the first case reported in the literature dates back to 1803, It most often affects young people either during a traffic accident or a fall from a high height. It is a particular entity and is defined by the mass displacement, in the frontal plane of the calcaneo-pedious block, around the talus, whose body remains in place in the tibiofibular mortise. The line of displacement thus involves the talonavicular and subtalar bones and respects the cuboid-calcaneal bone. This is a dislocation of the torsional couple respecting the calcaneocuboid bone (7).

The mechanism of the medial subtalar dislocation is a force inversion of the foot blocked on the ground causing ligamentous tears in a specific chronological way. First, the dorsal talonavicular ligament, then the two interosseous ligaments, and finally the calcaneofibular ligament. Lateral dislocation begins with the eversion of the foot. First, the deltoid ligament is disrupted, then the interosseous ligament and the talocalcaneal joint are disrupted, followed by the dorsal talonavicular ligament. (8) Lateral dislocation often results in injury to the posterior tibial tendon. The trauma is therefore more severe. Medial dislocation is more common than lateral dislocation (9,10), between 10 and 40% of subtalar dislocations are open.[11]. Open injuries tend to occur more frequently in lateral subtalar dislocation and Long-term follow-up has shown very poor outcomes with open subtalar dislocations (11).

To avoid soft tissue and vessel complications, early diagnosis of a clear type of dislocation, and early reduction are key factors for the treatment of subtalar joint dislocation, once the diagnosis is confirmed reduction should be started urgently under sedation with scopic control to avoid damaging the blood supply around the talus and reduce compression and necrosis of the skin (12-13), After successful reduction, the associated fractures should be treated at

the same time. Although the closed reduction is easy to achieve, there is still a failure rate of about 20%, and manual reduction of the lateral dislocation is more difficult to achieve (14), Regardless of the method of reduction, the subtalar joint is usually stable after closed or open treatment and does not require internal fixation. It is recommended that the limb be immobilized in a cast boot for 3 to 6 weeks without support, The prognosis of these injuries is relatively good in most authors except in cases of skin opening or associated fracture, The risk of talar necrosis is estimated at 4% and that of subtalar osteoarthritis at 31% [15].

5. Conclusion

Pure medial subtalar dislocation is a rare traumatological condition, its diagnosis is easy, and treatment often consists of reduction by external maneuver under general anesthesia, except in cases of irreducibility due to ligament incarceration, when surgical reduction is required. These lesions have a good prognosis except in cases associated with a skin opening.

Conflicts of Interest: The authors do not report any conflict of interest in this study.

Contributions of the Authors: All authors contributed to this study since conception, reading, and approved the latest version.

Source of Funding For The Study: None

References

1. DeLee, J. C., & Curtis, R. (1982). Subtalar dislocation of the foot. *JBJS*, 64(3), 433-437.
2. Smith, H. (1937). Subastragalar dislocation: a report of seven cases. *JBJS*, 19(2), 373-380.
3. TJ, Z. (1989). Subtalar dislocations. *Clin. Orthop. Relat. Res.*, 238, 190-194.
4. Judcy, P. (1811). Observation d'une luxation metatarsienne. *Bull Fac Med Paris*, 11, 81-86.
5. Defaurrest, P. luxation du pied en dehors, *J Med Chir Pharm*

1811 ; 22 ; 348-355.

6. Benabbouha, A., & Ibou, N. (2016). Rare case of pure medial subtalar dislocation in a basketball player. *Pan African Medical Journal*, 23(1).
7. NORMAN BIGA, Chirurgie des traumatismes du pied et de la cheville, *Fracture et luxation*, P : 131
8. Veltman, E. S., Steller, E. J., Wittich, P., & Keizer, J. (2016). Lateral subtalar dislocation: Case report and review of the literature. *World journal of orthopedics*, 7(9), 623.
9. Giannoulis, D., Papadopoulos, D. V., Lykissas, M. G., Koulouvaris, P., Gkiatas, I., & Mavrodontidis, A. (2015). Subtalar dislocation without associated fractures: Case report and review of literature. *World Journal of Orthopedics*, 6(3), 374.
10. Hoexum, F., & Heetveld, M. J. (2014). Subtalar dislocation: two cases requiring surgery and a literature review of the last 25 years. *Archives of orthopaedic and trauma surgery*, 134, 1237-1249.
11. Goldner, J. L., Poletti, S. C., Gates 3rd, H. S., & Richardson, W. J. (1995). Severe open subtalar dislocations. Long-term results. *JBJS*, 77(7), 1075-1079.
12. Nanjayan, S. K., Broomfield, J., Johnson, B., Patel, A., Srivastava, S., & Sinha, A. (2014). Total dislocation of the talus: A case report. *Foot & ankle specialist*, 7(1), 71-73.
13. Yapici, F., Coskun, M., Arslan, M. C., Ulu, E., & Akman, Y. E. (2019). Open reduction of a total talar dislocation: A case report and review of the literature. *World Journal of Clinical Cases*, 7(14), 1850.
14. Gaba, S., Kumar, A., Trikha, V., Das, S., & Agrawal, P. (2017). Posterior dislocation of subtalar joint without associated fracture: a case report and review of literature. *Journal of clinical and diagnostic research: JCDR*, 11(9), RD01.
15. Schuind, F., Andrianne, Y., Burny, F. L., Donkerwolcke, M., Saric, O., Body, J. J., ... & Demarneffe, R. (1983). Fractures et luxations de l'astragale. Revue de 359 cas. *Acta orthopaedica Belgica (Ed. bilingue)*, 49(6), 652-689.

Copyright: © 2023 Mohammed Sadougui, et al. This is an open-access article distributed under the terms of the Creative Commons Attribution License, which permits unrestricted use, distribution, and reproduction in any medium, provided the original author and source are credited.