

Toxic Epidermal Necrolysis and Graft versus Host Disease after Hematopoietic and Liver Transplantation: A Review

Juaquito Jorge¹, Areta Kowal-Vern^{2*}, Henry Chi Hang Fung³, Stathis J Poulakidas⁴

¹Tiesenga Surgical Associates, Elmwood Park, Illinois

²Arizona Burn Center, Department of Research, Maricopa Integrated Health Systems, Phoenix, Arizona

³Department of Hematology/Oncology, Fox Chase Cancer Center/Temple Health, Philadelphia, PA

⁴Sumner L. Koch Burn Center, Department of Trauma, John H. Stroger, Jr. Hospital of Cook County, Chicago, IL

*Corresponding author

Areta Kowal-Vern, Arizona Burn Center, Department of Surgery, Maricopa Integrated Health System, 2601 E Roosevelt Road, Phoenix, AZ 85008, Arizona, Tel: 865-548-6880; E-mail: akvern@hotmail.com, Areta.Kowal-Vern@MIHS.org

Submitted: 30 Aug 2018; Accepted: 08 Sep 2018; Published: 27 Sep 2018

Abstract

Background: Although rarely reported, Graft versus Host Disease (GvHD) and Toxic Epidermal Necrolysis (TEN) may complicate recovery in patients who undergo hematopoietic cell, and organ transplantation. Skin manifestations can appear clinically similar or overlap. The objective of this study was to determine whether there are any parameters, which distinguished these two conditions during transplantation.

Methods: A literature search for TEN only and combined TEN/GvHD cases after hematopoietic or liver transplantation between 1970 and 2015 was performed.

Results: Of 34 cases, there were 14 cases of TEN and 20 of combined TEN/GvHD after hematopoietic or liver transplantation. Patients with TEN had a median age of 41 (range 22-56) years compared to patients with TEN/GvHD who had a median age of 29 (range 18-52) years. Percent total body surface area (TBSA) skin involvement was a median of 50 (range 23-87) %TBSA in the TEN group and 55 (range 30-80) %TBSA in the TEN/GvHD group. Mortality was 71.4% in the TEN group (10 of 14) and 95% in those with concurrent TEN/GvHD (19 of 20).

Conclusions: Development of both TEN and GvHD after hematopoietic or liver transplantation heralded a poor prognosis. TEN was frequently precipitated by co-trimoxazole and allopurinol, medications frequently used during transplantation. GvHD was more likely to start before TEN if both were diagnosed. If Grade IV GvHD occurred, it was difficult to determine if TEN had also complicated the picture. More patients with HSCT developed TEN/GvHD compared to patients with BMT and liver transplants. Future treatment directions may utilize major histocompatibility complex genetic drug susceptibilities testing to prevent the development of TEN during the transplantation in vulnerable patients. Although still in the early stages, several studies have shown that cyclosporine, which is used to treat patients with GvHD, may also be beneficial in decreasing mortality in patients with TEN.

Keywords: Toxic Epidermal Necrolysis (TEN), Stevens-Johnson Syndrome (SJS), Graft Versus Host Disease (GVHD), Liver Transplantation, Hematopoietic Stem Cell Transplantation (HSCT), Bone Marrow Transplantation (BMT)

Introduction

Since 1970, overlap between toxic epidermal necrolysis (TEN) and graft versus host disease GVHD after transplantation has been controversial. TEN, also known as Lyell's disease, was initially described by Scottish dermatologist Alan Lyell in 1956 [1]. He used the term 'toxic epidermal necrolysis' to characterize an uncommon but severe, life-threatening mucocutaneous disorder exhibiting extensive, rapidly evolving epidermal detachment, erythema and necrosis [1].

Graft-versus-Host Disease (GvHD) is a serious and relatively common complication following an allogeneic hematopoietic cell transplant usually due to HLA incompatibility between the donor and the recipient. Immune cells from the new graft recognize the recipient as "foreign;" the transplanted immune cells then attack the host's body cells [2]. It can also occur in patients who undergo liver transplantation. Table 1 compared the skin manifestations of TEN and GvHD [2,3].

Peripheral blood stem cell transplantation (PBSCT) was first clinically introduced in 1986 as a transplant modality [4,5]. It has since become a hematopoietic modality, "Hematopoietic Stem Cell Transplantation" (HSCT) rivaling allogeneic BMT in terms of utilization. While no significant difference in the development

of acute GvHD exists between HSCT and BMT, HSCT is associated with an increased frequency of chronic GvHD [6].

Table 1: Comparison of TEN and GvHD

Parameter	TEN	Acute GvHD	Chronic GvHD	Grade IV GvHD
Drug-Induced	+	--	--	--
Erythema	+	+	--	+
Maculopapular rash	+	+	--	+
Blisters	+	--	--	+
Nikolsky Sign	+	--	--	-/+
Mucositis	+	--	-/+	-/+
Satellitosis	--	+	+	+
Lichenoid Pruritis	--	--	+	--
Scleroderma	--	--	+	--
Occurs (days)	8-30	≤ 100	>100	anytime

TEN= toxic epidermal necrolysis; GvHD= graft versus host disease

A patient recently treated in the Burn Unit, who developed a pathophysiological presentation consistent with both GvHD and TEN after HSCT, prompted a review of the literature to elucidate similarities and differences of TEN and GvHD, and to determine the frequency of TEN and TEN/GvHD co-existence after hematopoietic and liver transplantation.

Table 2: Cases Reported in the Literature of Demographic Characteristics of TEN only and TEN/GvHD Developing after Hematopoietic Transplantation

Article	Year	Age	Sex	Initial Disease	Type of Transplant	% TBSA	Diagnosis	Day of GVHD from Transplant	Day of TENS from Transplant	Suspected Drug(s)	Treatment	Survival from Trans plant (days)	Cause of Death
Graw [7]	1970	22	M	ALL	BMT	--	TEN/GvHD	15	25	allopurinol; antibiotics	steroid; MTX	33	Pseudo Sepsis
Peck [8,9]	1972	51	F	AML	BMT	--	TEN	n/a	--	--	--	No	Pseudo Sepsis
	1972	49	F	Lympho sarcoma	BMT	--	TEN	n/a	--	--	--	No	Pseudo Sepsis
	1972	15	M	AA	BMT	--	TEN	n/a	--	--	--	No	Pseudo Sepsis
Friedman [10]	1984	22	M	AML	BMT	90%	TEN/GvHD	25	40	co-trimoxazole	steroid	Alive	n/a
Villada [12]	1990	16	M	AML	BMT	60%	TEN/GvHD	--	28	Excluded	steroid	57	Acute GVHD, bacterial pneumonia
	1990	23	M	ALL	BMT	45%	TEN/GvHD	--	28	Excluded	steroid	39	Sepsis
	1990	45	M	AML	BMT	60%	TEN	n/a	7	co-trimoxazole	steroid	20	Sepsis, CNS bleeding
	1990	37	M	CGL	BMT	20%	TEN/GvHD	--	18	Excluded	steroid	27	Acute GVHD, pneumonia
	1990	28	F	AML	BMT	30%	TEN/GvHD	--	33	co-trimoxazole	steroid	245	CNS infection
	1990	28	M	CGL	BMT	30%	TEN	n/a	45	co-trimoxazole	steroid	63	HSV infection (CNS and lung)
	1990	41	F	CGL	BMT	80%	TEN/GvHD	--	26	Excluded	steroid	41	Pulmonary Aspergillosis
	1990	19	M	CML	BMT	80%	TEN	31	147	co-trimoxazole; sulfadiazine	steroid	156	Sepsis, CNS toxoplasmosis
	1990	37	F	ALL	BMT	40%	TEN/GvHD	--	15	Excluded	steroid	135	S
McDonald [13]	1992	23	M	ALL	BMT	60%	TEN	n/a	16	aztreonam	supportive	21	Sepsis, Pulmonary Failure
	1992	32	M	NHL	BMT	20%	TEN	n/a	16	aztreonam	supportive	44	Invasive Aspergillosis

Takeda [16]	1997	21	M	AML	BMT	--	TEN/GvHD	6	8	co-trimoxazole; sulfonamides	cytosine arabioside; MTX	19	Acute GVHD: Renal
Correia [17]	2001	38	M	CML	BMT	15	TEN/GvHD	26	39	busulfan	ATG; steroid MTX; cyclosporine	102	Chronic GVHD Respiratory Failure Pneumonia
	2001	47	F	CML	BMT	70	TEN/GvHD	39	69	busulfan	steroid; MTX; cyclosporine	210	Liver Failure
Zakrzewski [18]	2002	35	F	SAA	PBSCT	50%	TEN	n/a	3	co-trimoxazole; allopurinol	steroid	13	Septic Shock, MOF
Schaich [19]	2003	52	M-	CML	PBSCT	--	TEN; delayed GVHD	80	14	imatinib	steroid	100	Acute GVHD GI
Arvidson [21]	2007	9.5	M	ALL	PBSCT	90%	TEN/GvHD	9	26	co-trimoxazole allopurinol; cytosine arabioside	initially steroid; plasmapheresis, IVIG, Mtx	53 (alive)	n/a
Hilgendorf [22]	2007	?	F	MM	PBSCT	--	TEN Delayed GVHD	>500	22	co-trimoxazole; antibiotics	IVIG, steroid	593	MOF; Sepsis
Wasch [24]	2012	61	M	MM	HSCT	30%	TEN/GvHD	--	365	lenalidomide	Steroid; cyclosporine	491	MM
Macedo [27]	2014	23	F	NHL	HSCT	80%	TEN/GvHD	16	32	vancomycin; cefepine	steroid; tarolimus; mofetil; IVIG	44	Coagulopathy Pneumonia
Gomulka [28]	2014	67	2	CLL	HSCT	45%	TEN/GvHD	--	185	voricanazole	IVIG	alive	n/a
Study Case	2010	44	M	CML	BMT	80%	TEN/GvHD	31	140	sirolimus	sirolimus	169	Sepsis, Coagulopathy

Methods

Compilation of Cases

A literature search on GvHD and TEN or TEN only after hematopoietic [bone marrow transplant (BMT) and hematopoietic stem cell transplant (HSCT)] or liver transplantation was conducted in PubMed, Internet, Google Scholar, and citations of pertinent articles were cross-checked for additional references. There were 21 articles in the literature describing 33 cases; each article described from 1-9 cases between 1970 and 2014, Tables 2 and 3. Our case raised the total to 34 cases [7-28]. A case of Stevens Johnson Syndrome in a 21 year old patient with ALL who underwent an HSCT transplant was also reported as being precipitated by *Mycoplasma pneumoniae* [29]. There was engraftment by day 16, and the signs and symptoms of SJS appeared by day 29; the patient survived [29].

Statistical Analysis

Statistical analysis consisted of descriptive statistics and chi-squared, utilizing Statistica® (StatSoft, Tulsa Oklahoma). Demographic characteristics of age, % TBSA, sex, length of stay, time to engraftment, start day for TEN, start day for GvHD, mortality, medications, and diagnosis were compared in TEN only versus TEN/GvHD groups; BMT, HSCT, and Liver transplant groups and BMT versus HSCT groups. Summary descriptive statistics such as median, means and standard deviation were calculated; chi squared test, and one way ANOVA were also performed. Statistical analysis and significance (set at $p < 0.05$) were limited due to the high coefficient of variation (inconsistent) and the incomplete information available in the case reports.

Results

Medications

All transplant patients were exposed to a myriad of medications in terms of chemotherapy, antimicrobials, immunosuppressive agents

and many other supportive medications. Once GvHD developed, treatment medications commonly utilized included corticosteroids, cyclosporine, tacrolimus, infliximab, mycophenolate mofetil, sirolimus, anti-thymocyte globulin muromonab-CD3, allopurinol, sulfa drugs such as co-trimoxazole, carbamazepine, and others. It was frequently difficult to pinpoint the exact culprit since many of the TEN precipitating agents were often administered simultaneously to prevent or address transplant-related complications. As a major prophylactic medication for preventing *Pneumocystis carinii* pneumonia, co-trimoxazole was the most frequently cited causal medication (15 of 34 cases, 44%), either alone or in conjunction with other antibiotics or allopurinol, Tables 2 and 3.

Hematopoietic versus Liver Transplant Patients

Of the 34 patients, 27 (79%) had a hematopoietic, and 7 (21%) a liver transplant, Tables 2 and 3. Diagnoses for patients with hematopoietic transplantations were: 11 acute leukemias, 8 chronic granulocytic leukemias, 3 lymphoid neoplasms, 1 chronic lymphocytic leukemia, 2 multiple myelomas, and 2 aplastic anemia. Of the seven patients who received a liver transplant, 1 had a primary hepatic malignancy, 2 had Hepatitis C, 1 had Hepatitis C with a primary hepatic malignancy, 1 had Hepatitis B with a primary hepatic malignancy, 1 experienced hepatic failure secondary to *Amanita phalloides* mushroom ingestion, and 1 had Maple Syrup Urine Disease (MSUD) and nephrotic syndrome. Table 4 lists the demographic characteristics of the patients in the literature, Figures 1-3. Eighteen of 27 (67%) patients with hematopoietic transplants and 2 of 7 (29%) patients with liver transplants developed TEN/GvHD. Nine of 27 (33%) patients with hematopoietic transplants developed TEN only compared to 5 of 7 (71%) in the liver transplant group. Total survival in hematopoietic and liver transplant patients was 5 of 34 (14.7%). The HSCT group had a mortality of 88.9%, and liver transplant group had a mortality of 71.4%, Figure 4.

Table 3: Cases Reported in the Literature of Demographic Characteristics of TEN only and TEN/GvHD Developing after Liver Transplantation

Article	Year	Age	Sex	Initial Disease	Type of Transplant	% TBSA	Diagnosis	Day of GVHD from Transplant	Day of TENS rom Transplant	Suspected Drug(s)	Treatment	Survival from Transplant (days)	Cause of Death
Merle [11]	1990	58	M	Liver CA	Liver	80%	TEN	n/a	31	aztreonam; cyclosporine	steroid; aztreonam; cyclosporine	No	Pneum/Sepsis Candida encephalitis
Ostlere [14]	1992	44	F	Hepatitis C	Liver	--	TEN	n/a	27	fluconazole	OKT3; gangcyclovir	90 (alive)	n/a
Neumann [15]	1995	30	M	Amanita phalloides	Liver	--	TEN/GvHD	42	32	--	ATG;OKT3	52	Cranial Hemorrhage
Schulz [20]	2006	55	M	Hepatitis C; Hepatic Cancer	Liver	--	TEN	n/a	22	co-trimoxazole; beta-lactam antibiotics	steroid; IVIG	32	Septic Shock, MOF
Joo [23]	2008	62	M	Hepatitis B&C	Liver	--	TEN	n/a	n/a	co-trimoxazole;	steroid; tarolimus	104	Pneumonia; Carditis; CVA Herpes
Jeanwood [25]	2012	66	M	Hepatitis C	Liver	30%	TEN/GvHD	22	25	co-trimoxazole; antibiotics	steroid; tarolimus	34	MOF
Tomaino [26]	2012	7	F	MUSD; Nephrotic Syndrome	Liver	--	TEN	n/a	150	Mycoplasma pneumoniae; co-trimoxazole	steroid; azithromycin; IVIG	alive	n/a

Table 4: Demographic Characteristics of BMT, HSCT, and Liver Transplantation Recipients

Parameters mean±s.d (median)	BMT n=19	HSCT n=8	Liver n=7
Age (Years)	31.2±11.6 (28)	41.5±20.6 (43)	46.0±21.1 (55)
%TBSA	50.0±24.9 (52.5)	62.5±24.0 (65)	65.0±49.5 (65)
Time to Engraft (days)	16.5±3.5 (16.5)	14.0±8.5 (14)	--
Start GvHD (day)	23.7±11.7 (25.5)	126.0±210.6 (31)	32.0±14.2 (32)
Start TEN (day)	35.0±33.7 (27)	98.4±126.5 (29)	42.7±47.8 (27)
Survival from Transplant (days)	80.8±73.0 (44)	209.0±234.7 (100.0)	61.2±29.6 (53.5)
Mortality # (%)	18 (95%)	6 (75%)	5 (71%)

TEN= toxic epidermal necrolysis; GvHD= graft versus host disease; BMT= bone marrow transplant; HSCT= hematopoietic stem cell transplant

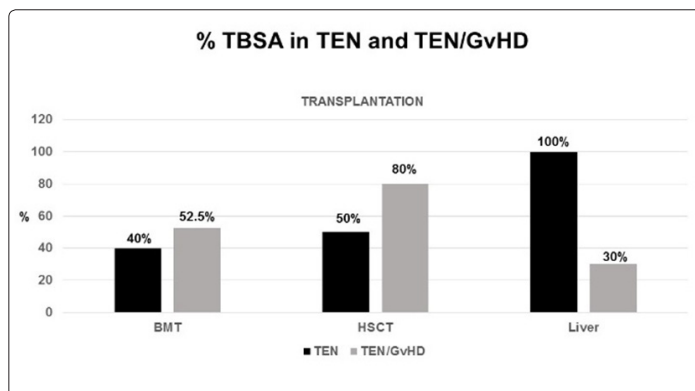


Figure 1: % TBSA in TEN and TEN/GvHD

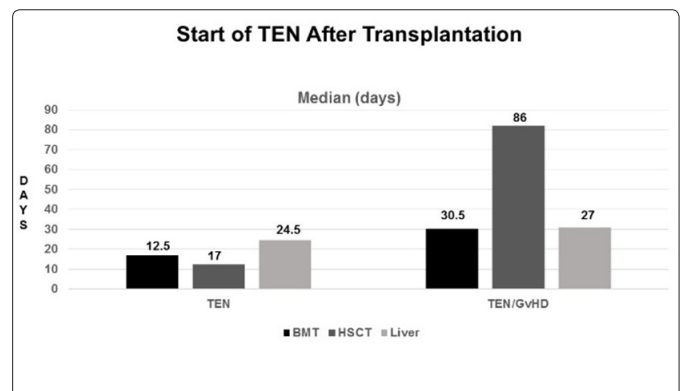


Figure 2: Start of TEN After Transplantation

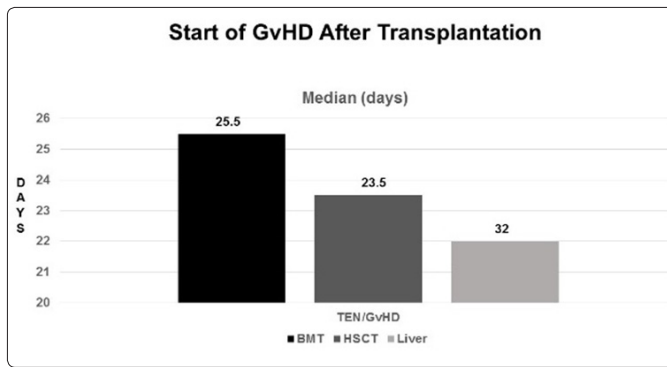


Figure 3: Start of GvHD After Transplantation

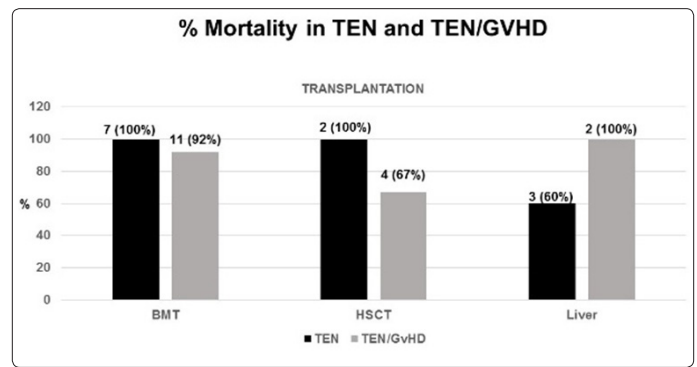


Figure 4: % Mortality in TEN and TEN/GvHD

There was no significant survival advantage in the TEN only compared to the TEN/GvHD, although there were 2 survivors in the TEN only liver transplant subset and 3 survivors in the TEN/GvHD group of the Hematopoietic transplant patients. In the TEN/GvHD subset, more hematopoietic transplant patients were alive compared to the liver transplant patients, $p=.0003$.

Comparison of Demographic Characteristics of Patients with TEN only and TEN/GvHD

Table 5 depicts the general characteristics of patient groups by disease process (TEN only or TEN/GvHD) regardless of transplant type. TEN and GvHD diagnoses were established by biopsy in 24 (71%) of the patients, one did not have a biopsy recorded, and 19

had no record of a biopsy in the publications. These two groups were similar in age and % TBSA. Although there was no statistically significant difference between these two groups, there were more men in the TEN/GvHD group. The severity of illness was reflected in the increased number of survival days to healing or death in the TEN/GvHD group compared to the TEN only groups (median 60 vs 42.5 days). Of interest also was the fact that as a comparison, the start day for TEN and GvHD were similar (median 22 vs 25 days); however, in cases diagnosed with concomitant TEN/GvHD, TEN was more likely to occur after the GvHD had already arisen (median 25.5 vs 32 days). More patients with HSCT developed TEN/GvHD compared to patients with BMT and liver transplants (75% vs 63% vs 43% respectively).

Table 5: Demographic Characteristics of Patients with TEN or TEN/GvHD after Transplantation

Group mean±sd (median)	TEN	TEN/GvHD
#	14	20
Age (yrs)	39.1±16.7 (41)	34.9±17.0 (29)
Sex (Male/Female)	6M/7F	16M/5F
% TBSA n=22	55.0±32.1 (50)	54.7±24.7 (55)
Survival from Transplant (Days) n=28	108.6±175.0 (42.5)	102.0±116.0 (60)
Time to Engraft (days) n=4	--	15.3±5.5 (16.5)
Start Day GvHD n=13	--	28.0±18.2 (25.5)
Start Day TEN n=31	31.2±40.2 (22)	65.2±86.1 (32)
BMT n=19	7 (37%)	12 (63%)
HSCT n=8	2 (25%)	6 (75%)
Liver n=7	4 (57%)	3 (43%)
Mortality	10 (71.4%)	19 (95%)

TEN= toxic epidermal necrolysis; GvHD= graft versus host disease; BMT= Bone marrow transplant; HSCT= Hematopoietic Stem Cell Transplant

TEN only versus TEN/GvHD in Patients with Hematopoietic and Liver Transplantation

Although the numbers were small, there were more males in the TEN/GvHD group (15 of 21, 71%), Table 6. The genders were more equally distributed in the TEN only group. Combined TEN/GvHD and TEN only subsets had more males, 21 of 34 (63.6%). The patients with liver transplants were older compared to those in the HSCT groups. The hematopoietic group had more patients with TEN/GvHD compared to the liver transplant group, $p=.01$. There were also significantly more deaths in the TEN/GvHD group with liver transplants compared to the TEN only group, $p=.002$. Table 7 illustrates that patients with HSCT had the best survival in the TEN/GvHD compared to BMT recipients. BMT recipients tended to be younger, especially in the TEN/GvHD group; there was no significant difference in %TBSA, time to engraftment, the start day of GvHD. In the HSCT subset, the TEN group had the longest survival. Two patients had delayed GvHD compared to onset of their TEN.

Table 6: Hematopoietic and Liver Transplantation Demographic Characteristics

Group mean±sd (median)	BMT and HSCT		Liver	
	TEN	TEN/GvHD	TEN	TEN/GvHD
SubSet				
#	9	18	5	2
Mortality # (%)	9 (100%)	15 (83%)	3 (60%)	2 (100%)
Age (yrs)	35.4±12.2 (36)	33.4±16.2 (28)	45.2±22.4 (55)	48.0±25.5 (48)
Sex (Male/Female)	4M/5F	12M/6F	2M/2F	3M/0F
% TBSA	46.0±26.1 (50)	56.3±24.6 (60)	100.0±0 (100)	30.0±0 (30)
Survival from Transplant (Days)	123.2±230.5 (34)	121.0±120.5 (81.5)	70.3±32.8 (72.5)	43.0±12.7 (52)
Time to Engraft (days)	--	15.3±5.5 (16.5)	--	--
Start Day GvHD	500±0 (500)	27.2±19.5 (25.5)	--	32.0±14.1 (32)
Start Day TEN	16.8±7.8 (17)	69.2±90.0 (32.5)	48.4±57.2 (24.5)	28.5±4.9 (27)

TEN= toxic epidermal necrolysis; GvHD= graft versus host disease; BMT= bone marrow transplant; HSCT= hematopoietic stem cell transplant

Table 7. Demographic Characteristics of Patients with Hematopoietic Transplantation in the TEN and TEN/GvHD subsets

Group mean±sd (median)	BMT		HSCT	
	TEN	TEN/GvHD	TEN	TEN/GvHD
SubSet				
#	7	12	2	6
Mortality # (%)	7 (100%)	11 (92%)	2 (100%)	4 (67%)
Age (yrs)	35.4±13.2 (37)	28.8±10.4 (25.5)	35.0±0 (35)	42.6±22.4 (47.5)
% TBSA	45.0±30.0 (40)	52.0±24.1 (52.5)	50.0±0 (50)	45.0±26.0 (80)
Survival from Transplant (days)	33.3±11.0 (34)	98.1±78.6 (63)	303.0±410.1 (303)	171.4±185.4 (100)
Time to Engraft (days)	--	16.5±3.5 (16.5)	--	14.0±8.5 (14)
Start Day GvHD	--	23.7±11.7 (25.5)	--	32.5±29.1 (23.5)
Start Day TEN	12.5±13.4 (12.5)	40.3±37.6 (30.5)	19±4.8 (17)	127.0±135.7 (86)

TEN= toxic epidermal necrolysis; GvHD= graft versus host disease; BMT= bone marrow transplant; HSCT= hematopoietic stem cell transplant

Discussion

The literature regarding TEN only and TEN/GvHD in bone marrow, hematopoietic stem cell and liver transplantation consists entirely of retrospective series and case reports. Development of both TEN and GvHD after hematopoietic or liver transplantation heralded a poor prognosis for patients. TEN was frequently precipitated by co-trimoxazole and allopurinol, medications frequently used during transplantation. GvHD was more likely to start before TEN if both were diagnosed. If Grade IV GvHD occurred, it was difficult to determine if TEN had also complicated the picture. More patients with HSCT developed TEN/GvHD compared to patients with BMT and liver transplants. TEN only and TEN/GvHD are either rarely diagnosed or under-reported in the literature. Graw et al described TEN/GvHD in a case report in 1970 and many authors have since written about their experiences, Tables 2 and 3. Skin manifestations were the most common sign of solitary acute GvHD, and TEN was described as a more severe manifestation [7]. There was no mention in the case reports of liver or intestinal symptoms or toxicity. Historically described in the context of drug-reactions, TEN is increasingly recognized as a complication in the transplant world; patients are exposed to many medications, which are known to trigger the occurrence of Stevens-Johnson Syndrome and TEN. In this review of the literature, there was only a 14.7 % survival for patients undergoing BMT, HSCT or liver transplantation if they succumbed to either TEN only or TEN/GvHD. There has been only one report of a patient who developed TEN 4 months after a

kidney transplant caused by co-trimoxazole used as treatment for a pneumonia [30]. Of cases with concomitant TEN and GvHD, nearly half, 14 of 30 (47%) had high suspicion for drug-induced TEN. Co-trimoxazole was the predominant drug implicated in these cases. Average time of presentation for both GvHD and TEN after transplantation was 25 days (mean calculated). Steroid therapy was used to a varying degree, but it was difficult to determine the impact on patient outcome. The number one cause of mortality was infection, 22 of 29 (76%) cases, either via overwhelming sepsis, pneumonia, or CNS involvement by invasive, opportunistic organisms, Tables 2 and 3. Outcome was universally poor with overall mortality approaching 85%, regardless of treatment.

Any Tests to Distinguish TEN from GvHD?

Distinguishing between these two entities is not simply one of semantics. Treatment for solitary TEN has been different from that for solitary GvHD, involving cessation of offending medications, and supportive treatment. Unlike for GvHD, the use of steroids in TEN, while controversial, is increasingly recognized as being detrimental to outcome in the late stages of the disease [31,32]. Ostlere et al described TEN following liver transplantation, while Schulz et al illustrated the dilemma of distinguishing between TEN and GvHD, also post orthotopic liver transplantation [14,20]. GvHD has been described in 35 to 50% of HSCT recipients, yet prevalence of extensive skin involvement in high grade GvHD with concurrent clinical TEN is low [33]. The incidence of isolated steroid

refractory Grade IV skin GvHD with mucocutaneous involvement in the absence of other organ involvement is very rare and this should raise the suspicion of TEN. There is general agreement that GvHD with severe cutaneous manifestations and TEN can simultaneously co-exist. Regardless of whether TEN in this context is medication- or GvHD- induced, the latter etiology represents an extreme on the GvHD severity spectrum. Realizing this concept of possible co-existence affects the management of these conditions, especially when therapy such as steroid medication is controversial and possibly detrimental.

The issue of proving concurrent GvHD and TEN is often extremely difficult, especially when skin biopsies have few if any disparate histological details which differentiate one condition from the other. Demonstration of macrochimerism (significant number of donor lymphocytes) within a recipient's circulating lymphocyte pool has been argued to be the only definitive means of proving a conclusive diagnosis of GvHD [21,34]. However, this may not always be feasible or practical. Additionally, proof of GvHD does not imply the presence of TEN; this may be a more relevant test if TEN is obvious and the diagnosis of GvHD is questionable. Given the lack of clarity in distinguishing these two conditions or proving that they are co-existing, clinical parameters should be utilized to influence diagnostic suspicions and management. Relevant historical information such as medication exposure, especially to high-risk drugs such as sulfonamides, allopurinol, etc., should be considered. Although the vast majority of combined TEN/GvHD cases are medication-induced, it should be remembered that there are instances where it may also occur without a definitive link to medications [12,16].

Many of the authors in this literature review, ourselves included, continued to use steroids despite acknowledging the presence of concomitant TEN. Use of corticosteroids remains the cornerstone of acute, solitary GvHD treatment despite their limited efficacy and considerable toxicity [33].

Several cytokine and immunologic studies have been reported for both TEN and GvHD [17,35-38]. Correia et al compared the IL-10, IL-6, and TNF-alpha cytokine levels in TEN and GVHD patient sera and found them to be significantly elevated in TEN and acute GvHD compared to normal blood donors [17]. Granulysin was considered at one point to be a distinguishing mediator between TEN and GvHD, Grade IV, but has been identified as significantly elevated in both conditions contributing to keratinocyte death [39,40]. Others have noted that cytokeratin-15-basal epithelial cells are more likely to be targeted in acute GvHD than in TEN [41].

Future Treatment Directions

TEN only and TEN/GvHD are rare and difficult to diagnose in patients who have undergone hematopoietic or liver transplantations. Two recent developments reported in the literature may shed some light and direction in improving survival in patients undergoing transplantation. Great strides have been achieved in identifying patient genetic susceptibilities to medications, which can precipitate SJS and TEN [2]. The plethora of medicines the patients are exposed to during the transplantation process opens a Pandora's box of drug metabolites, which may be deleterious in genetically susceptible patients [42]. Testing major histocompatibility complexes (MHC) may identify the ethnicity of patients who should not receive allopurinol, sulfa drugs, or other medications during their transplant

treatment and recovery phases, and thereby, decrease the risk of developing SJS and TEN complications [2,42-44]. In their review article, Paquet and Piérard provided a compilation of HLA complexes which made patients susceptible to developing SJS/TEN when exposed to specific medications, many of which are used during the transplantation and recovery process: HLA-A2, HLA-A29, HLA-A*0206, HLA-B12, HLA-B*1502, HLA-B*5801, HLA-DR4, HLA-DR7 [45].

Although still controversial, recent literature reports have noted that cyclosporine, which has been used successfully to treat GvHD in patients who have received hematopoietic or solid organ transplantations, may actually be beneficial in reducing mortality in patients with TEN [46-49].

Authors still caution that analysis of non-randomized case series, retrospective and prospective studies of this rare condition may be limited in confirming the benefit of cyclosporine for SJS and TEN patients [46]. In a retrospective study of 174 patients, those receiving cyclosporine had a higher frequency of acute renal failure [46]. Based on the report by González et al, Roujeau et al commented about the possible benefits of cyclosporine treatment for SJS and TEN patients, provided treatment recommendations, and noted that the RegiSCAR group in Europe will be developing a registry of epidermal necrolysis cases treated with cyclosporine to confirm or disprove the benefits in these conditions. If proven to be beneficial for GvHD and TEN, treatment with cyclosporine post-transplantation may contribute to improved survival for patients who develop TEN or TEN/GvHD [48,49].

Acknowledgement

J Jorge and A Kowal-Vern contributed equally in the concept and design of the study, literature review and analysis, drafting, critical revision and editing, and final approval of the final version. H C. Fung and SJ Poulakidas contributed equally in the critical revision and editing, and final approval of the final version.

References

1. Lyell A (1956) Toxic epidermal necrolysis: an eruption resembling scalding of the skin. *Br J Dermatol* 68: 355-361.
2. Dodiuk-Gad RP, Chung W-H, Valeyrie-Allanore L, Shear NH (2015) Stevens-Johnson Syndrome and Toxic Epidermal Necrolysis: an Update. *Am J Clin Dermatol* 16: 475-493.
3. Sundram U (2014) A review of important skin disorders occurring in the posttransplantation patient. *Adv Anat Pathol* 21: 321-329.
4. Goldman JM, Johnson SA, Catovsky D, Wareham NJ, Galton DA (1981) Autografting for chronic granulocytic leukemia. *N Engl J Med* 305: 700-707.
5. Körbling M, Freireich EJ (2011) Twenty-five years of peripheral blood stem cell transplantation. *Blood* 117: 6411-6416.
6. Bensinger WI, Martin PJ, Storer B, Clift R, Forman SJ, et al. (2001) Transplantation of bone marrow compared with peripheral blood cells from HLA-identical relatives in patients with hematologic cancers. *N Eng J Med* 344: 175-181.
7. Graw RG, Rogentine GN, Leventhal BG, Halterman RH, Berard C, et al. (1970) Graft-vs-host reaction complicating HLA-matched bone marrow transplantation. *Lancet* 2: 1053-1055.
8. Peck GL, Elias PM, Graw RG (1972) Graft-vs-host reaction and toxic epidermal necrolysis. *Lancet* 2: 1151-1153.
9. Peck GL, Herzog GP, Elias PM (1972) Toxic epidermal

- necrolysis in a patient with graft-versus host reaction. *Arch Dermatol* 105: 561-569.
10. Friedman HZ, Arias AM, Catchatourian R, Fretzin DF (1984) Toxic epidermal necrolysis following bone marrow transplantation. *Cutis* 34: 158-162.
 11. Merle C, Blanc D, Flesch M, Carbillet JP, Miguet JP, et al. (1990) A picture of epidermal necrolysis after hepatic allograft. Etiologic aspects. *Ann Dermatol Venereol* 117: 635-639.
 12. Villada G, Roujeau JC, Cordonnier C, Bagot M, Kuentz M, et al. (1990) Toxic epidermal necrolysis after bone marrow transplantation: study of nine cases. *J Am Acad Dermatol* 23: 870-875.
 13. McDonald BJ, Singer JW, Bianco JA (1992) Toxic epidermal necrolysis possible linked to aztreonam in bone marrow transplant patients. *Ann Pharmacother* 26: 34-35.
 14. Ostlere LS, Harris D, Burroughs AK, Rolles K (1992) Toxic epidermal necrolysis after hepatic transplantation. *Arch Dermatol* 128: 1550-1551.
 15. Neumann U, Knoop M, Langehr JM, Kaisers U, Bechstein WO, et al. (1995) Graft -vs- -host reaction: a severe complication after orthotopic liver transplantation. *Zentralbl Chir* 120: 478-481.
 16. Takeda H, Mitsuhashi Y, Kondo S, Kato Y, Tajima K (1997) Toxic epidermal necrolysis possibly linked to hyperacute graft-versus-host disease after allogeneic bone marrow transplantation. *J Dermatol* 24: 635-641.
 17. Correia O, Delgado L, Barbosa IL, Domingues JC, Azevedo R, et al. (2001) CD8+ lymphocytes in the blister fluid of severe acute cutaneous graft-versus-host disease: further similarities with toxic epidermal necrolysis. *Dermatol* 203: 212-216.
 18. Zakrzewski JL, Lentini G, Such U, Duerr A, Tran V, et al. (2002) Toxic epidermal necrolysis: differential diagnosis of an epidermolytic dermatopathy in a hematopoietic stem cell transplant recipient. *Bone Marrow Transplant* 30: 331-333.
 19. Schaich M, Schäkel K, Illmer T, Ehninger G, Bornhäuser M. (2003) Severe epidermal necrolysis after treatment with imatinib and consecutive allogeneic hematopoietic stem cell transplantation. *Ann Hematol* 82: 303-304.
 20. Schulz JT, Sheridan RL (2006) Severe desquamating disorder after liver transplant: Toxic epidermal necrolysis or graft versus host disease? *J Burns Wounds* Jan 5: 1-5.
 21. Arvidson J, Kildal M, Linde T, Gedeborg R (2007) Toxic epidermal necrolysis and hemolytic uremic syndrome after allogeneic stem-cell transplantation. *Pediatr Transplant* 11: 689-693.
 22. Hilgendorf I, Casper J, Sviland L, Prall F, Junghans C, et al. (2007) Toxic epidermal necrolysis after allogeneic haematopoietic stem cell transplantation. *Bone Marrow Transplant* 39: 245-246.
 23. Joo DJ, Kim SJ, Ju MK, Park JP, Huh KH, et al. (2009) Stevens-Johnson Syndrome in a liver transplant recipient. *Transpl Int* 22: 667-669.
 24. Wäsch R, Jakob T, Technau K (2012) Stevens-Johnson/toxic epidermal necrolysis overlap syndrome following lenalidomide treatment for multiple myeloma relapse after allogeneic transplantation. *Ann Hematol* 91: 287-289.
 25. Jeanmonod P, Hubbuch M, Grünhage F, Meiser A, Rass K, et al. (2012) Graft-versus-host disease or toxic epidermal necrolysis: diagnostic dilemma after liver transplantation. *Transplant Infect Dis* 14:422-426.
 26. Tomiano J, Keegan T, Miloh T, Kerkar N, Mercer S, et al. (2012) Stevens-Johnson Syndrome after *Mycoplasma pneumoniae* infection in pediatric post-liver transplant recipient: case report and review of the literature. *Pediatr Transplant* 16: E74-E77.
 27. Macedo FI, Faris J, Lum LG, Gabali A, Uberti JP, et al. (2014) Extensive toxic epidermal necrolysis versus acute graft versus host disease after allogeneic hematopoietic stem-cell transplantation: challenges in diagnosis and management. *J Burn Care Res* 35: e431-e435.
 28. Gomulka J, Wilson BD, Joyce JC (2014 Sep) Toxic epidermal necrolysis due to voriconazole: case report and review. *Dermatol Online J* 16: 20.
 29. Birch J, Duerst R, Jacobsohn D (2008) *Mycoplasma pneumoniae* and atypical Stevens-Johnson Syndrome in a Hematopoietic Stem Cell transplant recipient. *Pediatr Blood Cancer* 50: 1278-1279.
 30. Lacouture ME, Hsieh FH (2003) Skin rash in a transplant patient receiving multiple drugs. *Cleveland Clin J Med* 70: 1071-1075.
 31. Halebian PH, Corder VJ, Madden MR, Finklestein JL, Shires GT (1986) Improved burn center survival of patients with toxic epidermal necrolysis managed without corticosteroids. *Ann Surg* 204: 503-512.
 32. Roujeau JC (1999) Treatment of severe drug eruptions. *J Dermatol* 26: 718-722.
 33. Koreth J, Antin JH (2008) Current and future approaches for control of graft-versus-host disease. *Expert Rev Hematol* 1: 111.
 34. Taylor AL, Gibbs P, Sudhindran S, Key T, Goodman RS, et al. (2004) Monitoring systemic donor lymphocyte macrochimerism to aid the diagnosis of graft-versus-host disease after liver transplantation. *Transplantation* 77: 441-446.
 35. Correia O, Delgado L, Barbosa IL, Campilho F, Fleming-Torrinha J (2002) Increased interleukin 10, tumor necrosis factor α , and interleukin 6 in blister fluid of toxic epidermal necrolysis. *J Am Acad Dermatol* 47: 58-62.
 36. Hermanns-Lê T, Paquet P, Rousseau AF, Arrese JE, Piérard GE (1999) Regulatory function of Factor-XIIIa-positive dendrocytes in incipient toxic epidermal necrolysis and graft-versus-host reaction. *Dermatol* 198: 184-186.
 37. Villada G, Roujeau J-C, Clérici T, Bourgault, Revuz J (1992) Immunopathology of toxic epidermal necrolysis. *Arch Dermatol* 128: 50-53.
 38. Nassif A, Moslehi H, Le Gouvello S, Bagot M, Lyonnet L, et al. (2004) Evaluation of the potential role of cytokines in toxic epidermal necrolysis. *J Invest Dermatol* 123: 850-855.
 39. Chung WH, Hung S-I, Yang J-Y, Su S-C, Huang S-P, et al. (2008) Granulysin is a key mediator for disseminated keratinocyte death in Stevens-Johnson syndrome and toxic epidermal necrolysis. *Nature Med* 14: 1343-1350.
 40. Nagasawa M, Isoda T, Itoh S, Kajiwara M, Morio T, et al. (2006) Analysis of serum Granulysin in patients with hematopoietic stem-cell transplantation: its usefulness as a marker of graft-versus-host reaction. *Am J Hematol* 81: 340-348.
 41. Zhan Q, Signoretti S, Whitaker-Menezes D, McKeon F, Murphy GF. (2007) Cytokeratin-15-basal epithelial cell targeted in graft-versus-host disease express a constitutive anti-apoptotic phenotype. *J Invest Dermatol* 127:106-115.
 42. Yip VL, Alfirevic A, Pirmohamed M. (2015) Genetics of immune-mediated adverse drug reactions: a comprehensive and clinical review. *Clin Rev Allergy Immunol* 48: 165-175.
 43. Chang CC, Too CL, Murad S, Hussein SH (2011) Association of HLA-B*1502 allele with carbamazepine-induced toxic epidermal necrolysis and Stevens-Johnson syndrome in the multi-ethnic Malaysian population. *Int J Dermatol* 50: 221-224.

-
44. Chung WH, Hung SI (2010) Genetic markers and danger signals in stevens-johnson syndrome and toxic epidermal necrolysis. *Allergol Int* 59: 325-332.
 45. Paquet P, Piérard GE. (2010) New insights in toxic epidermal necrolysis (Lyell's Syndrome): clinical considerations, pathobiology and targeted treatments revisited. *Drug Saf* 33: 189-212.
 46. Poizeau F, Gaudin O, Le Cleach L, Duong TA, Hua C, et al. (2018) Cyclosporine for Epidermal necrolysis: absence of beneficial effect in a retrospective cohort of 174 patients-exposed/unexposed and propensity score-matched analyses. *J Invest Dermatol* 138: 1293-1300.
 47. Ng QX, Deyn MLZQD, Venkatanarayanan N, Ho CYX, Yeo W-S. (2018) A meta-analysis of cyclosporine treatment for Stevens-Johnson syndrome/toxic epidermal necrolysis. *J Inflammation Res* 11: 135-142.
 48. González-Herrada, Rodríguez-Martin S, Cachafeiro L, Lerma V, González O, et al. (2017) Cyclosporine use in epidermal necrolysis is associated with an important mortality reduction: evidence from three different approaches. *J Invest Dermatol* 137: 2092-2100.
 49. Roujeau JC, Mockenhaupt M, Guillaume JC, Revuz J. (2017) New evidence supporting cyclosporine efficacy in epidermal necrolysis. *J Invest Dermatol* 137: 2047-2049.

Copyright: ©2018 Areta Kowal-Vern, et al. This is an open-access article distributed under the terms of the Creative Commons Attribution License, which permits unrestricted use, distribution, and reproduction in any medium, provided the original author and source are credited.