

Third Molar: Optional Tooth

Maria Concepcion Parreñas DMD, MScD

Associate Professor at University of the East, College of Dentistry, Graduate School, Philippines

***Corresponding author**

Maria Concepcion Parrenas, Associate Professor at University of the East College of Dentistry, Graduate School, Philippines

Submitted: 27 Jun 2020; Accepted: 17 Jul 2020; Published: 01 Aug 2020

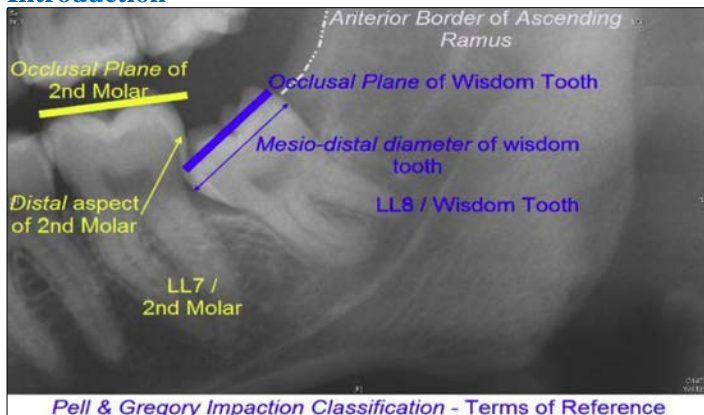
Abstract

There is always a nagging question, which heightens my curiosity on the appropriate removal of an impacted third molar in this specific situation: What if you have a carious or beyond-repair second molar or second bicuspid? Will you try to heroically upright the mesially and horizontally impacted third molars? How about resorbed second molar or a third molar in close proximity of mandibular inferior alveolar nerve.

Uprighting of mesially impacted tilted molars is the recommended treatment and should be done as soon as possible. If not properly corrected, mesially impacted molars may lead to complications such as elongation of opposing teeth, periodontal problems on the mesial side of the affected teeth, caries in the unerupted molars, temporomandibular disorders and poor oral hygiene. Some clinical procedures have been used to upright the third molar. Is it really worth working to leave the third molar be uprighted or have it surgically removed? As most maxillofacial oral surgeons, prefer.

Objectives: The purpose of this study is to really evaluate if it is necessary to remove third molars and to assess when to upright impacted third molars.

Introduction



Third molar removal is one of the most common dental surgical procedures in the United States, representing 95% of all extractions among patients aged 16 to 21 years in an insured population

•Rates of paresthesia and temporomandibular joint disorder were higher after third molar removal.

There are 5 million people in the United States each year at an annual cost of over \$3 billion who are undergoing surgery

of impacted third molars .In fact, there are 50% of upper third molars classified as impactions which are normally developed teeth and most of which will erupt with minimal discomfort. There is no evidence of widespread third-molar infection and pathology or of medical necessity to justify so much surgery. So much so that there are, only three fourths of developing third molars are mesioangular.

At times impactions at the time of extraction are not impacted at all, but would erupt into a normal position in the mouth if there were proper orthodontic intervention. Thus, there can be no excuse for tolerating so many unnecessary extractions on millions of unsuspecting people that misled them at risk sometimes with much iatrogenic nerve injury. And that leads to public health hazards.

• Periodontal attachment loss and caries at the distal sites of second third molar removal can result in various types of morbidity, such as:

1. Pain
2. Swelling
3. Bleeding
4. Infection
5. Dry socket
6. Trismus

7. Paresthesia
8. Temporomandibular joint disorders {not affected by extraction condition}

There are only about 12% of truly impacted teeth that are related to pathological conditions (i.e. cysts and damage to adjacent teeth). Most discomfort of erupting wisdom teeth is teething.

Pathologies caused by impacted teeth:

- a) Resorption of mandibular second molar
- b) Decay of mandibular second molar
- c) Periodontal bone loss of the distal wall of the crown of second molar
- d) Pericoronitis
- e) Operculum
- f) Dentigerous cyst of maxillary canine
- g) Ameloblastoma.

Rindler examined the data from the casts and lateral oblique radiographs of 78 patients between 10 and 15 years of age, with a Class II initial malocclusion and crowding in the lower arch.

Cavanaugh, in a clinical and radiographic evaluation of third molars after second molar extractions in 25 patients, had some kind of orthodontic treatment, suggesting that third molars usually successfully erupt into the space provided by the removed second molars. There were two million dollars' worth of odontectomy done two years ago in the United States. And the majority of them are asymptomatic with no pathology at all.

Methods of Clinical Research

We used some of our patients in our clinic both male and female before 12 years of age beforehand after being subjected for orthodontic treatment and some adult patients with mesially impacted third molars but with carious and missing first or second molars. *This was a prospective study over a four-year period. Their diagnosis of impacted maxillary and mandibular third molar was made thru clinical and radiological examinations. The age ranges from 8-29 years of age with missing first molars and carious or resorbed second molars. Most of the patients experimented were being subjected to orthodontic treatment.*

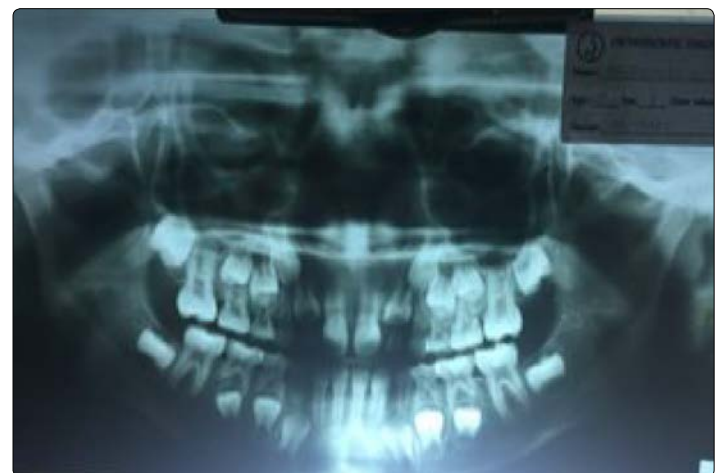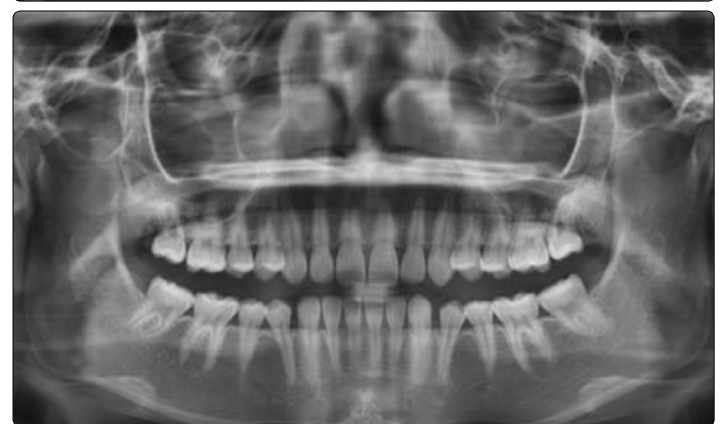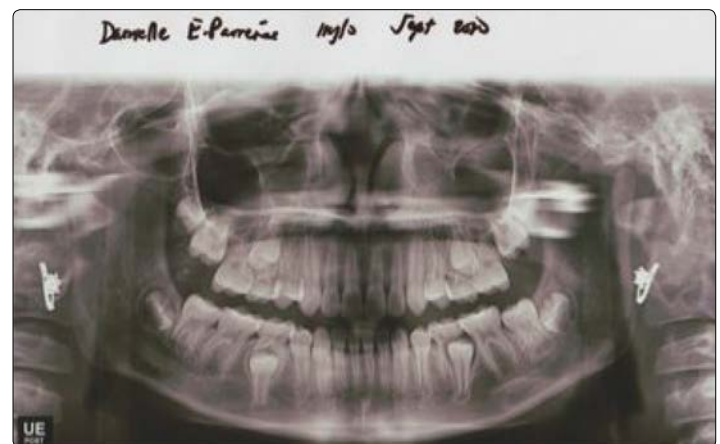Results

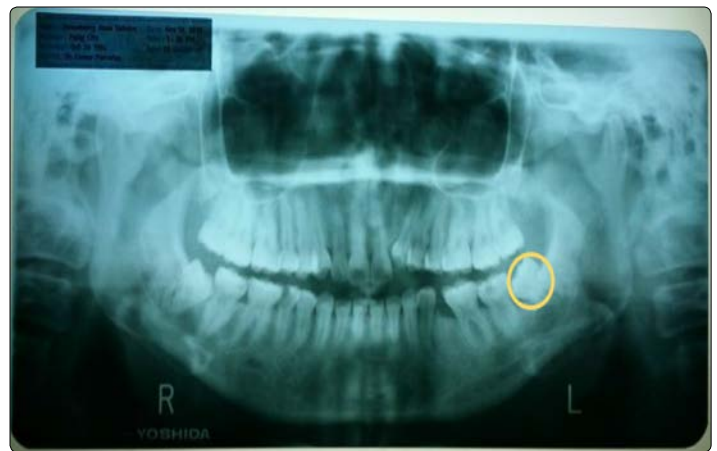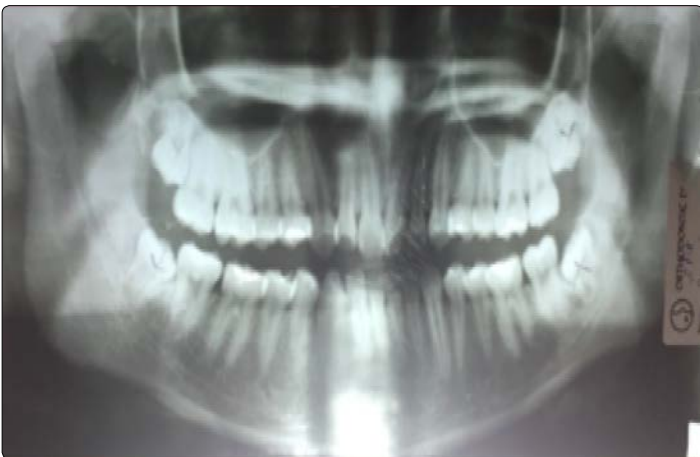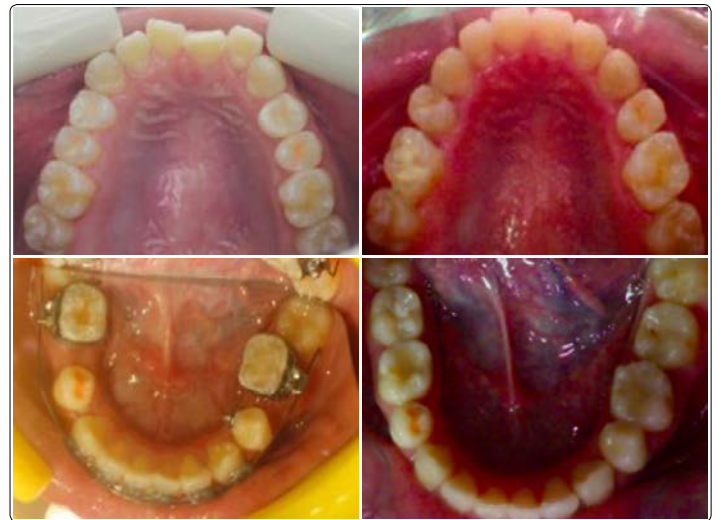
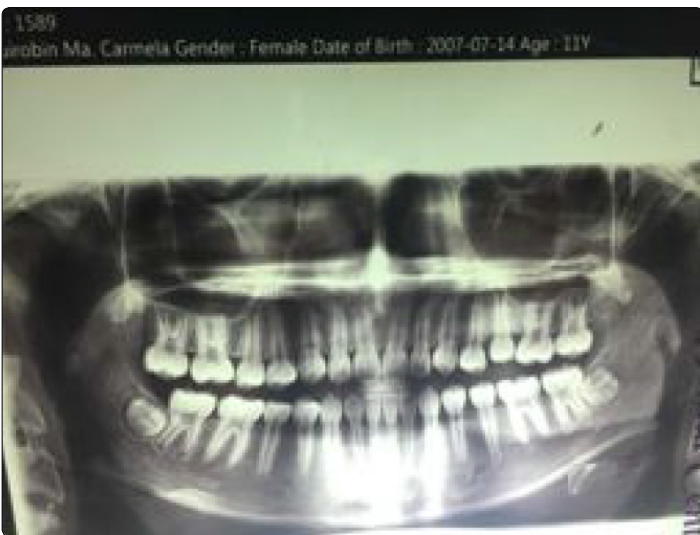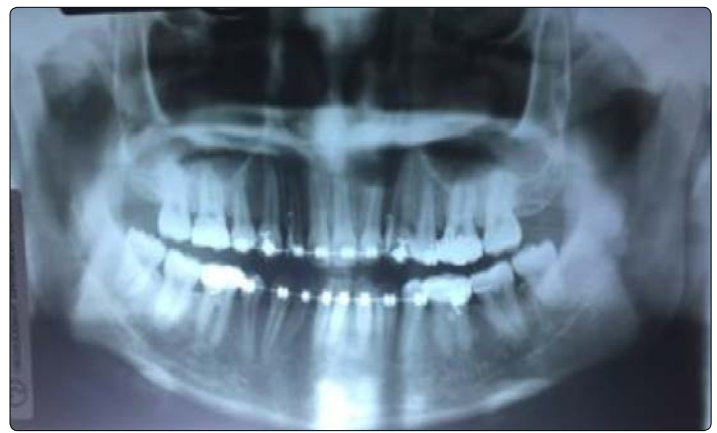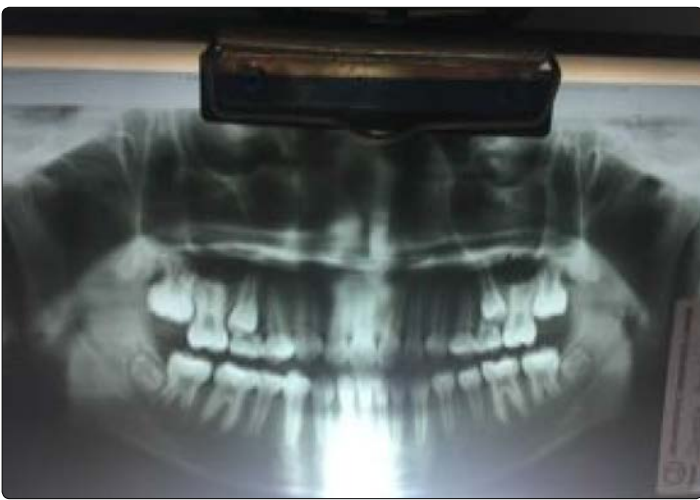Orthodontic uprighting technique for effective treatment of impacted third molars, exposed or unexposed, is described. When used with TADS along with Australian wire, 020 is the other technique that I used. The other one is with several wire mechanics without using TADS but with the utilization of some uprighting techniques that are simple and effective in positioning impacted third molars.

The patients were treated with different techniques and had both their second mandibular molars extracted at the same time

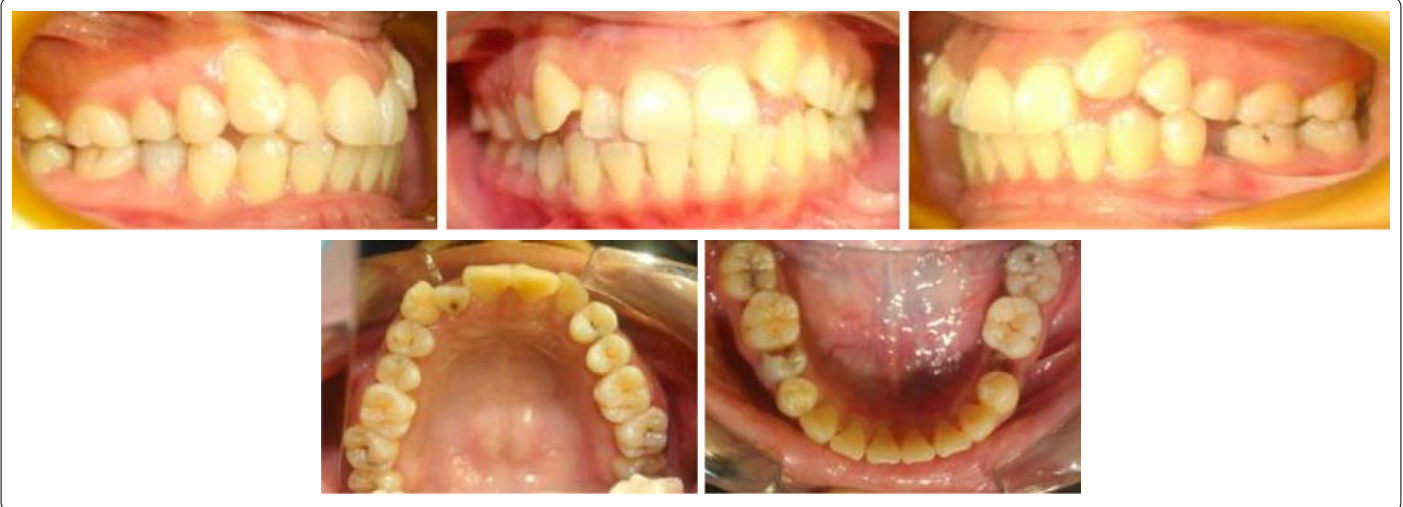with the initiation of root development of the third molars. In 21 cases, no additional orthodontic treatment was involved and, in the rest of the cases, lower first molars were moved distally with the use of activators (3 cases) and fixed appliances (15cases). As they reported in the summary of their study, the third molars successfully replaced the second molars in most cases (77%).

Before the age of 13, at least 12.5, with no roots completion for the third molars, with the absence of 2nd Molars D. Parrenas 18 YO after expansion QUEROBIN 8 YO before 11 YO after ortho treatment Anna at 12 yo before Anna at 16yo after orthotreatment w 3M, WO 2M S. Dulatre 16 yo before 19 yo after orthodontic treatment [1-18].

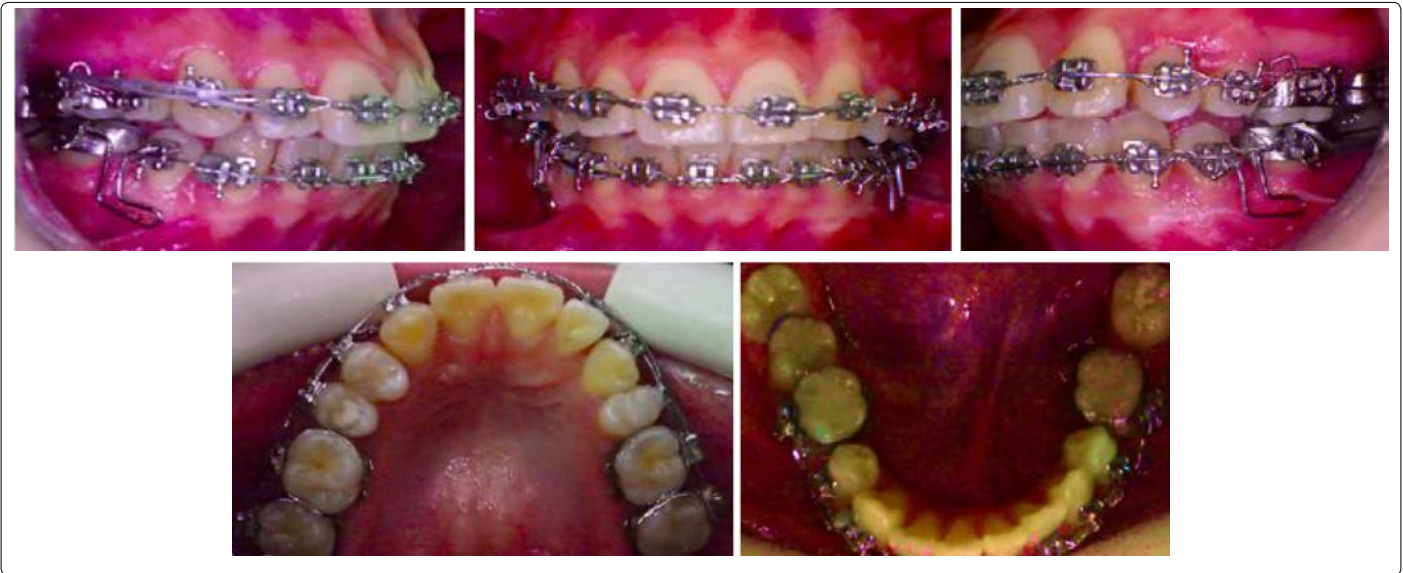



RESORPTION 2M

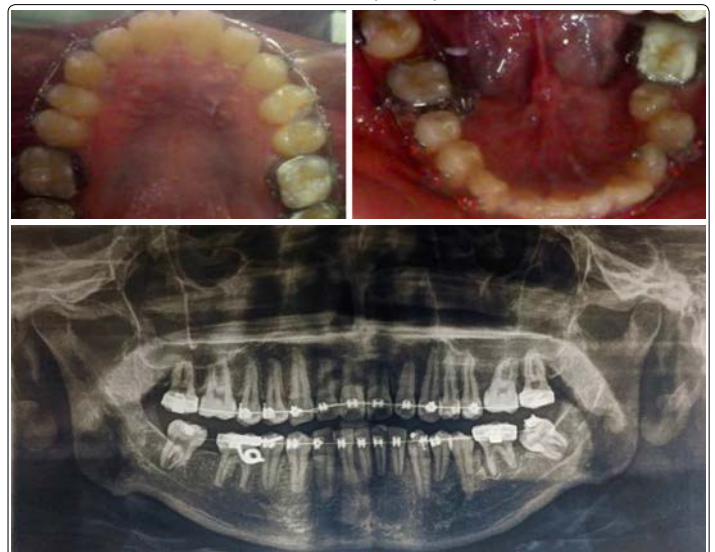
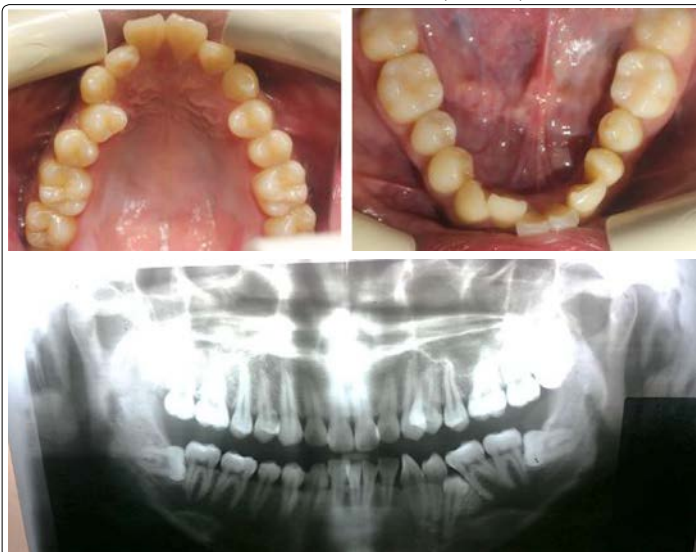
POST OP



Dela Rosa at 24 Y OLD (Before)

Dela Rosa at 29 Y OLD (After) w/o 2M w/ 3M



Reasons of retaining impacted third molars to erupt more than the 2nd molar

1. Second molars are beyond restoration so that it will not survive longer because of the presence of cavities compared to a healthy third molar.
2. For the purpose of preventing cases that involve pathological condition such as resorption or caries in second molars, cysts and pericoronitis.
3. Post-surgical complications that are difficult for patients to accept.
4. Post orthodontic stability.

Conclusion

The decision whether or not to remove third molars could be scheduled until the end of orthodontic treatment except for situations in which the removal of third molar is necessary since the beginning of treatment. A follow up evaluation of third molar position during treatment can present to a more realistic decision prognosis of these teeth. The ideal moment to determine whether or not to remove third molars is also under debate. Moreover, it is a daunting task to predict this biological condition with any degree of reliability. No evidence to support or refute prophylactic removal of asymptomatic impacted third molars, even in adults. These systematic reviews contraindicate the prophylactic removal of third molars in order to prevent late lower anterior crowding.

If you compare the opinion of orthodontists and oral and maxillofacial surgeons, it becomes clear that the latter indicate prophylactic removal of third molars to prevent crowding more often than the former. Whenever we are planning for extraction of third molars, we dentists should have a valid reason, one that takes into account future treatment planning from an orthodontic, surgical, periodontal and/or prosthetic point of view. At the same time which should only be indicated with the purpose of preventing cases that involve pathological processes, such as root resorption or caries in second molars, cysts and pericoronitis for the patient's own benefits.

References

1. Kruger E, Thomson WM, Konthasinghe P (2001) Third molar outcomes from age 18 to 26: findings from a population-based New Zealand longitudinal study. *Oral Surg Oral Med Oral Pathol Oral Radiol Endod* 92: 150-155.
2. Celikoglu M, Miloglu O, Kazanci F (2010) Frequency of agenesis, impaction, angulation, and related pathologic changes of third molar teeth in orthodontic patients. *J Oral Maxillofac Surg* 68: 990-995.
3. Mettes TG, Ghaemina H, Nienhuijs MEL, Perry J, van der Sanden WJM, et al. (2012) Surgical removal versus retention for the management of asymptomatic impacted wisdom teeth (Review). *Cochrane Database of Systematic Reviews* 2012: CD003879.
4. Dodson TB (2012) How many patients have third molars and how many have one or more asymptomatic, disease-free third molars? *J Oral Maxillofac Surg* 1: S4-S7.

5. Bui CH, Selodin EB, Dodson TB (2003) Types, frequencies and risk factors for complications after third molar extraction. *J Oral Maxillofac Surg* 61: 1379.
6. Slade GD, Foy SP, Daniel A Shugars, Ceib Phillips, Raymond P White Jr (2004) The impact of third molar symptoms, pain and swelling, on oral health-related quality of life. *J Oral Maxillofac Surg* 62: 1118-1124.
7. Blakey GH, Golgen BA, White RP (2007) The Changes in third molar and non-third molar periodontal pathology over time. *J Oral Maxillofac Surg* 65: 1577-1584.
8. Moss KL, Ruvo AT, Offenbachers S, James D Beck, Sally M Mauriello, et al. (2007) Third molars and progression of periodontal disease during pregnancy. *J Oral Maxillofac Surg* 65: 1065-1069.
9. Guven, O, A Keskin, UK Akal (2000) The incidence of cysts and tumors around impacted third molars. *Int J Oral Maxillofac Surg* 29: 131-135.
10. Glosser JW, Campbell JH (1999) Pathologic change in soft tissues associated with radiographically normal third molar impaction. *Br J Oral Maxillofac Surg* 37: 259-260.
11. Nitzan D (1982) Does an impacted tooth cause resorption of the adjacent one? *Oral Med Oral Surg Oral Path* 51: 221-225.
12. National Institute for Health and Clinical excellence. Wisdom teeth – removal. <http://www.nice.org.uk/TA1>
13. Evidence Based Third Molar Surgery (2017) AAOMS. www.aaoms.org/docs/evidence_based_third_molar_surgery.pdf
14. Pogrel MA, Lee JS, Muff DF (2004) Coronectomy: a technique to protect the inferior alveolar nerve. *J Oral Maxillofac Surg* 63: 1447-1453.
15. Jay W Friedman (2007) The prophylactic extraction of third molars: a public health hazard. *Am J Public Health* 97: 1554-1559.
16. Greg J Huang I, Joana Cunha-Cruz, Marilyn Rothen, Charles Spiekerman, Mark Drangsholt, et al. (2014) A prospective study of clinical outcomes related to third molar removal or retention. *Am J Public Health* 104: 728-734.
17. DM Hyam (2018) The contemporary management of third molars. *Australian Dental Association* 63: S19-S26.
18. Sarica I, Derindag G, Kurtuldu E, Naralan ME, Caglayan F (2019) A retrospective study: Do all impacted teeth cause pathology? *Niger J Clin Pract* 22: 527-533.

Copyright: ©2020 Maria Concepcion Parrenas. This is an open-access article distributed under the terms of the Creative Commons Attribution License, which permits unrestricted use, distribution, and reproduction in any medium, provided the original author and source are credited.