

## The Return of the Dragon Faucial Diphtheria

S Gerald Parisutham<sup>1\*</sup>, S Kishan Kumar<sup>2</sup>, S Krithika<sup>3</sup>, C Rajesh<sup>4</sup>

<sup>1,2,3</sup>Department of Otorhinolaryngology, Thanjavur Medical College, Thanjavur

<sup>4</sup>Department of Paediatrics Thanjavur Medical College, Thanjavur

### \*Corresponding author

Dr. S Gerald Parisutham, Senior Assistant Professor, Department of Otorhinolaryngology, Thanjavur Medical College, Thanjavur, Tamil Nadu, India; Email: drgerald94@gmail.com

Submitted: 09 July 2020; Accepted: 16 July 2020; Published: 21 July 2020

### Abstract

Diphtheria is caused by toxin producing strains of gram positive bacilli *Corynebacterium diphtheriae*. Epidemics occur when immunization coverage is inadequate. The characteristic pseudomembrane of diphtheria is formed by necrotic tissue, inflammatory exudates, fibrin and colonies of the organism and bleeds on removal. Other differentials of membranous tonsillitis include infectious mononucleosis, streptococcal pharyngitis and Vincent's angina. Diphtheria should be considered in all cases of membranous tonsillitis in the appropriate epidemiological background, and antitoxin treatment should be initiated promptly.

**Keywords:** *Corynebacterium Diphtheriae*, Diphtheria, Pseudo Membrane, Antidiphtheritoxin

### Case Report

A 11 year old female child referred from private hospital with H/O fever, throat pain, odynophagia for 5 days and treated with parenteral antibiotics with diagnosis as acute membranous tonsillitis and referred to tertiary hospital for further evaluation and management reviewed in ENT OPD.

On examination patient was conscious, febrile with no respiratory distress. Local examination of throat revealed whitish pseudo membrane over the right tonsil and uvula with grade III tonsillar hypertrophy. In view of pseudo membrane indirect laryngoscopy examination not done. No palpable neck nodes. Patient admitted and evaluated further for throat swab culture & sensitivity and all basic investigations.

Gram stain revealed Gram positive bacilli with granules arranged in cuneiform pattern of morphology resembling corynebacterium diphtheria and further Albert stain confirmed green bacilli with metachromatic granules. Blood investigations differential count and coagulation profile with in normal limits. ECG and X ray chest showed no significant abnormality. Patient was on IV fluids and parenteral antibiotics. On confirmation of diphtheria patient was transferred to Paediatric ICU for Diphtheria antitoxin therapy. She was administered 50,000 IU ADS for 3 days. Patient recovered and on ENT follow up no evidence of membrane or pseudo membrane in oropharynx and clinically normal. Prophylaxis with oral erythromycin for 7 days given.

### Discussion

The Hippocrates only first described Diphtheria in the 4th century B.C., during epidemics that emerged across Europe. It was known as 'the strangling angel of children'. 'Diphtheria' meaning leather in Greek, used in describing the greyish white pseudo membrane that deposits on mucous membranes of upper respiratory tract mainly

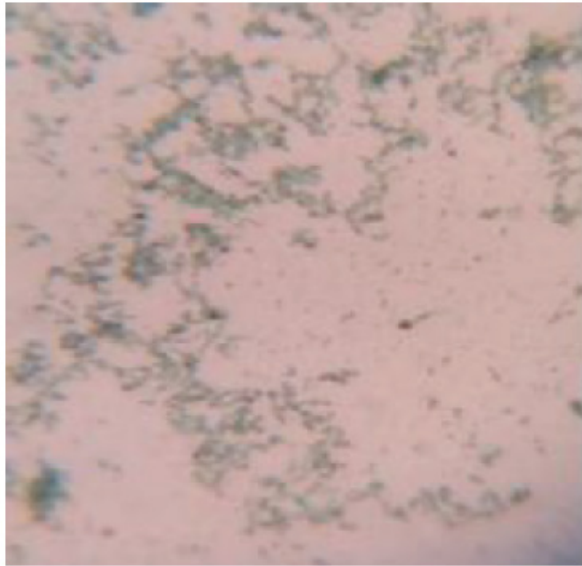
in oropharynx. The causative organism being *Corynebacterium diphtheriae* was discovered by German bacteriologist and physicist Fredrick Löffler and Edwin Löffler and known as *Klebsiella Löffleri*.

The most common type of clinical presentation is faucial diphtheria. Diphtheria is a contagious disease due to toxigenic strains of the pathogen *C. diphtheriae* is usually spread by direct physical contact among humans by droplets or through inhaling aerosols of infected individuals. Beginning with sore throat, low grade fever and later an adherent greyish white membrane over the tonsils, pharynx, and nasal cavity. This thick and fibrinous pseudomembrane, which may dislodge and severely obstruct upper airways to cause stridor in patients to cause sudden life threatening respiratory failure. The major fatality in Diphtheria apart from respiratory failure is life threatening complications including myocarditis and peripheral motor neuropathy. The pathophysiology of diphtheria causing organ damage is due to prototypic, toxigenic exotoxin of bacterium. The virulence factor of exotoxin was first demonstrated by French Pierre-Paul-Émile Roux and Swiss-French Alexandre Émile Jean Yersin. The microbial exotoxins is capable of inhibiting the process of protein biosynthesis to target individual steps of mRNA translation (e.g. initiation, elongation and termination) but also to attack different components of the ribosomal machinery. DT unfold its lethal action, by hijacking a post-translationally modified residue known as diphthamide in its target protein EF2 (eukaryotic translation elongation factor 2). Eventually, EF2 inactivation by DT causes depletion of de novo protein biosynthesis and results in the death of the target cell. Non toxigenic strains may also acquire virulence following lysogenic conversion. Systemic organ damage associated with diphtheria is due to the lethal DT rather than dissemination of blood-borne pathogens. This led to the development of a highly successful toxoid vaccine in which inactivated DT that remains antigenic is able to raise an immune response. Even in immunized

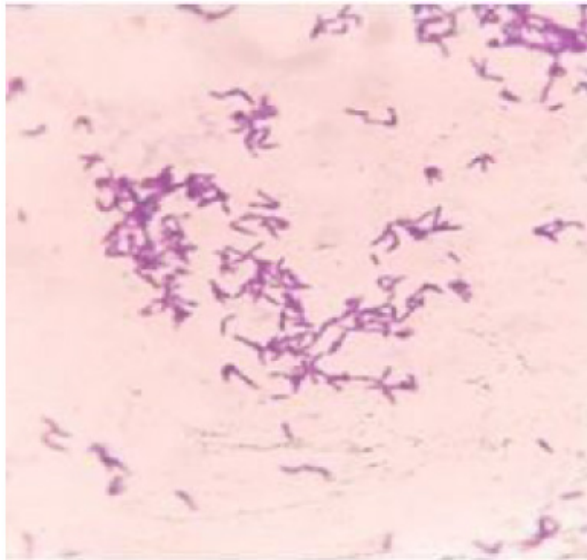
individual antibiotics (e.g. penicillin and erythromycin) are used as part of the treatment of patients who are diagnosed and confirmed Albert stain with diphtheria, prompt and immediate administration of diphtheria antitoxin is most effective in reducing the mortality rate. Immunity against diphtheria infection wanes over time among adults who lose protection from childhood vaccination unless they receive boosters in schedule and mainly defaulters in routine vaccination schedule. It is recommended that individuals at high risk of exposure (i.e. travellers to endemic areas, laboratory and healthcare workers) should receive a booster every 10 years [1-15].

### Conclusion

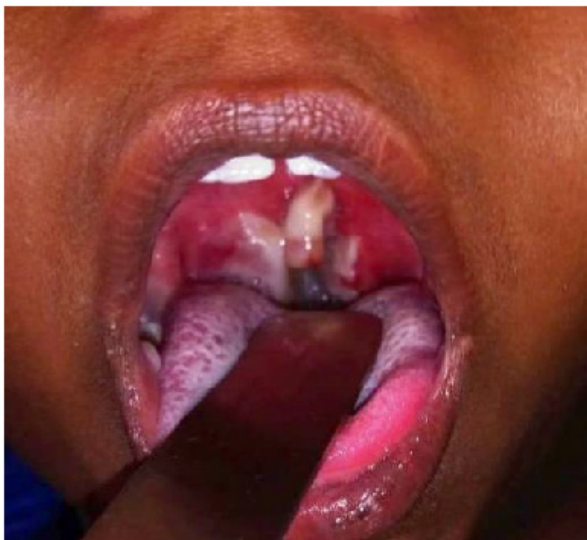The role otolaryngologist in evaluation of every case of membranous tonsillitis should emphasize the recognition of re-emergence of diphtheria by immediate throat swab for Gram stain, & culture and sensitivity apart from immediate airway management. The diagnosis of diphtheria infection is largely driven by clinical suspicion. While awaiting for definitive culture and sensitivity, antibiotics and anti-toxin therapy should be started immediately, to reduce morbidity and mortality associated with the disease.



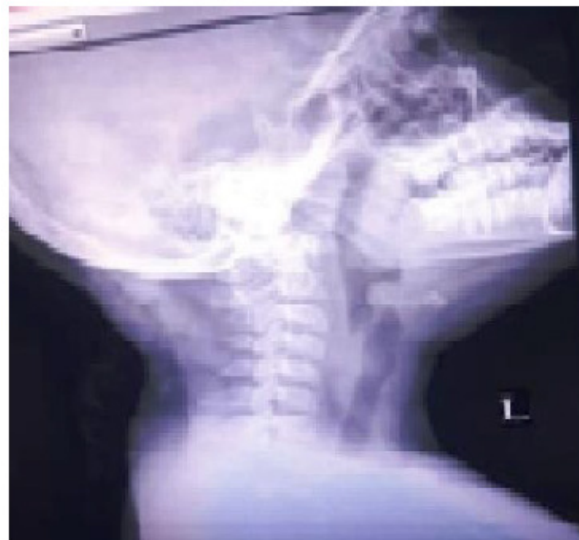**Figure 1:** Albert stain metachromatic granules.



**Figure 2:** Gram stain gram positive bacilli with cuneiform pattern



**Figure 3:** Image pseudomembrane in oropharynx.



**Figure 4:** X-ray soft tissue neck

### References

1. Byard RW (2013) Diphtheria- 'The strangling angel' of children. *J Forensic Leg Med* 20: 65-8.
2. Clarke KEN (2017) Review of Epidemiology of Diphtheria 2000-16. World Health Organisation.
3. Diphtheria Infection. In: Centers for Disease Control and Prevention Diphtheria (2018).
4. The Childhood Immunization Programme in Singapore (2013) Ministry of Health.
5. Moore LSP, Leslie A, Meltzer M, Sandison A, Efstratiou A, et al. (2015) *Corynebacterium ulcerans* cutaneous diphtheria. *Lancet Infect Dis* 15:1100-1107.

- 
6. Murphy JR (1996) *Corynebacterium Diphtheria*.
  7. Hadfield TL, P McEvoy, Y Polotsky, V A Tzinslerling, A Yakovlev (2000) The pathology of diphtheria. *J. Infect. Dis* 181: S116-S120.
  8. Moored A, J M Guérin, N Falfoul-Borsali, C Level (1994) Cutaneous diphtheria. *Rev. Med. Interne* 15: 515-520.
  9. Vitec CR (2006) Diphtheria. *Cur. Top. Microbial. Imanol* 304: 71-94.
  10. Von Graevenitz A (2002) The changing epidemiology of diphtheria in the past two centuries. *Ann. Ig* 14: 1-5.
  11. Kleinman L C (1992) To end an epidemic. Lessons from the history of diphtheria. *New Engl. J. Med* 326: 773-777.
  12. Nekrassova LS, Liudmila M Chudnaya, Victor F Marievski, Victor G Oksiuk, Elena Gladkaya (2000) Epidemic diphtheria in Ukraine, 1991–1997. *J. Infect. Dis* 181: S35-S40.
  13. Niyazmatov BI, Abigail Shefer, Mark Grabowsky, Charles R Vitek (2000) Diphtheria epidemic in the Republic of Uzbekistan, 1993–1996. *Ibid* 181: S104–S109.
  14. Nakao H (2000) Molecular epidemiology of diphtheria re-emerged in Russia // *Nippon Saikingaku Zasshi* 55: 55-67.
  15. Titov L, Valentina Kolodkina, Alina Dronina, Francine Grimont, Patrick A D Grimont (2003) Genotypic and phenotypic characteristics of *Corynebacterium diphtheriae* strains isolated from patients in Belarus during an epidemic period // *J. Clin. Microbial* 41: 1285-1288.

**Copyright:** ©2020 S Gerald Parisutham., This is an open-access article distributed under the terms of the Creative Commons Attribution License, which permits unrestricted use, distribution, and reproduction in any medium, provided the original author and source are credited.