

The Regenerative Treatment of Compressive Radiculo-Neuropathy. Case Report.

Victoria Palinska* and Palinskiy I

Private Scientific Institute International Treatment-Health-Educational Center "Victoria", Ukraine

*Corresponding author

Victoria Palinska, Private Scientific Institute International Treatment-Health-Educational Center "Victoria", Ukraine

Submitted: 23 June 2017; Accepted: 30 June 2017; Published: 04 July 2017

Abstract

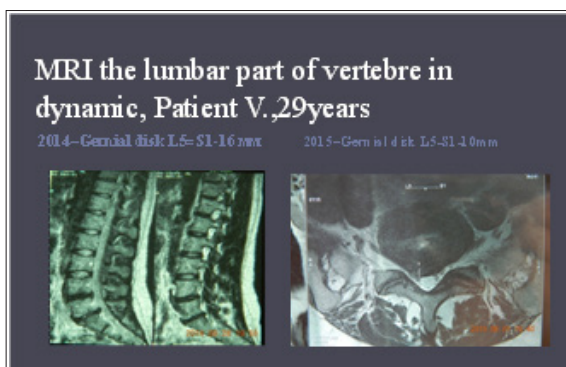
Statement about the Abnormal Medical Condition

Although disc herniation is the most common etiology of compressive radiculopathy [1,2]. Lumbar radiculopathy is indication to operative surgery [3-5]. Purpose of this study is to show the results of regenerative treatment of compressive radiculo-neuropathy in young girl without neurosurgical treatment. Case report: patient V., 24 years had been treating in Private Scientific Institute ITHEC "Victoria" for 1 year with diagnosis: vertebral osteochondrosis, hernia disk L5-S1 with rightside lateralization, chronic radicular syndrome, compressive radiculo-neuropathy, disk protrusion L4-5. At the moment of coming patient had complaints on pain and hypestesy in lumbar part of back and in the dorsal surface of thigh rightside and in lateral surface of shin and foot, paresis of right foot and gait disorder. From anamnesis-patient was volleyball player for 10 years. In neurological status was determinate segmental loss of sensitivity and paresis of right foot. MRI showed hernia disk L5-S1 rightside localization, size 16mm and compression of radix S1. Patient refused surgery and got start regenerative treatment by "Protocol of medical care for patient with radiculopathy" №V-14.3.3.4.2.13-M54.1. After 4 hours pain reduced and to finish of 2d month paresis was reduced. For 1 year patient hasn't pain and performed gymnastic yet. MRI-control of lumbar part of spine showed hernia disk reduce (calcification) to 10 mm. was performed style life modification and patient hasn't pain and paresis for 3 years. The patient is monitored yet. Findings: Regenerative treatment has anti-inflammatory effect and promotes faster regeneration of the radix and peripheral nerve.

Conclusion & Significance

Regenerative treatment, by the protocol №V-14.3.3.4.2.13-M54.1, allows patients with radiculo-neuropathy compression like method, that providing anti-inflammatory and regenerative effect and like method of treatment in patients with contraindication to neurosurgical operations.

3. Kris Radcliff (2016) Surgical treatment for lumbar disc herniation: Open discectomy (indications, technique, outcomes, and complications). Spine surgery 28: 14-19.
4. A Blamoutier (2013) Surgical discectomy for lumbar disc herniation: Surgical techniques. Orthopaedics & Traumatology: Surgery & Research 99: 187-196.
5. Kim R, Kim RH, Kim CH (2015) The Incidence and Risk Factors for Lumbar or Sciatic Scoliosis in Lumbar Disc Herniation and the Outcomes after Percutaneous Endoscopic Discectomy. Pain Physician 18: 555-564.



Image

References

1. Corey JM (2006) Genetic disorders producing compressive radiculopathy. Semin Neurol 26: 515-522.
2. Andrew W Tarulli, Elizabeth M Raynor (2007) Lumbosacral Radiculopathy. Elsevier 25: 387-405.

Copyright: ©2017 Victoria Palinska and Palinskiy I. This is an open-access article distributed under the terms of the Creative Commons Attribution License, which permits unrestricted use, distribution, and reproduction in any medium, provided the original author and source are credited.