

Surgical Management of Lung Hydatidosis. A Monocentric Experience: At Habib Bourguiba University Hospital, Sfax-Tunisia

Kleriene Souza^{1*}, Zied Chaari² and Imed Frikha³

¹Medicine student of 4th in Federal University of Mato Grosso, Brazil

²Medicine Doctor and thoracic surgeon - Department of thoracic and cardiovascular surgery - Habib Bourguiba University Hospital, Sfax - Tunisia

³PhD in Thoracic and Cardiovascular Surgery - Department of thoracic and cardiovascular surgery - Habib Bourguiba University Hospital, Sfax - Tunisia

*Corresponding author

Kleriene Souza, Medicine student of 4th in Federal University of Mato Grosso, Brazil; E-Mail: klerivilela@yahoo.com.br

Submitted: 15 Feb 2019; Accepted: 22 Feb 2019; Published: 05 Mar 2019

Abstract

Introduction: Hydatidosis is a parasitic disease caused by the larval form of the *Taenia Echinococcus granulosus* in human which is considered as the accidental intermediate host. Hydatidosis is widely seen in the Mediterranean region, South America, Australia and New Zealand. The liver is the most common location followed by the lung in adults.

Material and methods: We report a monocentric experience of the surgical management of lung hydatidosis in a total period of 6 years from January 2012 to December 2017 in the Department of Thoracic and Cardiovascular surgery in the University hospital Habib Bourguiba in Sfax, Tunisia.

Results: A total of 80 patients had surgery for lung hydatidosis with a mean age of 42,5 years +/-15 years (7-78) and a SEX RATIO = 1,16. In 67 cases (83, 75%) pulmonary hydatid cysts was unique and unilateral, and the cyst was bilateral in 3 cases (5%). The cyst was multiple in 3 cases (3, 25%). The mean location was the right lung (46.7%). Cystectomy was performed in all patients. Surgery was completed by closure of bronchial fistula in 52 cases (65%). Anatomical resection (lobectomy) was necessary only in 2 cases (2, 5%). The evolution was simple in 70 cases (87, 5%) and complicated in 10 cases with a total morbidity rate of 12, 5%. The main complications were: fever, pneumonia, hemothorax, empyema and atelectasis. The peri operative mortality was about 2, 5%.

Conclusion: Conservative surgical procedure (cystectomy) is the treatment of choice of lung hydatidosis specially the uncomplicated ones. This simple procedure is safe, reliable and successful. However anatomical resections should only be carried out in selected patients with specific indications.

Keywords: Lung Hydatidosis, Thoracic Surgery, Parasite Disease

Introduction

Hydatidosis is a parasitic disease caused by the development of the larval form of the parasite *Echinococcus Granulosus* in humans who is an accidental intermediate host. That disease is widely seen endemically in the Mediterranean region, South America, Australia and New Zealand [1]. In humans, the accidental hosts of the parasite, the most common site of localization is the liver, followed by the lungs [2]. The treatment of hydatidosis is essentially surgical. Complications rate (morbidity) and death rate (mortality) are variable from a study to another. In fact, in big series, the mortality rate is about 1% and the morbidity rate varies from 3 to 10% [3, 4]. Thus, the purpose of this study is to look at the features of clinical presentation, management of lung hydatidosis and postoperative complications.

Materials and methods

We report our experience of lung hydatidosis surgery through a retrospective study in a total period of 6 years from January 2012 to December 2017 in the department of thoracic and cardiovascular surgery in the university hospital Habib Bourguiba in Sfax, Tunisia. The inclusion criteria were the presence of lung hydatidosis confirmed by pathological exam. We included also all lung hydatidosis with extension to the mediastinum, the pleura or the diaphragm. After surgery, all patients were supervised in our consultation. Any recurrence, secondary complication or the occurrence of another hydatid diseases were reported.

Results

Eighty patients were included in our study with a mean age of 42,5 years +/- 15 years (7 – 78 years) with a sex ratio equal to 1,16. The repartition of sex according age scales is presented in table 1.

Table 1: Age and sex wise distribution of cases (n=80)

Age group (years)	Female	Male
0-10 (n=3)	1	2
11-20 (n=13)	2	11
21-30 (n=22)	12	10
31-40(n=11)	7	4
41-50 (n=9)	6	3
51+ (n=22)	11	11
Total	39 (53.75)	41 (46.25)

In 67 cases the hydatid cyst was unique and unilateral. The cyst was bilateral in 4 cases and multiple in 3 cases (Figure 1)

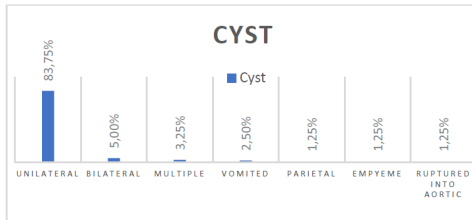


Figure 1: Lung hydatid characteristics

The main location was the right lung (46.7%). Otherwise, the cyst has an extension to the pleura in 3 cases (3, 75%), and to the mediastinum in 1 case (Figure 2).

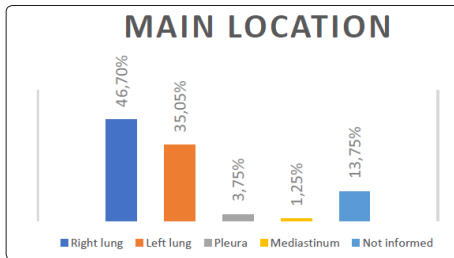


Figure 2: the main locations of the cyst.

Chest pain and caught were the mean symptoms for discovery of the disease, reported in respectively 83 and 70% of cases. Hemoptysis was reported in 25% of cases, and the patients reported the notion of vomit (expectoration of saline liquid associated or not with white membranes after an effort of caught) in 2.5% of cases. The discovery of lung hydatidosis was fortuitous on chest X-ray radiography in 4 patients (5% of cases). All the patients had X-ray radiography (Image 2) explorations with CT scan that confirmed the presence of a liquid density mass, located in the lung.

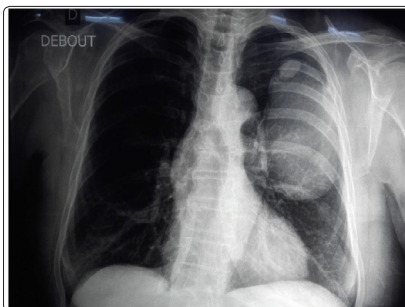


Image 1: Chest X-Ray radiography showing two adjacent non-complicated hydatid cysts of the left lung. The upper cyst (White

arrow) and the lower cyst (red arrow)

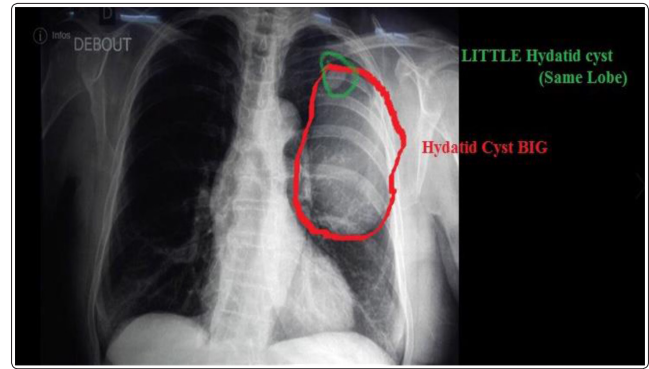


Image 2: Chest X-Ray radiography showing two adjacent non-complicated hydatid cysts of the left lung. The upper cyst in green circle and the lower cyst in red circle

The cyst was complicated (ruptured into the pleura, or into the bronchus) in 11, 25% of cases (Image 3).

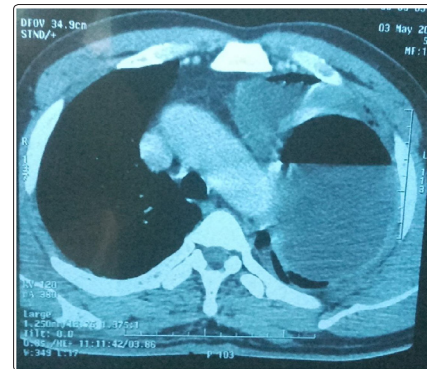


Image 3: Lower left lobe hydatid cyst ruptured into the pleural with air-liquid level

Serology with ELISA technique was performed for only 36% of patients and was positive in 75% of cases. All the patients were operated essentially through a posterolateral thoracotomy (92.5% of cases). Mini invasive approach (video-assisted thoracic surgery or VATS) was adopted to treat peripheral hydatid cysts with a size inferior to 4cm. The procedure consisted on the protection of the pleural cavity with gauzes imbibed with saline solution. Then the cyst was punctiioned and the content was sterilized after injection of saline solution. After sterilizing, the cyst was opened with evacuation of the hydatid fluid, and extraction of the hydatid membrane (Image 4).

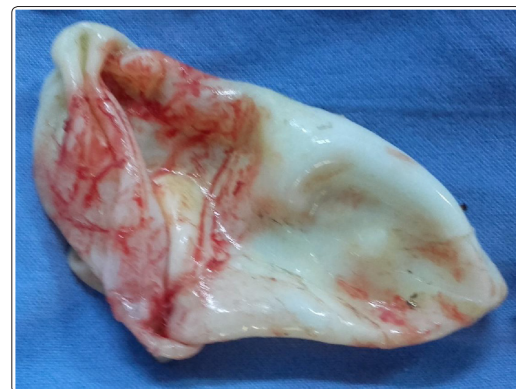

Image 4: Hydatid membrane for a giant 15-cm hydatid cyst

The closure of the residual lung cavity was performed in 85% of cases after closure of bronchial fistula in 52 cases (65%). Anatomical resection (lobectomy, segmentectomy) was necessary in only 2 cases (2, 5%). After surgery, the post-operative course was uneventful in 70 cases (87, 5%). Complications were recorded in 10 cases with a total morbidity rate of 12, 5%. The main complications were: fever, pneumonia, hemothorax, empyema and atelectasis in respectively 1, 25%, 3, 75%, 1, 25% and 1, 25% of cases. Two patients died after surgery with a mortality rate of 2, 5%. Death occurred after septic choc for the two patients secondary to infected hydatid cyst associated with empyema or vomit. After surgery, the patients were reviewed in our consultation with a mean surveilling time of 3.2 years +/- 0.54 year (2 months – 5 years). We recorded only one case of recurrence in a patient how already multiple, bilateral and ruptured hydatid cyst into the pleura.

Discussion

Hydatidosis is a zoonosis due to development in the man of the larval form of dog taenia: *Taenia Echinococcus Granulosus*. The usual intermediate host is the sheep. The penetration of the egg is digestive, then by passage through the portal venous system, explaining preferential hepatic localization [5]. Nevertheless, in 10 to 30% of cases, the parasite can pass through hepatic veins and then, in the right heart leading to single or multiple pulmonary involvement in the form of intra-parenchymal fluid cysts. The main location of the cysts is the right lower lobe in two-thirds of cases [6]. In our study, the right side was involved in 46.7% of cases. Simple hydatid cysts may remain asymptomatic for a long time to the elasticity of the lung. As they enlarge, they can be symptomatic with slight chest pain, nonproductive cough and dyspnea resulting from compression of adjacent organs (trachea, oesophagus, lung, mediastinum, heart or great vessels). Thus, hydatid cysts of the lung grow regularly until the occurrence of local complications (like compression of adjacent organs, bronchus or tracheal fistula, or infection) or general complications like intrapleural or intra pericardial rupture with dissemination and possibility of anaphylactic shock [7]. The typical clinical form is incidental findings on radiological exam showing a well surrounded intra parenchymal fluid image associated or not with cough or chest pain. These signs were reported in 4 patients in our series (5% of cases). These signs are not very specific in young adults, but there are very evocative especially in endemic areas or countries like Tunisia. The diagnosis of hydatidosis can be confirmed by serology, but there are 45% false negatives [8].

In our study, ELISA test was negative in 25% of the patients, which can be considered as non specific test for the positive diagnosis of lung hydatidosis. The differential diagnosis must evoke other cystic intraparenchymal fluid masses, including bronchogenic cysts, enterogenic cysts, and intra scissural pleurisy. Without adequate treatment, the habitual evolution is towards complications. Medical treatment based on Albendazole is often insufficient and doesn't lead to parasite eradication, so, the only therapeutic possibility is still surgical excision [9]. The purpose of the treatment is the excision of the cyst, the evacuation of its content in order to protect the patient from complications, and trying to preserve the functional respiratory capital of the lung. Surgery is based on whether the excision of the cyst by a conservative (Cystectomy with or without closure of residual cavity) or non-conservative parenchyma technique (pulmonary atypical resection or systematized resection such as segmentectomy, lobectomy, or even pneumonectomy). Surgical treatment is the rule in hydatid cysts of the lung, whether they are

symptomatic or not [10].

The choice of technique depends on the number, size and topography of the lesions. Conservative parenchyma techniques are always preferred. The morbidity of this surgery is 3 to 10% [4]. Ruptured cysts have a higher rate of postoperative complications. Complications related to aerostasis are in the foreground and hemorrhagic complications to the second. Recurrences are rare, especially when they occur late; it is most often considered as a re-infestation. In the largest series, the mortality of hydatid cysts surgery is 1% [3]. In our study, the mortality rate was 2.5% and morbidity rate was 12.5% which is concordant with the rates in the literature. But a bigger study including much more patients is needed to study these rates with more precision. In fact, surgery of lung hydatidosis was started from 1987 in thoracic Surgery Department in Habib Bourguiba University Hospital, and a current study is performed including all the patients who had undergone surgery for lung hydatidosis. We think that the results will reflect the real morbi-mortality rates of this surgery.

Conclusion

Conservative surgical procedure (cystectomy) is the treatment of choice of lung hydatidosis specially the uncomplicated ones. This simple procedure is safe, reliable and successful. However anatomical resections should only be carried out in selected patients with specific indications (such as the destruction of the lobe becoming non-functional). The various surgical modalities have fairly comparable results. Nevertheless, the savings of lung parenchyma in young adults especially in endemic countries seems legitimate. The protection of the operative field with hypertonic saline solution and treatment of the residual cavity remain controversial and no factual argument can prove the benefit. Particular attention should be paid to risk of bronchopleural fistula, the main complication of this surgery. A great attention should be carried-out to close the entire bronchogenic fistula after removing the hydatid membrane to avoid these complications.

References

1. S Maalej DB, Hantous S, Fenniche S, Ammar A, Hammami S, et al. (2003) Hydatid costovertebral: value of MRI. Review of Respiratory Diseases [in French]. *Rev Mal Respir* 20: 614-617.
2. Ousehal A, Adil A, El Azhari A, Kadiri R (1995) Spinal cord compression disclosing rib hydatidosis [in French]. *J Radiol* 76: 1093-1095.
3. Salih OK, Topcuoglu MS, Celik SK, Ulus T, Tokcan A (1998) Surgical treatment of hydatid cysts of the lung: analysis of 405 patients. *Can J Surg* 41:131-135.
4. Kavukcu S, Kilic D, Tokat AO, Kutlay H, Cangir AK, et al. (2006) Parenchyma-preserving surgery in the management of pulmonary hydatid cysts. *J Invest Surg* 19: 61-68.
5. Klotz F, Nicolas X, Debonne JM, Garcia JF, Andreu JM (2000) Kystes hydatiques du foie. *Encycl Méd Chir (Elsevier SAS, Paris), Hépatologie* 7-023-A-10.
6. Lewall DB (1998) Hydatid disease: biology, pathology, imaging and classification. *Clin Radiol* 53: 663-674.
7. Gomez de la Torre R, Lopez Moran A, Verano Garcia J, Fernandez Hidalgo JM (2003) Anaphylaxis as first manifestation of unknown hydatid cyst. *Med Interna* 20:156-157.
8. Biava MF, Dao A, Fortier B (2001) Laboratory diagnosis of cystic hydatid disease. *World J Surg* 25:10-14.
9. Riquet M, Souliamas R (2000) Kyste hydatique pulmonaire.

Indications thérapeutiques. Encycl Méd Chir (Elsevier SAS, Paris), Pneumologie 6-003-M-10.

10. Kuzucu A, Soysal O, Ozegel M, Yologlu S (2004) Complicated

hydatid cysts of the lung: clinical and therapeutic issues. Ann Thorac Surg 77: 1200-1204.

Copyright: ©2019 Kleriene Souza, et al. This is an open-access article distributed under the terms of the Creative Commons Attribution License, which permits unrestricted use, distribution, and reproduction in any medium, provided the original author and source are credited.