

# Recurrent cervical hemorrhages and thromboses associated to pulmonary thrombembolism in a hereditary thrombophilia with heterozygous mutants of MTHFR and PAI-1. Case Report and Pathophysiology Hypotheses

Manuela Cristina Russu<sup>\*1</sup>, A Bogza<sup>1</sup>, Codruta Mirciulescu<sup>2</sup> and Ilinca Gussi<sup>1</sup>

<sup>1</sup>“Dr I Cantacuzino” Clinical Hospital, Clinic of Obstetrics and Gynecology, “Carol Davila” University of Medicine and Pharmacy, Bucharest Romania

<sup>2</sup>Anesthesiology Intensive Care Unit,

## \*Corresponding author

Manuela Cristina Russu, Professor of obstetrics and gynecology, “Carol Davila” University of Medicine and Pharmacy, Bucharest Romania

Submitted: 21 Oct 2020; Accepted: 29 Oct 2020; Published: 03 Nov 2020

## Abstract

A 30 years Caucasian nullipara, 1 blighted ovum, former Yasmin user (1 year), without antiphospholipid antibodies, prophylactic cervical cerclage at 19 weeks pregnancy, is readmitted in emergency at 21 weeks gestation for heavy pelvic pains, and abundant vaginal red blood loss, with cerclage suppression. Under tocolysis and vaginal progesterone, she presents 3 new episodes of intense pains and red, pulsatile blood loss from different cervical areas at 24- 36 hours after admittance, with mechanical hemostasis by nylon sutures at cervico- vaginal junction. The 4th episode is followed by severe anemia (Hb= 6.03mg/dL, Ht= 18.32%), haemodynamic instability, coagulation disorders- hematomas, generalized petechia, and at 24 hours after last vaginal sutures she claims thoracic pains, dyspnea, cyanosis. There are not registered fetal distress, placental abnormalities, cervical shortness below 2.5 cm (when cerclage), and maternal heart abnormalities at repeated ultrasound examinations. No thoracic computer tomography because maternal refuse. After a cardiologist consultation it is appreciated a mild/moderate pulmonary thrombembolism, without deep legs venous thrombosis, and it is started continuous intravenous anticoagulant therapy – heparine 25,000UI/day x 6 days, then fraxiparine in increased dosages continued to term, and 6 weeks postpartum. The laboratory test confirms intravascular disseminated coagulation with secondary fibrinolysis, and positivity for heterozygous mutants of MTHFR (methylene tetrahydrofolate reductase deficiency C677T and A1298C), and PAI (plasminogen activator inhibitor)-1 (4G). Cesarean delivery is performed at 37 weeks for fetal distress at labor onset, with extraction of a girl 3340g, Apgar=7/8, premature senescent placenta, thin umbilical cord. No maternal and neonate postpartum complications.

**Keywords:** Acute Recurrent Cervico-Vaginal Arteries Hemorrhage/Thrombosis, Pulmonary Embolism, MTHFR, PAI-1 Thrombophilias, Pregnancy

## Introduction

There are growing evidences of an increased rate of thrombophilia cases, and the medical literature is analyzing the parallel increase of venous thrombosis. The case report of cervical arteries hemorrhages associated to recurrent cervical arteries thrombosis, and pulmonary thrombembolism at the beginning of the second pregnancy trimester opens the discussions of this article, regarding several clinical, biological, biochemical and hematological mechanisms, which are challenging our knowledge from the famous Virchow's triad. The arterial thrombosis is depicted to heart coronary arteries, brain, other abdominal organs, and legs, and it is usually associated to atherosclerosis. Some findings show that patients with venous thromboembolism are at higher risk of arterial events and vice versa, so there is the question if the venous and

arterial thrombosis are different sides of the same coin/disease, being described differences, and common risk factors and therapeutic options [1-3].

## Case Report

NA- a Caucasian nullipara 30 yrs old, with a pregnancy of 21 weeks gestation is readmitted in emergency in “Dr I Cantacuzino” Clinic of Obstetrics and Gynecology for heavy pelvic pains, and abundant vaginal red blood loss. Her family history has nothing special, and her medical history reveals no bleeding episodes demanding intervention from birth, the use of Yasmin for one year –without any adverse event, 1 blighted ova, prophylactic cerclage at 19 weeks for short cervix, when there were recorded the negativity of antiphospholipid antibodies, TORCH syndrome, and cer-

vix uteri culture. The patient was treated with aspirin 75 mg/day, progesterone, folic acid, and vitamins. The patient was hemodynamically stable at readmission, the sonography showed an alive fetus, no placental hematoma, normal Doppler of uterine arteries; the cerclage was suppressed with the believe to be the reason of the cervical bleeding. The patient was treated with saline perfusions, antispastic medication as drotaverine, scopolamine, and vaginal progesterone 200mg/day. The patient presents 3 new episodes of intense pelvic pains, similar to those pains from readmission, without uterine contractions on tocography, and active, red blood loss from different cervical areas (at the levels of cervico- vaginal insertions, or at the insertion of utero- sacral ligaments), at 24- 36- 48 hours after admittance. It was performed mechanical hemostasis with nylon sutures at cervico- vaginal junctions at the places of acute blood loss. The cerclage was done with a subepithelial nylon suture, exteriorized at 12, 3, 6 and 9 on a watch hour.

The 4th episode is followed by hemodynamic instability, coagulation disorders- hematomas, generalized petechia, associated to severe anemia (Hb = 6.03 mg/dL, Ht = 18.32%), and at 36 hours after last vaginal sutures, in the middle of the night, the patient claims thoracic pains, dyspnea, cyanosis, with no pelvic pain, or vaginal bleeding. The electrocardiogram is normal. The ultrasound examinations showed only the cervical shortness below 2.5 cm (the reason for cerclage), left pleural effusion, and no maternal heart abnormalities, or fetal distress, or placental abnormalities, no abnormalities of legs' deep veins. It was not done thoracic computer tomography because maternal refuse. It is appreciated a mild/moderate pulmonary thrombembolism, without deep legs venous thrombosis after the cardiologist consultation, and it is started continuous intravenous anticoagulant therapy – heparin 25,000 UI/day for 6 days, then fraxiparine in increased dosage continued to term, and during the first 6 postpartum weeks. The laboratory tests confirm intravascular disseminated coagulation with secondary fibrinolysis, and positivity for heterozygous mutants of MTHFR (methylene tetrahydrofolate reductase deficiency- C677T and A1298C), and PAI (plasminogen activator inhibitor)-1 (4G). The delivery is performed by cesarean section at 37 weeks gestation for fetal distress at labor onset, with extraction of a girl 3340g, Apgar Score of 7/8, being recorded a normal gross aspect of placenta, and a thin umbilical cord. The placental microscopy reveals large areas of hyalinization, microcalcifications, venous stasis, and thickened vessels' walls.

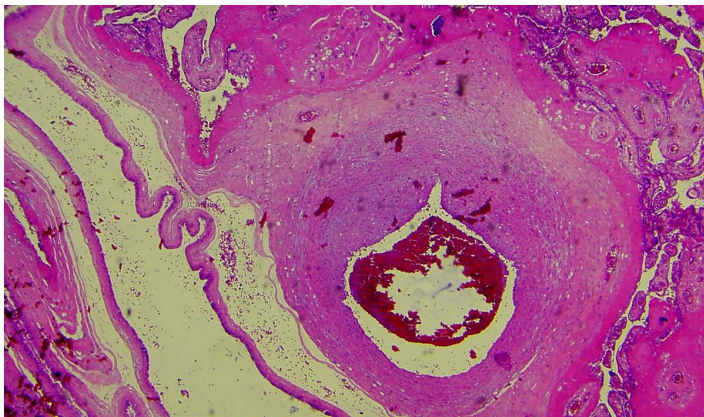


Figure 1. Placenta microscopy. HE x40.

The baby is breastfed six months, with a normal evolution. One records a normal postpartum evolution regarding the mother, no general or genital complication after the first period in the postnatal period, with normal appearance of cervix uteri, up to the moment of this written paper.

## Discussion

The reported case is at the knowledge of the authors, the first case of thrombosis located to the level of cervix uteri arteries, and the manifestation can be considered a new clinical complication of inherited, acquired, or complex/mixed thrombophilias, besides recurrent miscarriages, pre-eclampsia, intrauterine growth restriction, stillbirth, placental abruption, as well as legs' deep vein thrombosis [4]. The venous thromboembolism (VTE) in pregnant women is the second commonest cause of maternal deaths in Caucasian and Asian populations - 0.12 per 10,000 live births and stillbirths is the rate of maternal deaths from thromboembolism [5]. The MEGA study showed that the risk of VTE is higher in the third trimester (OR 3.3; 95% CI 2.2–5.0), and during puerperium (OR 11.0; 95% CI 8.1–15.1), being highest in the 2 days before and the day after delivery (OR 77.6; 95% CI 52.4–114.8) [6, 7]. The arterial disease- with lower frequency than venous thrombosis is discussed mainly for the coronary and brain arteries, through the rupture of atherosclerotic plaques, but after the Virchow's triad, old of 150 years, Dvorak M, Vlasin M, Dvorakova M, Staffa R et al (2010)– from Prague (Czech Republic) are discussing the arterial thrombosis of major or minor vessels of abdominal viscera, besides legs, coronary and brain arteries, and Benett CP, Silverman HS, Gill SP, Lip YHG (2009) from Birmingham (UK) are discussing the peripheral arterial disease with the pathophysiological processes involved in its development, progression and complications: atherothrombosis and thromboembolism [8-10]. Quick onset and severe manifestation is typical for arterial occlusion, while venous thrombosis is known for its slow start, discrete clinical symptomatology and more than one site of stenosis [11].

The Virchow's triad abnormalities are focused on blood flow, vessel wall, and blood constituents, associated with thrombogenesis. It is now accepted that venous thrombi are mainly constituted by fibrin and red blood cells, and less by platelets, which are essential for primary haemostasis, repair of damaged endothelium, and play a pivotal role in the development of atherosclerosis, which was considered as a basis pathology for arterial thrombosis [12]. Inflammation, lipids and the immune system, through a complex interplay, are also important determinants of arterial and, albeit to a lesser extent, of venous thrombosis.

The reported case rises many questions regarding the management for positive and differential diagnosis, and therapy. At patient's first visit for pregnancy registration it was a suspicion of acquired thrombophilia because the patient used many years ago a pill from the third generation of combined oral contraceptives, with high risk of venous thrombosis, and the tests for antiphospholipid antibodies were negative [13-15]. Regarding the hereditary/inherited thrombophilia which was confirmed after the reported complications, one must reconsider that the changes on coagulation during pregnancy are different from those induced by contraceptive pills, specially from the third generation.

The studies from Hopkins Lupus Center- USA on the comparison of arterial thrombosis and pregnancy loss from hereditary thrombophilias, antiphospholipid syndromes (APS), and APS with systemic lupus erythematosus (SLE) concluded that risk factors differ for venous and arterial thrombosis [15]. Hypertension increases the prevalence of arterial thrombosis in APS, and venous thrombosis are associated to hereditary thrombophilias, and elevated triglycerides; on another hand the frequency of thrombosis and pregnancy loss is greater in APS associated with SLE than in primary APS. The reported case presented normal values of arterial pressure during all pregnancy duration.

The first episode of abundant cervical bleeding is registered at 7 days after the cerclage. The cervical bleeding episodes were recorded at different areas from the points of the cerclage, and the blood loss was with pulsatile aspect, similar to maternal pulse rate. When the patient claimed intense pelvic pains the tocography did not recorded uterine contractions. The pains claimed by the patient are characteristic for arterial thrombosis. Regarding the bleeding, it was initially difficult to be sure if it was a delayed arterial hemorrhage after cerclage, an arterial thrombosis from inherited thrombophilia, or from a Scott syndrome or Platelet factor X receptor deficiency, from the Quebec platelet disorder, or about the Glanzmann Thrombasthenia, and Bernard Soulier Syndrome (giant platelet syndrome). In the Scott Syndrome is a defective platelet phospholipid membrane support (a rare disease, only 10 cases being described since 1973, when it was first discovered). When hemostatic screening labs are normal, it is recommend to analyze the platelet factor 3 availability, and Annexin V for platelet procoagulant activity, but the definitive diagnosis is done by the presence of a mutation within the ABC transporter gene (ABCA1), which is a confirmation of the previous statement about the inherited characteristic of this hemorrhagic disorder [16].

**Table 1.** Test Results Indicative of the Scott Syndrome

Platelet factor 3 availability assay	Annexin V binding assay	Mutational analysis
Prolonged modified Russell's Viper Venom time	Abnormal binding	Identification of a mutation within the ABC transporter (ABCA1) gene

It is considered that aspirin use within the previous 7-8 days may lead to Scott Syndrome false- positive tests, but for us it was not possible to achieve the tests, considering the syndrome diagnosis.

The hereditary/inherited and acquired disorders of platelets must be analyzed, The Quebec platelet disorder is a rare autosomal dominant bleeding disorder induced by a mutation of urokinase-plasminogen activator (u-PA), with large amounts of the enzyme in platelets granule, characterized by moderate to severe bleeding after surgery or obstetric intervention, trauma, with frequent ecchymoses, muco-cutaneous bleeding, muscle, and joint bleeds [17]. The Glanzmann thrombasthenia (GT) is a rare autosomal recessive bleeding syndrome affecting the megakaryocyte lineage, and characterized by lack of platelet aggregation. The mutation in

the genes that encode the glycoproteins GPIIb or GPIIIa is inducing a platelets dysfunction, as the disorder was named by Eduard Glanzmann (1918), who described the novel platelet abnormality with defective clot retraction and abnormal appearance on stained blood film [18, 19]. GT is the only disease in which platelet aggregation is defective to all agonists, while absent clot retraction is another frequent characteristic. Normal ristocetin-induced platelet agglutination, and normal platelet size clearly rule out the Bernard-Soulier syndrome (BSS). BSS was first described in 1948 (by Jean Bernard and Jean-Pierre Soulier) as a congenital bleeding disorder, characterized by thrombocytopenia, and large platelets (macrothrombocytopenia, from 3 to 20 times normal size), with a qualitative platelet hereditary adhesion defect, resulting in bleeding tendency (mucocutaneous bleeding, menorrhagia, post-partum bleeding, post-trauma bleeding) [20]. The underlying biochemical defect in BSS is the absence or decreased expression of the GPIIb/IX/V complex on the surface of the platelets [21]. This complex is the receptor for von Willebrand factor (vWF), and the result of decreased expression is deficient binding of vWF to the platelet membrane at sites of vascular injury, resulting in defective platelet adhesion This disorder is characterized by ante-, intra-, or postpartum haemorrhage, which may be delayed and severe [22]. Inherited thrombocytopenias are eliminated by a normal platelet count. Normal coagulation parameters rule out clotting disorders that can also affect platelet function such as congenital afibrinogenemia, and von Willebrand disease. Acquired thrombasthenia is eliminated in the absence of a family history of the disease.

Many of these disorders are present and manifest immediately after birth, during childhood or adolescence at the menarche, fact that is not present in the Romanian case. Although venous thrombosis has been traditionally associated with stasis and hypercoagulability, arterial thrombosis is mainly associated with heightened platelet reactivity and damage to the vessel wall [2]. The endothelial damage - a part of Virchow's triad of the arterial thrombosis, is usually represented by atherosclerosis, but one may consider in the reported case the vessels trauma to be associated to hypercoagulation [23].

The cervical vessels' trauma can be considered during the cerclage, performed 7 days previously to the first bleeding episode. We may consider some biological events in the moment of bleeding, as the appearance of tissue factor (TF), blood cells and their fragments or microvesicles/microparticles (MVs/MPs), coagulation factors, in conjunction to the presence of pregnancy's characteristic trophoblastic cells, which initiate and maintain the coagulation initially in physiologic state, and exaggerated afterwards because patient's specific conditions of hypercoagulation. The hypercoagulation- a constant state of pregnancy, can be considered in the presence of MPs/MVs or in the presence of insufficiently treated hereditary thrombophilias (low doses aspirin), and in association to patient's PAI-1 heterozygous mutant presence, which was discussed to promote formation of endothelial MPs with procoagulant potential [24].

Chargaff E, West R. (1946) were the first who described the microparticles as a "precipitable factor"; MPs are present in plasma as fragments or submicron vesicles (0.1–1µm) released from

remodeling of eukaryotic cells' plasma membranes (as platelets, leukocytes, red blood cells, endothelial cells) in response to activation or apoptosis [25]. Actually it is appreciated that MPs balance between pro and anticoagulant properties ultimately determines their net effects in hemostasis and thrombosis. MPs can promote coagulation processes, in conjunction to phosphatidylserine (PS) exposure and the presence of tissue factor (TF) or thromboplastin or thrombogenic tissue factor (from the intima of blood vessels) in the MPs membrane. MPs support plasmin generation, another regulatory mechanism by which fibrin clots are degraded [26-28].

It was an original dogma that vessel wall injury induces cells activation or apoptosis, and exposure of TF within the vasculature to blood is sufficient for the occurrence of arterial thrombosis. Very old experiments [30], cited by [31], and recent studies provided that leukocytes - specially neutrophils, and in a less manner the monocytes, which are first present at the area of injury, are the main source of TF in the early phase of thrombus formation, and must interact with platelets or CD15 to transfer TF, and activate TF pathways to the place of arterial walls' endothelium injury, in order to initiate, and maintain coagulation [29-34]. Leukocytes modulate the hemostatic activity of endothelial cells and platelets, fact very well known in cardiology, in CHD [35]. The anticoagulant activity of endothelial cells is modulated by leukocyte-released antimicrobial enzymes, cytokines- as tumor necrosis factor- $\alpha$  and interleukin-1 $\beta$ , involved in stimulation of the exocytosis of endothelial Weibel-Palade bodies, inducing the release of von Willebrandt Factor (VWF) and/or P-selectin (PS). The circulating platelets bind subendothelial ligands, such as collagen and VWF that facilitate the generation of a platelet-rich thrombus.

MPs-associated PS provide a catalytic surface for the assembly of enzymatic coagulation complexes that initiate and maintain coagulation [36]. TF is the main initiator of the coagulation cascade and MP-TFs are shed into the circulation by cells (mainly platelets and to a lower extent monocytes) during activation or apoptosis. It is known MPs involvement in numerous biologic processes- inflammation, immune response, cancer metastasis, angiogenesis, in pregnancy, or after blunt trauma [37, 38].

Activated platelets release cytokines that can modulate leukocyte activation resulting in the formation of heterotypic leukocyte-platelet aggregates that serve to localize activated leukocytes to the arterial thrombus, platelet-neutrophil interactions being drivers of inflammatory and thrombotic disease, modulating each other's functions, and neutrophil/platelet crosstalk is facilitated by MPs, all these events being prone to repair the tissue injury [39, 40].

In pregnancy it is a constant process of deportation of trophoblastic cells into maternal circulation, as it is the fact that extrusion of trophoblast may lead to the formation of MPs, which are shown to be elevated in normal pregnancy [41], indicating a pregnancy ongoing process of cell activation, more important when thrombophilias are associated, being discussed their presence in cases without or with thrombosis [36, 42-44]. The presence of endothelial microparticles in the interval between pregnancies may be a chronic state of blood vessels activation which only becomes apparent in pregnancy, when appears an accident as thrombosis,

when MPs interact with coagulation or with fibrinolytic factors [41, 45, 46, 26]. Other discussion on MPs is their increased percentage in the pathophysiology of pulmonary embolism, and we can suppose that in the Romanian case the presence of MPs was increased as pregnancy progressed, and after repeated sutures for cervico- vaginal hemostasis. These data, and our hypothesis are similar to a study showing that MPs and TF are not increased in cases with recurrent vein thrombosis [47-49].

Tissue factor is the main initiator of the coagulation cascade and MP-TFs are shed into the circulation by cells (mainly platelets and to a lower extent monocytes) during activation or apoptosis [50]. The influence of MP-TF and MP-TF activity on the occurrence of thromboses has mainly been studied in animal models- in rat, mouse, and rabbit [51-53].

One considers pregnancy as a biological state with hypercoagulation, which is associated with increased concentrations of most procoagulant factors, decreased concentrations of some of the natural anticoagulants and reduced fibrinolytic activity.

Although adverse pregnancy outcomes are more common in women with thrombophilia, in the majority of European and North American countries the current evidence does not support routine thrombophilia screening of all pregnant women. The UK analysis of thrombophilias at 10 weeks after birth looked for mutations of factor V Leiden, MTHFR- C677T, and G20210A prothrombin gene, and deficiencies of protein C, protein S, and antithrombin III, and the presence of lupus anticoagulant, and anticardiolipin antibodies [54]. The study discovered the presence of these abnormalities in cases with severe obstetrical pathologies (PE/eclampsia, abruption placentae, IUFG, stillbirth), and in pregnancies with normal evolution. In some European countries, like the Czech Republic there are discussions on the criteria for thrombophilias diagnosis. Selective thrombophilia screening (genetic tests) may be justified in pregnancy in certain groups of pregnant women, particularly those with a history of thromboembolism, or previous pregnancy complications in the first or last trimesters; in UK routine screening for inherited or acquired thrombophilias is not routinely recommend in the absence of venous thromboembolism [54-56]. In these conditions, in the Romanian case only the genetic tests were done for the proteins involved in the cascade coagulation disorders. The most common inherited thrombophilias are deficiencies of antithrombin III, protein C, and protein S, acquired protein C resistance, genetic mutation encoding for factor V Leiden, prothrombin gene, and inherited hyperhomocysteinemia, and antiphospholipid syndrome, which were analyzed in the mentioned above British postpartum study. The inherited deficiency of one of the inhibitors of coagulation mentioned above leads to a critical reduction of the natural anticoagulant system, and enhances thrombin generation, increasing susceptibility to VTE, and have little or no effect on arterial thrombosis risks, and according to the medical literature, factor V Leiden, as well as hyperhomocysteinemia affect both arterial and venous thrombosis in the same manner [57-60].

In the Romanian case it is discovered the heterozygotism of MTHFR (C677T and A1298C), and of PAI-1 (4G); the patient did not have preconceptional treatment with folic acid, and started it lat-

er at 14th week gestation, and the connection of heterozygotism of MTHFR (C677T and A1298C) is proved to be associated to mild/moderate hyperhomocysteinemia, pre-eclampsia/eclampsia, IUFGR and future atherosclerosis [61, 62]. A Greek study demonstrated also the hypertensive risks of MTHFR mutations during pregnancy, and that MTHFR mutations do not interfere with pregnancy loss, as it happens when are present factor V Leiden and prothrombin G 20210A mutations [63]. The placenta presented only microscopic changes, hyalinization, venous stasis and thick vessels' walls, with no intravascular thrombus.

Heparin and its depolymerizing products – low molecular weight heparins (LMWH's) represent the treatment for both types of thrombosis: arterial and venous for the American College of Chest Physicians, 2008 [6, 64, 65]. These drugs do not affect the patient's general coagulation profile, being involved in different pathways of the coagulation cascade with anticoagulant, antithrombotic, profibrinolytic, anti-aggregative, as well as anti-inflammatory effects [9]. The Romanian authors consider that after standard heparin therapy for the acute pulmonary thromboembolism, long duration of LMWHs was the correct option for mother and fetus protection- the cervical bleeding did not repeat, and the pulmonary embolism was the last maternal complication. The mother did not developed hypertension/pre-eclampsia, fetal intrauterine growth restriction which are usually associated to heterozygous mutants of MTHFR and PAI-1, and we confirm previous statements. The fetal growth was normal, according to parents constitution and European curves of babies growth, only some small changes of placental vessels may be considered as pathological, but noncharacteristic, as there are in other inherited thrombophilias.

Biological studies have demonstrated that heparin has other beneficial effects on the placenta in addition to the anticoagulant properties mediated through its interaction with antithrombin [56]. These include increased tissue factor pathway inhibitor, angiogenesis on the antiphospholipid antibody-inhibited human endometrial endothelial cell, and reduced trophoblast apoptosis, complement activation with modulation of the immune system, and platelet aggregation [66, 67]. In the Romanian authors' opinion the supplementation of vaginal progesterone from the 16th to 37th weeks gestation had also crucial effects on decidua, placenta, cervix uteri and uterine normal progression, and fetal protection.

There are discussions on the risks of vaginal and cervical lesions, after so many procedures done for cervical hemostasis, but we consider that the constant anastomosis of the three pedicles of the arterial system - superior, median, inferior of uterus, cervix and vagina (lower uterine vascular supply- as superior, cervical artery as middle supply, and vaginal arteries as lower supply), which are interconnected along the isthmic-vaginal borders or in the thickness of the cervico-vaginal junction (intramural anastomotic network) ensured a normal healing of the area, and can explain the normal evolution of the case [68]. In our opinion more important is the risk of cervical cancer associated to women with C677T and A1298C genotypes of MTHFR, and we will recommend HPV high risk testing and Pap smear in patient regular monitoring [69].

## Conclusion

Cervix uteri can suffer from thrombosis in inherited thrombophil-

ias. At present routine screening for acquired or inherited thrombophilias is not routinely recommended in the absence of venous thromboembolism history, for women with embryo loss. Cervix uteri arteries thrombosis must be considered as a manifestation of hereditary thrombophilia due to heterozygous mutants of MTHFR, a condition inducing hyperhomocysteinemia, and atherosclerosis risks. LMWHs is a diagnosis and therapeutic option, and in increasing doses ensured a good management for mother and fetus. Cervix uteri recurrent thromboses were a guardian for pregnancy evolution, for fetus normal growth, with late placental vessels jeopardize, only microscopically proved

## References

1. Franchini M, Mannucci PM (2008) Venous and arterial thrombosis: different sides of the same coin? *Eur J Inter Med* 19: 476-481.
2. Martinelli I, Bucciarelli P, Mannucci PM (2010) Thrombotic risk factors: basic pathophysiology. *Crit Care Med* 38: S3-S9.
3. Lowe DOG (2008) Common risk factors for both arterial and venous thrombosis. *BJH* 140: 488-495.
4. Rodger MA, Paidas M, McLintock C, Middelpoort S, Greer AI, et al. (2008) Inherited thrombophilia and pregnancy complications revisited. *Obstet Gynecol* 112: 320-324.
5. Tan JY (2002) Thrombophilia in pregnancy. *Ann Acad Med Singapore* 31: 328-334.
6. Pomp ER, Lenselink AM, Rosendaal FR, Doggen CJ (2008) Pregnancy, the postpartum period and prothrombotic defects: risk of venous thrombosis in the MEGA study. *J Thromb Haemost* 6: 632-637.
7. Salonen Ros H, Lichtenstein P, Bellocco R, Petersson G, Cnattingius S (2002) Pulmonary embolism and stroke in relation to pregnancy: how can high-risk women be identified? *Am J Obstet Gynecol* 186: 198-203.
8. Baba N, Bashe WJ Jr, Keller MD, Geer JC (1975) Anthony JR-Pathology of atherosclerotic heart disease in sudden death. I. Organizing thrombosis and acute coronary vessel lesions. *Circulation* 52: III 53-59.
9. Dvorak M, Vlasin M, Dvorakova M, Rauser P, Staffa R, et al. (2010) Heparin and its derivatives in the treatment of arterial thrombosis: a review. *Veterinari Medicina* 55: 523-546.
10. Bennett CP, Silverman HS, Gill SP, Lip YHG (2009) Peripheral arterial disease and Virchow's triad. *Thrombosis & Haemostasis* 101: 1032-1040.
11. Schumann R, Rieger J, Ludwig M (2007) Acute peripheral arterial occlusive disease. *Medizinische Klinik* 102: 457-471.
12. Previtali E, Bucciarelli P, Passamonti MS, Martinelli I (2011) Risk factors for venous and arterial thrombosis. *Blood Transfus* 9: 120-138.
13. Winkler UH-Hemostatic (2000) effects of third- and second-generation oral contraceptives: absence of a causal mechanism for a difference in risk of venous thromboembolism. *Contraception* 62: 11S-20S.
14. Kemmeren JM, Algra A, Grobbee DE (2001) Third generation oral contraceptives and risk of venous thrombosis: meta-analysis. *BMJ* 323: 131-134.
15. Danowski A, de Azevedo NM, de Souza Papi JA, Petri M (2009) Determinants of risk for venous and arterial thrombosis in primary antiphospholipid syndrome and in antiphospholipid syndrome with systemic lupus erythematosus. *J Rheu-*

- matol 36: 1195-1199.
16. Toti F, Satta N, Fressinaud E, Meyer D, Freyssinet JM (1996) Scott syndrome, characterized by impaired transmembrane migration of procoagulant phosphatidylserine and hemorrhagic complications, is an inherited disorder. *Blood* 87: 1409-1415.
  17. Diamandis M, Veljkovic DK, Maurer-Spurej E, Rivard GE, Hayward CPM (2008) Quebec platelet disorder: features, pathogenesis and treatment. *Blood Coagulation and Fibrinolysis* 19: 109-119.
  18. Glanzmann E (1918) Hereditaire Hamorrhagische thrombasthenic. Ein Beitrag Zur Pathologie der Blutplattchen. *Jahrbuch Kinderheilkunde* 88: 1-42.
  19. Sebastiano Ch, Bromberg M, Breen KT, Hurford TM (2010) Glanzmann's thrombasthenia: report of a case and review of the literature. *Int J Clin Exp Pathol* 3: 443-447.
  20. Bernard J, Soulier JP (1948) A new variety of congenital hemorrhagic thrombocytic dystrophy, *Sem. Hop. Paris* 24: 3217-3222.
  21. Diz Kucukkaya R (2013) Inherited platelet disorders including Glanzmann thrombasthenia and Bernard-Soulier syndrome. *Hematology Am Soc Hematol Educ Program* 2013: 268-275.
  22. Peitsidis P, Datta T, Pafilis I, Otomewo O, Tuddenham EG, et al. (2010) Bernard Soulier syndrome in pregnancy: a systematic review. *Haemophilia* 16: 584-591.
  23. Puchmayer V, Roztocil K (2000) *Practical Angiology*; 2000; 1st Ed. Triton, Prague 191.
  24. Brodsky SV, Malinowski K, Golightly M, Jesty J, Goligorsky MS (2002) Plasminogen activator inhibitor-1 promotes formation of endothelial microparticles with procoagulant potential. *Circulation* 106: 2372-2378.
  25. Chargaff E, West R (1946) The biological significance of the thromboplastic protein of blood. *J Biol Chem* 166: 189-197.
  26. Lacroix R, Plawinski L, Robert S, Doeuvre L, Sabatier F, et al. (2012) Leukocyte- and endothelial-derived microparticles: A circulating source for fibrinolysis. *Haematologica* 97: 1864-1872.
  27. Lacroix R, Dignat-George F (2013) Microparticles: New protagonists in pericellular and intravascular proteolysis. *Semin Thromb Hemost* 39: 33-39.
  28. Lacroix R, Dubois C, Leroyer AS, Sabatier F, Dignat-George F (2013) Revisited role of microparticles in arterial and venous thrombosis. *J Thromb Haemost* 11: 24-35.
  29. Zeldis MS, Nemerson Y, Pitlick AF, Lentz LT (1972) Tissue Factor (Thromboplastin): Localization to Plasma Membranes by Peroxidase-Conjugated Antibodies. *Science* 175: 766-768.
  30. Ribatti D, Crivellato E (2007) Giulio Bizzozzero and the discovery of platelets. *Leuk Res* 31: 1339-1341.
  31. Chu AJ (2011) Tissue factor, blood coagulation, and beyond: an overview. *Int J Inflamm* 2011: 367284.
  32. Darbousset R, Thomas MG, Mezouar S, Frère C, Panicot-Dubois L, et al. (2012) Tissue factor-positive neutrophils bind to injured endothelial wall and initiate thrombus formation. *Blood* 120: 2133-2143.
  33. Rauch U, Bonderman D, Bohrmann, Badimon JJ, Nemerson Y, et al. (2000) Transfer of tissue factor from leukocytes to platelets is mediated by CD15 and tissue factor. *Blood* 96: 170-175.
  34. Lisman T (2018) Platelet-neutrophil interactions as drivers of inflammatory and thrombotic disease. *Cell Tissue Res* 371: 567-576.
  35. Swystun LL, Liaw CP (2016) The role of leukocytes in thrombosis. *Blood* 128: 753-762.
  36. Owens AP III, Mackman N (2011) Microparticles in hemostasis and thrombosis. *Circ Res* 108: 1284-1297.
  37. Mooberry JM, Key SN, for International Society for Advancement of Cytometry (2015) *Microparticle Analysis in Disorders of Hemostasis and Thrombosis*. Wiley Online Library (wileyonlinelibrary.com) DOI: 10.1002/cyto.a.22647V
  38. Park MS, Owen BAL, Ballinger BA, Sarr MG, Heit JA, et al. (2012) Quantification of hypercoagulable state after blunt trauma: Microparticle and thrombin generation are increased relative to injury severity, while standard markers are not. *Surgery* 151: 831-836.
  39. Lindemann S, Tolley ND, Dixon DA, McIntyre MTh, Weyrich SA, et al. (2001) Activated platelets mediate inflammatory signaling by regulated interleukin 1beta synthesis. *J Cell Biol* 154: 485-490.
  40. Andrews KR, Berndt CM (2008) Microparticles facilitate neutrophil/platelet crosstalk. *Blood* 112: 2174-2175.
  41. Bretelle F, Sabatier F, Desprez D, Camoin L, Dignat-George F, et al. (2003) Circulating microparticles: A marker of procoagulant state in normal pregnancy and pregnancy complicated by preeclampsia or intrauterine growth restriction. *Thromb Haemost* 89: 486-492.
  42. Carp H, Dardik R, Lubetsky A, Salomon O, Inbal A, et al. (2004) Prevalence of circulating procoagulant microparticles in women with recurrent miscarriage: a case- controlled study. *Hum Reprod* 19: 191-195.
  43. Enjeti AK, Lincz LF, Scorgie FE, Seldon M (2010) Circulating microparticles are elevated in carriers of factor V Leiden. *Thromb Res* 126: 250-253.
  44. Campello E, Spiezia L, Radu CM, Bon M, Simioni P, et al. (2012) Circulating microparticles in carriers of factor V Leiden with and without a history of venous thrombosis. *Thromb Haemost* 108: 633-639.
  45. Davizon P, Lopez JA (2009) Microparticles and thrombotic disease. *Curr Opin Hematol* 16: 334-341.
  46. Somajo S, Koshiar RL, Norström E, Dahlbäck B (2014) Protein S and factor V in regulation of coagulation on platelet microparticles by activated protein C. *Thromb Res* 134: 144-152.
  47. Garcia Rodriguez P, Eikenboom HCJ, Tesselaar MET, Huisman MV, Bertina RM, et al. (2010) Plasma levels of microparticle-associated tissue factor activity in patients with clinically suspected pulmonary embolism. *Thromb Res* 126: 345-349.
  48. Bal L, Ederhy S, Di Angelantonio E, Toti F, Tedgui A, et al. (2010) Circulating procoagulant microparticles in acute pulmonary embolism: A case-control study. *Int J Cardiol* 145: 321-322.
  49. Steppich BA, Hassenpflug M, Braun SL, Schomig K, Ott I, et al. (2011) Circulating tissue factor and microparticles are not increased in patients with deep vein thrombosis. *Vasa* 40: 117-122.
  50. Kooiman J, den Exter P, Kilicsov I, Cannegieler CS, Versteeg H, et al. (2015) Association between micro particle-tissue factor activity, factor VIII activity and recurrent VTE in patients with acute pulmonary embolism. *Journal of thrombosis and thrombolysis* 40: 323-330.
  51. Zhou J, May L, Liao P, Gross PL, Weitz JI (2009) Inferior

- vena cava ligation rapidly induces tissue factor expression and venous thrombosis in rats. *Arterioscler Thromb Vasc Biol* 29: 863-869.
52. Ramacciotti E, Hawley AE, Farris DM, Ballard NE, Wakefield TW, et al. (2009) Leukocyte-and platelet-derived microparticles correlate with thrombus weight and tissue factor activity in an experimental mouse model of venous thrombosis. *Thromb Haemost* 101: 748-754.
  53. Himer J, Wohlgensinger C, Roux S, Damico LA, Riederer MA, et al. (2003) Inhibition of tissue factor limits the growth of venous thrombus in the rabbit. *J Thromb Haemost* 1: 889-895.
  54. Alfirevic Z, Mousa HA, Martlew V, Perez-Casal M, Toh CH (2001) Postnatal Screening for Thrombophilia in Women with Severe Pregnancy Complications. *Obstet Gynecol* 97: 753-759.
  55. Poul H (2006) Thrombophilia important in the pathogenesis of venous thromboembolism (in Czech).
  56. Simcox EL, Ormisher L, Tower C, Greer AI (2015) Thrombophilia and pregnancy complications. *Int J Mol Sci* 16: 28418-28428.
  57. Clark P, Brennard J, Conkie JA, McCall F, Greer IA, et al. (1998) Activated protein C sensitivity, protein C, protein S and coagulation in normal pregnancy. *Thromb Haemost* 79: 1166-1170.
  58. Franchini M (2006) Haemostasis and pregnancy. *Thromb Haemost* 95: 401-413.
  59. Franchini M, Targher G, Montagnana M, Lippi G (2008) The metabolic syndrome and the risk of arterial and venous thrombosis. *Thromb Res* 122: 727-735.
  60. Kamphuisen PW, Lensen R, Houwing-Duistermaat JJ, Eikenboom JCJ, Rosendaal FR, et al. (2000) Heritability of elevated factor VIII antigen levels in factor V Leiden families with thrombophilia. *British Journal of Hematology* 109: 519-522.
  61. Mousa HA, Alfirevic Z (2001) Thrombophilia and adverse pregnancy outcome. *Croat Med J* 42: 135-145.
  62. Wu X, Yang K, Tang X, Sa Y, Tang W, et al. (2015) Folate metabolism gene polymorphisms MTHFR C677T and A1298C and risk for preeclampsia: a meta-analysis. *J Assist Reprod Genet* 32: 797-805.
  63. Foka ZJ, Lambropoulos AF, Saravelos H, Karas GB, Agorastos T, et al. (2000) Factor V Leiden and prothrombin G20210A mutations, but not methylene tetrahydrofolate reductase C677T, are associated with recurrent miscarriages. *Hum Reprod* 15: 458-462.
  64. Bates SM (2007) Management of Pregnant Women with Thrombophilia or a History of Venous Thromboembolism. *Hematology. Am Soc Hematol Educ Program* 2007: 143-150.
  65. Bates SM, Greer IA, Pabinger I, Sofar S, Hirsh J (2008) Venous thromboembolism, thrombophilia, antithrombotic therapy, and pregnancy: American College of Chest Physicians Evidence-Based Clinical Practice Guidelines. *Chest* 133: 844S-886S.
  66. Nelson SM, Greer IA (2008) The potential role of heparin in assisted conception. *Hum Reprod Update* 14: 623-645.
  67. Greer IA, Brenner B, Gris JC (2014) Antithrombotic treatment for pregnancy complications: Which path for the journey to precision medicine? *Br J Haematol* 165: 585-599.
  68. Jaraquemada PMJ, Garci R, Naco A, Barbosa SEN, Conesa AH, et al. (2007) Lower uterine blood supply: extrauterine anastomotic system and its application in surgical devascularization techniques *Acta Obstetrica et Gynecologica* 86: 228-234.
  69. Long S, Yang X, Liu X, Yang P (2012) Methylene tetrahydrofolate reductase (MTHFR) polymorphisms and susceptibility for cervical lesions: a meta-analysis. *PLoS One* 7: e52381.

*Copyright: ©2020 Manuela Cristina Russu. This is an open-access article distributed under the terms of the Creative Commons Attribution License, which permits unrestricted use, distribution, and reproduction in any medium, provided the original author and source are credited.*