

## Pre-Descemet's Endothelial Keratoplasty (PDEK): Learning Curve in the First Brazilian Cases

Emilio Almeida Torres-Netto\*, Maria Daniela Rivera-Monge, Denise de Freitas and Aline Moriyama

Department of Ophthalmology and Visual Sciences, Paulista School of Medicine (EPM), São Paulo Hospital, Federal University of São Paulo (UNIFESP), Sao Paulo, Brazil

### \*Corresponding author

Emilio Almeida Torres-Netto, MD, Department of Ophthalmology and Visual Sciences, Paulista School of Medicine (EPM), São Paulo Hospital, Federal University of Sao Paulo (UNIFESP), Rua Botucatu, 821 – Vila Clementino, 04023-062 – Sao Paulo, Brazil, Phone: +55 (11) 5058-2082; E-mail: emilioatorres@me.com

Submitted: 23 Apr 2018; Accepted: 30 Apr 2018; Published: 08 May 2018

### Abstract

**Purpose:** To describe the learning curve of pre-descemet endothelial keratoplasty (PDEK) and the intraoperative findings of the first 5 cases performed at Federal University of Sao Paulo.

**Methods:** Five PDEK procedures were performed by the same surgeons; four cases used pneumodissection and one case used reverse hydro-bubble technique to obtain the donor graft. All cases were recorded and the following intraoperative variables were measured: type of bubble obtained, button size used and time of opening and centralization of the graft in the recipient anterior chamber.

**Results:** Type-1 Big Bubble (BB) was achieved in three of the four cases that air dissection was used. In the fourth case of pneumodissection, there was simultaneous formation of type-1 and type-2 BB. When balanced saline solution was used for dissection, type-2 BB was obtained. Every time type-2 BB was formed, the procedure was then converted to Descemet Membrane Endothelial Keratoplasty (DMEK). When only type-1 BB was achieved, the PDEK was uneventful with an easier manipulation of the tissue and a quicker opening in the recipient anterior chamber. Namely, grafts that included pre-Descemet's layer were less elastic and less curled. The graft size used varied from 7.50 to 7.75mm.

**Conclusion:** PDEK is a recent technique of endothelial keratoplasty. Early outcomes suggest potential advantages in the learning curve over the prior procedures, especially by the facilitated manipulation of PDEK graft in the anterior chamber. Although results with this technique seem promising, the potential advantages need to be confirmed with long-term postoperative follow-up.

**Keywords:** Pre descemet endothelial keratoplasty (PDEK), Lamellar keratoplasty, Dua's layer, Pre- Descemet's layer, Endothelial keratoplasty

### Introduction

After 100 years of penetrating keratoplasty (PK) being at the forefront, lamellar transplants (LK) began to be performed. The first attempt to carry out LK was described by Barraquer in 1950 [1].

The Endothelial Keratoplasty (EK) is a corneal transplant technique that selectively replaces the pathological endothelium maintaining the integrity of the previous layers of the cornea. It is the preferred modality for the treatment of purely corneal endothelial disorders, as it provides a better final visual acuity, faster visual recovery and lower rejection rates [2]. The two most used EK techniques are Descemet's Stripping Automated Endothelial Keratoplasty (DSAEK) and Descemet Membrane Endothelial Keratoplasty

(DMEK). In DSAEK, the corneal graft includes endothelium, Descemet's Membrane (DM) and a thin layer of posterior stroma; in DMEK, the graft includes only endothelium and DM.

Despite the growing popularity and reported advantages of DMEK, DSAEK is still used widely in many centers. Barriers to implementation of DMEK include greater complexity for preparation of the donor and intraoperative difficulty, especially when opening and positioning the corneal graft in the anterior chamber [1].

In 2013, Dua described an acellular layer composed of collagen located between the DM and the adjacent corneal stroma [3]. Based on that description Agarwal et al. unprecedentedly published a series of five cases of EK in which the grafts were obtained by pneumodissection. This technique became known as PDEK, where the transplanted tissue was comprised not only of endothelium and DM, but also included the Pre-Descemet's Layer (PDL) or so called

Dua's layer [4]. Despite few cases with long follow-up reported, PDEK technique seems to have equivalent surgical outcomes than DMEK, nonetheless with potentially better reproducibility due to lower intraoperative surgical difficulty. This study aims to report the surgical findings of the first cases of PDEK performed in Department of Ophthalmology and Visual Sciences, Paulista School of Medicine, at Federal University of Sao Paulo (UNIFESP).

## Methods

This study is compliant with the declaration of Helsinki and was approved by the Institutional Review Board of UNIFESP.

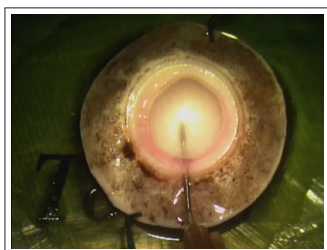Five eyes of five patients with indication of endothelial keratoplasty underwent PDEK at the External Eye Disease and Cornea Service of Paulista Medical School in 2015. All patients signed an informed consent to undergo the surgeries that were performed by the same (surgeons (EATN and ASM). Local anesthesia (retro bulbar) and sedation were always used. All cases were recorded, and the following intraoperative variables were analyzed: type of big-bubble (BB), graft size used, opening time and centralization of the graft (OTCG) in the anterior chamber (AC).

## Surgical Technique

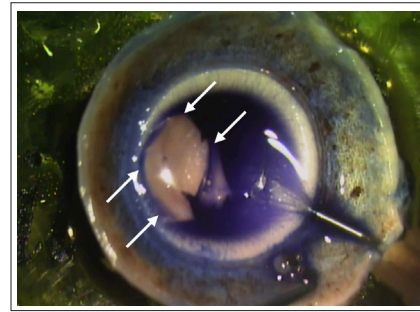
### Preparation of the Donor Button

The corneal scleral donor disk was placed on a flat surface with endothelial side up. In order to obtain the graft two similar techniques were performed: pneumodissection (PD) and reverse hydro-bubble (RHB). In both, a 5ml syringe and a 30-gauge needle were used. The needle was inserted distally to the trabecular meshwork, with the bevel facing upward until it reached the corneal stroma in its paracentral portion. The substance used for the corneal layer dissection was the differential between the two techniques: air was used in PD, and balanced saline solution (BSS) in RHB.

With the injection of air or BSS two kinds of bubbles may be obtained, as cited in previous publications [3,4]. The type-1 BB (**Figure 1**) is formed when the separation occurs between the posterior corneal stroma and PDL. Generally, it occurs in approximately 80% of cases after pneumodissection [5]. The formation of a type-1 BB starts in the center and further expands towards the periphery, with an average diameter of 7.0 to 8.5mm [3]. When this type of bubble occurs, the graft obtained consists of endothelium, DM and PDL. After bubble formation, the graft was removed with the use of a trephine and if required, gentle scissor cuts. On the other hand, formation of a type-2 BB (**Figure 2**) starts at the corneal periphery and expands centripetally. This latter type of bubble separates PDL and DM, thus the graft lamella consists of only endothelium and DM [3]. It is interesting to note that there is a possibility of simultaneous formation of type-1 and 2 BB. Whenever a type-2 BB or simultaneous bubbles were obtained, the surgical technique was converted to DMEK.



**Figure 1:** Type 1 bubble



**Figure 2:** Type 2 bubble (delimited by the arrows)

After obtaining the graft, it was stained with trypan blue 0.1% (Ophthalmos SA, Sao Paulo, Sao Paulo, Brazil) in order to improve the visualization of the tissue in AC during the implantation.

### Preparing Recipient Eye and Inserting the Graft

Method of preparation of the recipient was the same as described for DMEK [6]. In patients that had already undergone DMEK or DSAEK (**Table 1**), it was not necessary to perform descemetorexis since this had already been done previously. A surgical inferior iridectomy was performed and viscoelastic substances were not used.

The donor tissue was implanted by a 2, 8 mm clear corneal incision, using a modified intraocular lens (IOL) injector [7]. The insertion in the AC was performed slowly and the graft was opened and centered with no-touch technique maneuvers [8]. Final steps were air injection under the graft and AC pressurization for 30 minutes.


## Results

The intraoperative variables of the surgical technique in each patient are shown in **Table 1**.

## Discussion

In 2014, the first five cases of PDEK were published [4]. The present article reports the first series of cases using this surgical technique in our country.

Different intraoperative variables were analyzed. We could observe that when the graft was obtained from BB type-1, the tissue enrolled less (**Figure 3**) and the opening in the AC was easier. This occurred even when a 27-year-old donor cornea was used, situation in which a DMEK graft would tend to curl up more. Our results suggest that whenever PDEK was performed there was less difficulty in manipulating and opening the tissue in the AC of the recipient. Not only a subjective perception of surgeons, such convenience was indirectly shown by the reduced time required to fully open and center the graft (**Table 1**).



**Figure 3:** Donor grafts number 1, 2 and 3 (PDEK / type-1 bubble); donor grafts number 4 and 5 (DMEK / type-2 bubble)

**Table 1: Intraoperative Variables of the Surgical Technique in Each Patient**

Case	Patient's Age (years)	Operated Eye	Etiology	Donor's Age (years)	LDT	Type of Bubble	Graft Size (mm)	OTCG	Complications
1	78	OS	BK	56	PD	1	7.75	3min 45s	No
2	74	OS	DSAEK PF (BK)	64	PD	1	7.75	29s	No
3	70	OS	DMEK PF (BK)	27	PD	1	7.75	55s	No
4	68	OS	DMEK PF (BK)	50	RHB	2	7.50	10min	Conversion to DMEK
5	75	OS	DSAEK PF (BK)	44	PD	1/2	7.5	30min	Conversion to DMEK

**OTCG:** opening time and centralization of graft, PF: primary failure, BK: bullous keratopathy, LDT: lamellar dissection technique

A potential advantage of PDEK is that younger corneas (<50 years) often not used in DMEK, could be used. When performing DMEK surgeons preferentially use older corneas, since the corneas of young donors show increased elasticity and consequently greater difficulty of opening in AC. Hence, the use of a wider donor age range certainly could increase the availability of corneas for endothelial transplantation in certain regions of the world, in particular where corneal tissues are not widely accessible.

By definition, the formation of BB type-1 is required to perform PDEK. Accordingly, that means the diameter of the graft would never be greater than 8.5mm. Therefore, one could argue that a limitation of this technique might be a lower endothelial cell transfer, owing to limited size of the transplanted tissue (3-5). This barrier, nevertheless, might be potentially counter balanced by easier handling of those grafts and the increased endothelial cell density of the younger corneas.

Another point to highlight is the possible intraoperative conversion to DMEK if a type-2 BB is formed during the graft preparation, as it occurred in two of our patients. Whence, type-2 BB formation is not synonymous of tissue loss as the same may be used for DMEK technique. Thus despite the easier handling of the corneal graft with PDEK, it does not exempt the surgeon's training and familiarity with DMEK and the manual dissection technique. This is particularly important in countries such ours, where pre-prepared grafts are not yet fully available and the number of corneas is limited.

### Conclusion

In conclusion, PDEK is a recent surgical technique of endothelial keratoplasty based on the existence of the pre-Descemet's or Dua's layer. Early outcomes suggest potential advantages in the learning curve over the prior procedures. Long-term prospective studies are needed to confirm the promising results and the learning curve of this technique.

### References

1. Tourtas T, Laaser K, Bachmann BO, Cursiefen C, Kruse FE (2012) Descemet membrane endothelial keratoplasty versus descemet stripping automated endothelial keratoplasty. *Am J Ophthalmol* 153: 1082-1090.
2. Terry MA (2012) Endothelial keratoplasty: why aren't we all doing Descemet membrane endothelial keratoplasty? *Cornea* 31: 469-471.
3. Dua HS, Faraj LA, Said DG, Gray T, Lowe J (2013) Human corneal anatomy redefined: a novel pre-Descemet's layer (Dua's layer). *Ophthalmology* 120: 1778-1785.
4. Agarwal A, Dua HS, Narang P, Kumar DA, Agarwal A, et al. (2014) Pre-Descemet's endothelial keratoplasty (PDEK). *Br J Ophthalmol* 98: 1181-1185.
5. Altaan SL, Gupta A, Sidney LE, Elalfy MS, Agarwal A, et al. (2015) Endothelial cell loss following tissue harvesting by pneumodissection for endothelial keratoplasty: an ex vivo study. *Br J Ophthalmol* 99: 710-713.
6. Melles GR, Ong TS, Ververs B, van der Wees J (2008) Preliminary clinical results of Descemet membrane endothelial keratoplasty. *Am J Ophthalmol* 145: 222-227.
7. Kim EC, Bonfadini G, Todd L, Zhu A, Jun AS (2014) Simple, inexpensive and effective injector for descemet membrane endothelial keratoplasty. *Cornea* 33: 649-652.
8. Dapena I, Moutsouris K, Droutsas K, Ham L, van Dijk K, et al. (2011) Standardized "no-touch" technique for descemet membrane endothelial keratoplasty. *Arch Ophthalmol* 129: 88-94.

**Copyright:** ©2018 Emilio Almeida Torres-Netto, et al. This is an open-access article distributed under the terms of the Creative Commons Attribution License, which permits unrestricted use, distribution, and reproduction in any medium, provided the original author and source are credited.