

## Pneumococcal Meningitis Among Children in the Post-13-Valent Pneumococcal Conjugate Vaccine Era: Three Case Reports

Hind Al Hajri<sup>1</sup>, Hilal Al Hashami<sup>2</sup> and Salah Al Awaidy<sup>\*3</sup>

<sup>1</sup>Oman Medical Specialty Board, Muscat, Oman

<sup>2</sup>Royal Hospital, Muscat, MOH, Oman

<sup>3</sup>Office of Health Affairs, MOH, Oman

### \*Corresponding author

Salah T Al Awaidy, Office of Health Affairs, MOH, P. O. Box 393 PC 100, Muscat, Oman

Submitted: 28 Aug 2020; Accepted: 03 Sep 2020; Published: 14 Sep 2020

### Abstract

We report three cases under two years of age, of meningitis due to *Streptococcus pneumoniae* in vaccinated children. Two grew non-typable strain and the third serotype 10A. All improved with no neurological sequel. Continued monitoring of the epidemiology of bacterial meningitis within the post13-valent pneumococcal conjugate vaccine introduction is warranted.

**Keywords:** *Streptococcus Pneumoniae*; Pneumococcal Conjugate Vaccine; Invasive Pneumococcal Disease; Oman

### Introduction

Acute bacterial meningitis is a serious disease and a medical emergency with a high rate of mortality and risk of neurological sequels, especially among young children [1, 2]. Additionally, the disease can have negative impacts on cerebral blood perfusion, resulting in hypoxia and cell death. It requires an efficient therapy that may rapidly sterilize the central nervous system and limit the inflammatory response [3]. Furthermore, the mortality rate attributed to pneumococcal meningitis is significantly higher (30%) compared to meningococcal meningitis (7%) [1].

In 2017, globally, around 5 million new cases and 290 000 deaths were attributed to pneumococcal meningitis. Although meningitis affects all ages, children under five years of age are mostly in jeopardy, constituting around half of all events and deaths [1, 2]. While global meningitis mortality decreased by 21% from 1990 to 2016, the overall burden of meningitis remains significant, predominantly among children within the developing world [1].

Moreover, bacterial meningitis has enormous economic implications for health care providers and families [4, 5]. Within that group, *Streptococcus pneumoniae* infection remains the foremost common reason for bacterial meningitis in children in many countries, ranging from 22.5% in Europe to 41.1% in Africa [6].

Ultimate failure to accurately diagnose and promptly treat meningitis generally and pneumococcal meningitis specifically,

invariably leads to devastating consequences, including death or significant morbidity. Survivors can allegedly suffer severe sequelae with considerable personal, social and economic costs for health care providers and families [7, 8].

During the neonatal period, the foremost common pathogen causing meningitis is a *Group B streptococci* (GBS), followed by *Escherichia coli*, *Listeria monocytogenes* and *S. pneumoniae* [9]. After the neonatal period, *S. pneumoniae* becomes the most common bacterial cause of meningitis, followed by *Nisseria meningitidis*, *Hemophilus influenzae* and other bacterial agents [10-13].

Despite the provision and uptake of the vaccine, bacterial meningitis continues to represent a major cause of emergency access to hospitals [14, 15]. In Oman, all cases of suspected meningitis will be referred from a primary health care to the hospital emergency department for further evaluation and assessment. During the past two decades, significant changes have taken place in the epidemiology of pneumococcal meningitis, including a decrease in the incidence of pneumococcal meningitis globally, mainly attributed to the availability of pneumococcal conjugate vaccine (PCV) [16-18].

In 2007, World Health Organization (WHO) recommended the inclusion of the first pneumococcal conjugate vaccine into the national extended program of immunization (EPI), the 7-valent conjugated pneumococcal vaccine (PCV7) which offered

protection against 7 serotypes (1, 5, 6A, 6B, 14, 19F, 23F). Subsequently, PCV7 has been replaced by PCV13 (serotypes, 1, 3, 4, 5, 6A, 6B, 7F, 9V, 14, 18C, 19A, 19F and 23F) or PCV10 (serotypes, 1, 4, 5, 6B, 7F, 9V, 14, 18C, 19F and 23F) [19, 20].

The 7-valent conjugated pneumococcal vaccine was first introduced in Oman into the EPI in November 2008. From May to October 2010, PCV 13 was inaugurated. In November 2010, PCV13 was replaced by PCV10, given at 2, 4, 13 months of age. In December 2011, PCV10 was replaced by PCV 13 in 2011 given at 2, 4, 13 months of age (2 + 1). The coverage rates of PCV13 was 98% for the 3 doses.

In Oman, the incidence of meningitis declined from 9.3 cases/100 000 population in 1995 to 2.3 cases/100 000 population in 2018 [21-24]. Pneumococcal meningitis contributed to 65.9% of meningitis cases with the highest rate of occurrence among children < 2 years old (39.4%) [24, 25]. Young children with meningitis typically present with non-specific signs and symptoms, including fever, and a bulging fontanel; while older children may present with fever, headache and a stiff neck. Cerebrospinal fluid culture is the gold standard used for the diagnosis of bacterial meningitis [26]. Despite the declining incidence, pneumococcal meningitis has significant rates of long-term complications [21, 22].

In 2019, we observed a surge of pneumococcal meningitis cases, and here, we are presenting three cases of pneumococcal meningitis due to *S. pneumoniae* in fully vaccinated children by their age as per the national schedule.

## Case Presentation

### Case one

A seventeen-months-old boy, Omani, a known case of G6PD deficiency, was brought by his parents to the emergency department in May 2019 with two days' history of high-grade fever and vomiting. The mother was worried because within the previous couple of days before presentation, he had a history of reduced activity and interaction. The child was followed in private hospital and managed as upper respiratory tract infection (URTI). No past history of any disease was present and development was appropriate for his age. The child had all due vaccination as per the national schedule, including PCV 13 in 2, 4 and 13 months. No past medical, family and psychosocial history were present.

On physical exam, he was febrile (oral temperature of 37.80 C) with systolic blood pressure of 85 mmHg, diastolic blood pressure of 53 mmHg, heart rate of 110 beats per minute, and respiratory rate of 40 per min. The central and peripheral nervous systems were evaluated completely, and he was lethargic and had neck stiffness. There have been no abnormal findings of the assessment of the other organs.

A cranial computed tomography (CT) scan was planned for the patient, which showed mild brain edema. A lumbar puncture

was subsequently done. The cerebrospinal fluid (CSF) had a clear appearance, while the analysis yielded white blood cell (WBC) count of 400/ $\mu$ L (with 85% polymorphonuclear cells), elevated protein levels (1.46 g/L), and decreased glucose levels (3.2 mmol/L), with serum glucose of 8mmol/L. No organism was discovered on the gram stain of the CSF.

His complete blood count showed neutrophilic leukocytosis with total WBC of  $28 \times 10^9$ /L and absolute neutrophils count of  $24.7 \times 10^9$ /L. Blood and CSF cultures obtained yielded a non-typable strain of *S. pneumoniae*.

The child was diagnosed as a case of meningitis and empirical antimicrobial therapy with intravenous ceftriaxone with a dose of ceftriaxone 50 mg/kg/day every 12 hours and vancomycin 15mg/kg intravenously every 8 hours were commenced. When the culture results were available, vancomycin was stopped and only ceftriaxone 50 mg/kg/day every 12 hours was continued. Nevertheless, the child remained persistently febrile and appeared unwell. Brain CT scan with contrast, that was performed on day four of the antibiotic treatment, showed leptomeningeal enhancement and right frontoparietal subdural collection suggestive of an effusion. The cranial magnetic resonance imaging (MRI) was done subsequently in the course of his illness which showed right frontoparietal subdural effusion, with no empyema or abscess formation.

The child stayed on the same antibiotic regimen for three weeks and improved clinically and also the fever subsided. Follow up MRI showed small residual subdural collections with enhanced dura mainly on the right side. There have been no abscess and no brain edema. The child was continued on intravenous antibiotic ceftriaxone for additional three weeks. MRI after three weeks showed improvement of small right frontal collection, merely with the persistent enhancing dura and meningeal coverage extending to right temporal fossa with no significant accumulation. During the initial course of complicated meningitis; neurosurgeon's services was consulted and that they advised to continue on medical management with no neurological intervention required at that point of consultation.

Rifampin 15 mg /kg/day orally was also started by the infectious diseases team for six weeks in addition to intravenous ceftriaxone. His fever subsided gradually and he was discharged on both ceftriaxone and oral rifampicin. Follow up cranial MRI after one month showed tiny residual left frontal and right frontal collection, with residual dura enhancement, which is less conspicuous than before.

Although the child was asymptomatic, due to prolonged use of ceftriaxone; ultrasound scans (US) of the abdomen showed multiple gall bladder stones. Ceftriaxone was stopped, and intravenous levofloxacin was started and went on for another four weeks.

The child's family decided to go for a second opinion abroad. There he continued on levofloxacin for four weeks and subsequently switched to intravenous cefotaxime. Craniotomy and removal of subdural collection were performed at the end of the antibiotic treatment.

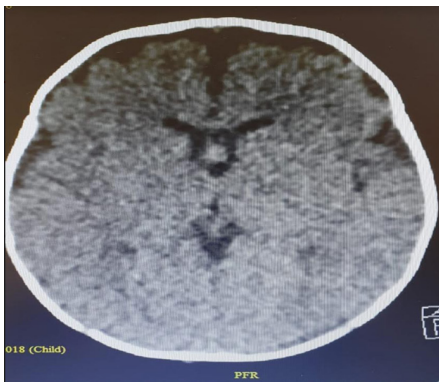
Histopathological investigation of the drained fluid showed reactive fibrous tissue with a mixed inflammatory infiltrate and focal granulation tissue. The culture of tissue was negative for bacterial growth. The child was discharged home. He was followed up in the outpatient clinic by infectious disease service and found active, afebrile with no neurological sequelae.

### Case Two

A two months old Omani female, was referred from a private hospital with a three-day history of fever, lethargy and focal seizure. There was no past medical history of any disease and her growth and development were appropriate for her age. The child received all due vaccination as per the national schedule, including PCV 13 in 2 months.

The child was initially seen in a private hospital, where she was admitted and received intravenous antibiotics, no report was available about the antibiotic administered in the private hospital. She developed seizures with facial deviation to the right side when she was transferred to tertiary care in June 2019 for further evaluation and management.

She was admitted and investigated; a lumbar puncture was performed and CSF test result was reported as follows: CSF red blood cells: 150 per mm<sup>3</sup>, CSF WBC: 400 per mm<sup>3</sup> polymorph 80%, lymphocyte 15%), CSF glucose: 2.5 mmol/L, blood glucose: 5.1 mmol/L, CSF protein: 1.22 g/L. All cultures, including blood, urine, and CSF were negative for bacterial growth. CSF bacterial PCR came positive for *S. pneumoniae*. Serotype identification was not possible. Cranial CT showed focal areas of reduced density in the left parietal lobe and the enhancement of the leptomeninges of the left frontal region [Figure 1].



**Figure 1.** Cranial CT showed focal areas of reduced density in the left parietal lobe and the enhancement of the leptomeninges of the left frontal region, Case two, Oman.

Intravenous cefotaxime was started for a duration of 2 weeks. The seizure stopped and also the standard level of wakefulness and activity regained. The infant was discharged after completion of the antibiotic course. She was followed up in the pediatric infectious diseases clinic. She improved significantly with no neurological sequel.

### Case Three

An eight-month-old, Omani, previously healthy boy, presented to the emergency department in June 2019 with two days' history of fever, vomiting, and lethargy. There was a history of passing loose stool twice a day prior to his presentation.

There was no past medical history of any disease and no family and psychosocial history. His growth and the development were appropriate for his age. The child received all due vaccination as per the national schedule, including PCV 13 in 2 and 4 months.

On the initial physical examination, he was ill with persistent tachycardia (172 bpm), febrile (38.4°C), BP 97/66 mmHg. Chest X-ray was performed and showed borderline cardiomegaly. The child was admitted with an initial impression of viral myocarditis and acute gastroenteritis.

His investigations showed a normal initial blood count. On the second day of his admission, the child was observed to be more lethargic with poor response, then he developed focal seizure, and got intubated and shifted to the pediatric intensive-care unit (PICU), where he was started on intravenous ceftriaxone 50 mg / kg/day divided every 12 hours.

The blood culture yielded *S. pneumoniae* with serotype 10A. Lumbar puncture was not done as he was unsuitable for the process and thus no CSF was taken for investigation. Cranial CT showed: patchy parenchymal enhancement with multiple scattered areas of diffusion restriction, suggestive of an acute ischemic insult.

During his admission to intensive care, the child showed clinical improvement and was transferred to the pediatric medical ward for the continuation of care. No more seizures were reported, and he was alert and active in the ward with no residual neurological deficit noted. He was treated with intravenous ceftriaxone for 25 days, CSF was done at the terminal stage of the treatment course, and it showed no pleocytosis. He was discharged and planned for one more week of intravenous ceftriaxone in the daycare. In his subsequent follow-up clinic in the pediatric infectious diseases team; he was active, and immunologic and neurological evaluation was done with no defect.

### Discussion

Globally, the proportion of PCV13-type pneumococcal meningitis decreased within the post-PCV era, however, pneumococcal meningitis has not been eliminated [23-27]. A rise in invasive pneumococcal disease (IPD) due to non-PCV13 serotypes has also been extensively documented among several developed and non-

developed countries following PCV13 introduction; however, the spectrum of the disease varies unpredictably among the countries [28-32].

The non-vaccine serotype pneumococcal meningitis increased from 98% to 127% compared to the pre-vaccine era [33]. The incidence rate of IPD is highest in children aged < 2 years and therefore rare non-vaccine serotypes of *S. pneumoniae* may be accountable for acute meningitis in vaccinated or unvaccinated children [3, 34-37].

In Oman, the routine use of PCV7, PCV10, and PCV13 in children have led to sharp declines in the incidence of IPD caused by the vaccine serotypes among children. Nevertheless, the emergence of non-PCV13 serotypes among children less than 5 years was not subsequently documented in Oman [38].

We reported three cases of pneumococcal meningitis in our hospitals. A case (number 3) suffered from a disease caused by serotypes not included within the PCV13 vaccine (10A). The same finding observed in other countries, that serotype 10A [35]. This outcome is coherent with other studies, which demonstrated the detection of rare non-vaccine serotypes (7A, 8, 15, 15C, 2, 10, 6, 17, 16F, and 23A) [37, 39]. Other emerging non-PCV13 serotypes were also observed, among which mostly 1, 7F, 12F, 19A, 22F, and 24F were related to a rise in IPD rates among youngsters in Europe [3, 34-36].

Two cases received an incomplete PCV13 vaccination (case number 2 and 3) as they were undue for vaccination. The likelihood of increased risk of IPD due to PCV13 serotypes within the first year of life, before the second and booster dose, remains high, therefore, the risk of vaccine-serotype disease is high in non-vaccinated [40]. It has been estimated that the contribution of non-PCV13 serotypes among the countries that introduced the higher-valent PCVs were 42% of childhood IPD [40].

The physician attending to the child should be aware of the possible organisms prevalent in the vicinity and their antimicrobial sensitivity in order to initiate prompt and appropriate antibiotic therapy. The initial antibiotic therapy for a child with suspected meningitis should be guided by the national surveillance data and local susceptibility data. The antibiotics dose should also be optimal for the child's weight and for time-dependent antibiotics such as ceftriaxone twice-daily regimen is preferred than once daily dose. The regimen should initially include coverage of resistant organisms like resistant streptococcus or MRSA till the final culture result is finalized along with antibiotics' susceptibility pattern.

The three cases in this report fully recovered, hence the likely possibility of low virulence with the invasive strain with low morbidity if the proper treatment is sought. It has been estimated

that the median risk of at least 1 major sequelae represents 25%, for pneumococcal meningitis. Long and short-term sequelae after discharge from the hospital have also been reported. Hearing loss was the foremost common major side effects, and others invariably include seizures and mental retardation, behavioral/intellectual disorders all of which may be temporary or may result in long-term disability. Accordingly, a proper and long-term follow-up of those patients is warranted [7, 8].

To conclude, the present case studies eluded that within the post PCV13 era, *S. pneumoniae* meningitis continues to remain a prime concern among our children. Additionally, we highlight the considerable importance of enhancing the national surveillance of IPD which helps and guides in adequately understanding the epidemiology of bacterial meningitis and to vigilant monitoring trends of serotypes causing the disease within the post-PCV13 introduction era.

## References

1. Defeating Meningitis by 2030 a global roadmap (2020). <https://www.who.int/immunization/research/development/DefeatingMeningitisRoadmap.pdf>
2. Global Burden of Disease Collaborative Network. The Global Burden of Disease Study 2017 (GBD 2017) Results. Seattle (WA): Institute for Health Metrics and Evaluation; 2019 <http://ghdx.healthdata.org/gbd-results-tool>.
3. Kaplan, Sheldon L, M.L. Volker-Soberanes (2013) Early Trends for Invasive Pneumococcal Infections in Children After the Introduction of the 13-valent Pneumococcal Conjugate Vaccine. The Pediatric Infectious Disease Journal 32: 203-207.
4. Portnoy A, Jit M, Lauer J, Adriaan Blommaert, Sachiko Ozawa, et al. (2015) Estimating costs of care for meningitis infections in low- and middle-income countries. Vaccine 33: A240-A247.
5. Usuf E, Mackenzie G, Sambou S, Atherly D, Suraratdecha C (2016) The economic burden of childhood pneumococcal diseases in The Gambia. Cost Eff Resour Alloc 14: 4.
6. Oordt-Speets AM, Bolijn R, van Hoorn RC, Bhavsar A, Kyaw MH (2018) Global etiology of bacterial meningitis: A systematic review and meta-analysis. PLoS ONE 13: e0198772.
7. Edmond K, Dieye Y, Griffiths UK, Jessica Fleming, Ousseynou Ba, et al. (2010) Prospective cohort study of disabling sequelae and quality of life in children with bacterial meningitis in urban Senegal. Pediatr Infect Dis J 29: 1023-1029.
8. Goetghebuer T, West TE, Wermenbol V, A L Cadbury, P Milligan, et al. (2000) Outcome of meningitis caused by Streptococcus pneumoniae and Haemophilus influenzae type b in children in The Gambia. Trop Med Int Health 5: 207-213.
9. Heath P, Nik Y, Baker C (2003) Neonatal meningitis. Arch Dis Child Fetal Neonatal Ed 88: F173-F178.

10. Mado SM, Aliyu I (2018) Acute bacterial meningitis in Nigerian children beyond neonatal period: A review. *Niger J Basic Clin Sci* 15: 1.
11. Nigrovic LE, Kuppermann N, Malley R, for the Bacterial Meningitis Study Group of the Pediatric Emergency Medicine Collaborative Research Committee of the American Academy of Pediatrics (2008) Children with Bacterial Meningitis Presenting to the Emergency Department during the Pneumococcal Conjugate Vaccine Era. *Acad Emerg Med* 15: 522-528.
12. Cho HK, Lee H, Kang JH, Kim KN, Kim DS, et al. (2010) The Causative Organisms of Bacterial Meningitis in Korean Children in 1996-2005. *J Korean Med Sci* 25: 895-899.
13. Thigpen MC, Whitney CG, Messonnier NE, Zell ER, Lynfield R, et al. (2011) Bacterial Meningitis in the United States, 1998-2007. *N Engl J Med* 364: 2016-2025.
14. R Khan F, Rizvi M, Fatima N, Shukla I, Malik A, et al. (2011) Bacterial meningitis in North India: trends over a period of eight years. *Neurol Asia* 16: 47-56.
15. Saeed N, Al Ansari H, Al Khawaja S, Jawad JS, Nasser K, et al. (2016) Trend of bacterial meningitis in Bahrain from 1990 to 2013 and effect of introduction of new vaccines. *East Mediterr Health J* 22: 17.
16. World Health Organization (2019) Pneumococcal conjugate vaccines in infants and children under 5 years of age: WHO position paper—February 2019. [who.int/iris/bitstream/handle/10665/310968/WER9408.pdf?ua=1](http://www.who.int/iris/bitstream/handle/10665/310968/WER9408.pdf?ua=1) O'Brien KL, Wolfson LJ, Watt JP, Henkle E, Deloria-Knoll M, et al. (2009) Burden of disease caused by *Streptococcus pneumoniae* in children younger than 5 years: global estimates. *Lancet* 374: 893-902.
17. World Health Organization (2008) Estimated Hib and pneumococcal deaths for children under 5 years of age.
18. World Health Organization (2007) Pneumococcal conjugate vaccine for childhood immunization- WHO position paper. *Wkly Epidemiol Rec* 82: 93-104.
19. World Health Organization (2015) WHO vaccine-preventable diseases: monitoring system. 2015 global summary 2015.
20. Edmond K, Clark A, Korczak VS, Sanderson C, Griffiths UK, et al. (2010) Global and regional risk of disabling sequelae from bacterial meningitis: a systematic review and meta-analysis. *Lancet Infect Dis* 10: 317-328.
21. Allan T van de beek D, Michael S (2015) Acute meningitis. In: Mandell, Douglas and Bennett's Principles and Practice of Infectious Diseases. Eight Edition 2015: 201-204.
22. N Dash, S Al Khusaiby, T Behlim, A Mohammadi, E Mohammadi, et al. (2009) Epidemiology of meningitis in Oman, 2000-2005. *Eastern Mediterranean Health Journal* 15: 1358-1364.
23. Annual Health Report, MOH, Oman (2018) <https://www.moh.gov.om/en/-/201-7>
24. Padmamohan J Kurup, Seif Al-Abri, Salim Al-Mahrooqi, Amina Al-Jardani, Shyam Bawikar, et al. (2018) Epidemiology of Meningitis in Oman: Implications for Future Surveillance. *Journal of Epidemiology and Global Health* 8: 231-235.
25. Matthijs C Brouwer, Allan R Tunke, Diederik van de Beek (2019) Epidemiology, Diagnosis, and Antimicrobial Treatment of Acute Bacterial Meningitis. *Clin Microbiol Rev* 23: 467-492.
26. Lorna Awo Renner, Effua Usuf, Nuredin Ibrahim Mohammed, Daniel Ansong, Thomas Dankwah, et al. (2019) Hospital-based Surveillance for Pediatric Bacterial Meningitis in the Era of the 13-Valent Pneumococcal Conjugate Vaccine in Ghana. *cid* 69: S89-S96.
27. Lepoutre A, Varon E, Georges S, F Dorléans, C Janoir, et al. (2015) Impact of the pneumococcal conjugate vaccines on invasive pneumococcal disease in France, 2001-2012. *Vaccine* 33: 359-366.
28. Moore MR, Link-Gelles R, Schaffner W, Ruth Lynfield, Catherine Lexau, et al. (2015) Effect of use of 13-valent pneumococcal conjugate vaccine in children on invasive pneumococcal disease in children and adults in the USA: analysis of multisite, population-based surveillance. *Lancet Infect Dis* 15: 301-309.
29. Baldovin T, Lazzari R, Russo F, C Bertonecello, A Buja, et al. (2016) A surveillance system of invasive pneumococcal disease in North- Eastern Italy. *Ann Ig* 28: 15-24.
30. Hanquet G, Krizova P, Valentiner- Branth P, Shamez N Ladhani, J Pekka Nuorti, et al. (2019) SpIDnet/I-MOVE+ Pneumo Group. Effect of childhood pneumococcal conjugate vaccination on invasive disease in older adults of 10 European countries: implications for adult vaccination. *Thorax* 74: 473-482.
31. Ladhani S, Collins S, Djennad A, Carmen L Sheppard, Ray Borrow, et al. (2018) Rapid increase in non-vaccine serotypes causing invasive pneumococcal disease in England and Wales: a prospective national observational cohort study, 2000-2017. *Lancet Infect Dis* 18: 441-451.
32. Alari A, Cheysson F, Le Fouler L, Lanotte P, Varon E, et al. (2019) Association of Pneumococcal Conjugate Vaccine Coverage With Pneumococcal Meningitis: An Analysis of French Administrative Areas, 2001-2016. *Am J Epidemiol* 188: 1466-1474.
33. Lorena Rodríguez-Muñoz, Fortino Solórzano-Santos, Edgar A Flores-Reyes, Juana Escalante-López, Dora E Rodríguez-Balderas, et al. (2018) Invasive non-vaccine serotype infections of *Streptococcus pneumoniae*: a growing threat. *Bol Med Hosp Infant Mex* 76: 281-286.
34. Jackson MA (2016) Pediatric Infectious Disease: Part II. An Issue of Infectious Disease Clinics of North America, E-Book. Elsevier Health Sciences 2016: 201.
35. Sheldon L Kaplan, William J Barson, Philana Ling Lin, José R Romero, John S Bradley, et al. (2019) Invasive Pneumococcal Disease in Children's Hospitals: 2014-2017. *Pediatrics* 144:

---

e20190567.

36. Dong-Chul Park, Si Hyun Kim, Dongeun Yong, In Bum Suh, Young Ree Kim, et al. (2019) Serotype Distribution and Antimicrobial Resistance of Invasive and Noninvasive *Streptococcus pneumoniae* Isolates in Korea between 2014 and 2016. *Ann Lab Med* 39: 537-544.
37. Al-Jardani (2019) *International Journal of Infectious Diseases*, 85 (2019) 135–140
38. Mehmet Ceyhan, Nezahat Gurler, Akgun Yaman, Candan Ozturk, Lutfiye Oksuz, et al. (2011) *Streptococcus pneumoniae* isolates from children with invasive pneumococcal disease in Turkey: baseline evaluation of the introduction of the pneumococcal conjugate vaccine nationwide. *Clin Vaccine Immunol* 18: 1028-1030.
39. Tamara Pilishvili (2020) Effects of Pneumococcal Conjugate Vaccine in the United Kingdom: Success of Vaccine Policy and Remaining Opportunities for Prevention. *The Journal of Infectious Diseases* 221: 1235-1237.
40. Balsells E, Guillot L, Nair H, Kyaw MH (2017) Serotype distribution of *Streptococcus pneumoniae* causing invasive disease in children in the post-PCV era: A systematic review and meta- analysis. *PLoS ONE* 12: e0177113.

**Copyright:** ©2020 Mohammed Elkhazendar. This is an open-access article distributed under the terms of the Creative Commons Attribution License, which permits unrestricted use, distribution, and reproduction in any medium, provided the original author and source are credited.