

## Pericentric Inversion of Chromosome 1 in a Child with Low Height: Diagnostic Dilemmas

Ada Paloma Soto Brambila<sup>1,2</sup>, Alejandro Marin-Medina<sup>2</sup>, Eduardo Esteban Zubero<sup>5</sup>, Sabrina Diaram<sup>4</sup>, Moises Alejandro Alatorre Jimenez<sup>3\*</sup>

<sup>1</sup>Laboratory of mitochondria-Oxidative Stress and Pathology, Neurosciences Division, Western Biomedical Research Center, The Mexican Social Security Institute. Wet Saw 800, C.P. 44340. Guadalajara, Jalisco, Mexico

<sup>2</sup>Doctorate Human Genetics, University of Guadalajara, Health Sciences Center, Center for Biomedical Research in the West, IMSS\*. Jalisco, Mexico

<sup>3</sup>Department of Pediatrics, SUNY Downstate, Brooklyn, NY, USA 11203

<sup>4</sup>Asociacion Mexicana de atrofia Muscular Espinal, Chapala 26, Col, Vallarta poniente, Guadalajara, Mexico, 44101

<sup>5</sup>Emergency Department, Hospital de San Pedro, Logroño, Spain, 26006

### \*Corresponding author

Moises Alejandro Alatorre Jiménez, Department of Pediatrics, SUNY Downstate, Brooklyn, NY, USA 11203 Tel: +1 (210) 9844376, E-mail: dr\_alatorre@hotmail.com

Submitted: 21 June 2018; Accepted: 26 June 2018; Published: 10 July 2018

### Abstract

*The inversions are one of the most common chromosomal abnormalities. They occur when two breaks occur in a chromosome; the segment as well originated is reversed and becomes the reintegration on the same chromosome. Generally, an inversion does not cause an abnormal phenotype in the carrier, but it can do so in their offspring. Which sometimes can be associated with cases of mental retardation, congenital malformations or infertility. It is critical to determine if the inversion has a family origin, where there usually is no risks for the individual, or if it is a de novo mutation, the risk is somewhat higher, possibly due to the interruption of a key sequence of the gene. The pericentric inversion of chromosome 1 is one of the structural chromosomal variations that are not common, and it has been observed in general population and patients with abnormal phenotypes and disease. We report the case of a child that came to the office for presenting a failure to thrive every year; the cytogenetic testing reported an inversion of chromosome 1 without maternal origin nor paternal. In this case, there is no evidence that low height has relation with the abnormal chromosome.*

**Keywords:** Pericentric Inversion, Short Stature, Psychomotor Retardation, Chromosome 1

### Introduction

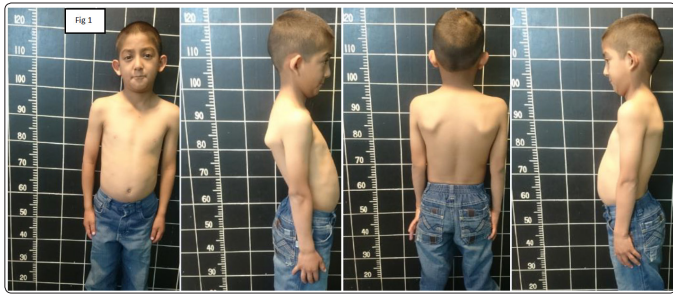Inversions (INV) are intrachromosomal structural rearrangements. Its incidence in the general population is 1/1.000 individuals [1]. They occur when there are two breakage points in the same chromosome; the segment can be reversed, rotated 180° and can become reintegrated on the same chromosome. If the inversion includes the centromere, is called a pericentric inversion, and paracentric if it does not include the centromere.

The rearrangement of the genetic material does not affect, in general, the function of genes; the breakage and reunion of most sites does not disturb the genome; therefore, the phenotype of the carriers is healthy, and the anomaly is considered to be a balanced rearrangement. Its true medical significance relates to the offspring: a carrier of any type of inversion runs the risk of producing abnormal

gametes due to an abnormal recombination or inactivation of genes by the rearrangement. Once fertilized, these gametes give origin to malformed individuals, with or without mental retardation, or reproductive loss [2,3]. The pathogenicity or not of an inversion is in direct relationship with the size of the segment inverted. When this comprises less than one-third of the total length of the chromosome, there is no abnormal recombination during meiosis, but it tends to occur when the size exceeds one-third of the length; the higher is the size, the higher the number of chiasmata and crosslinking (crossing over) [2,4]. The risk of having offspring not balanced in carriers of an inversion is of 1-10%. There are a number of inversions in the general population, called standard variants, and tend not to be related to an increased risk of birth defects and/or difficulties in development. The most common inversion observed in human chromosomes is a small pericentric inversion of chromosome 9, which is present in 1-3% of the general population [5-8]. A Mendelian form inherits it, or it may occur de novo. We report the case of a pericentric inversion of chromosome 1 de novo.

## Clinical Case

This paper presents the case of a 12 years old child, evaluated for psychomotor retardation, low height, hypothyroidism, retinitis and sensorineural hearing loss to 40% in both ears (Figure 1).



**Figure 1:** Shows the phenotype of the patient

## Personal history

During pregnancy, no adverse events occurred and was vaginally delivered at 39 weeks of gestation, with a weight of 3,250 g (p 25-50), a length of 51 cm (p 50-75), a circumference of 34 cm (P 25) and a Apgar score of 7/8. Being the first son of mother and father of 28 and 29 years of age, respectively, healthy and without a history of consanguinity or ingestion of toxic substances and medicines. In the anamnesis on family history, there is no history of miscarriages, birth defects or mental retardation.

## Evolution

Presents a progressive delay of growth development from the year of life, reaching its curve in weight and height at one year of age at the third percentile, with conservation of the head circumference at the 50th percentile. The rest of the physical examination is normal, without presenting dysmorphic features. It is not associated with other clinical symptoms, the neonatal period with hypotonia, and it had surgery for post-axial polydactyly. Weight of 48 Kg currently (Pc >80-90), height 1.25 m (Pc <50), with an expected adult height of 1.69 cm.

## Additional examinations

Normal echocardiogram, brain CT with cortical atrophy, with bone age according to its age, USG chord with bilateral renal ectasia, blood work, thyroid function, lipid profile and urine exam without alterations detected. Celiac disease was ruled out. The cytogenetic study carried out in the karyotype in peripheral blood shows that all 20 metaphases analyzed have 46 chromosomes, with sexual XY chromosomes. An inversion in a chromosome 1 was observed when tested by bands G, determines a 46, XY karyotype inv (1) (p12q21), the father and mother presents a normal karyotype 46, XY and 46, XX respectively.

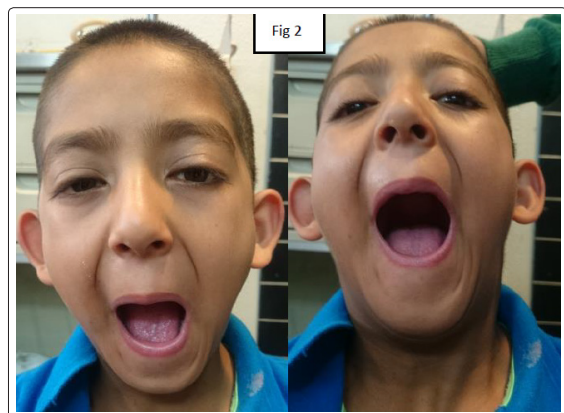
## Discussion

The inversion of the chromosome 1 is one of the rare balanced structural variations and found both in healthy populations as in patients with abnormal different phenotypes and disease.

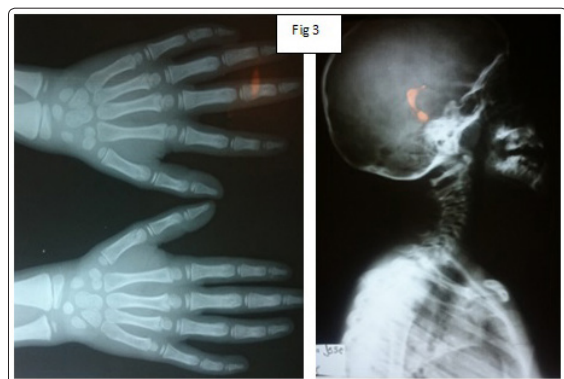
The incidence of inv (1) is not known and have been described various types of phenotypes of an heir of chromosome 1 inversion. The most common variants are the reversal of the heterochromatic region [4,5]. Constitutional inversions affecting the region of chromosome 1 pericentric breakpoints that are situated in 1Q12 or 1q13-21.1 and, less frequently, in 1Q12.

The investments, in general, most often appear as a family inherited chromosomal alterations, in which there is normally no risk of injury for the individual. There is a slightly higher risk if it is a de novo mutation, possibly due to the interruption of a key sequence of a gene. Although the bearer of an investment may be completely normal, has a slightly higher risk of producing an embryo with a chromosomal imbalance. This is due to the fact that one chromosome inversion hardly pairs with its normal counterpart during meiosis, which can produce gametes containing derivatives unbalanced chromosomal if an unequal cross. Despite being classified as a chromosome rearrangement of lesser importance, which does not correlate with abnormal phenotypes, many studies have raised conflicting views of the association of this investment with recurrent miscarriages, subfertility, clinical abnormalities and chromosomal disorders [9-11]. Among the anomalies associated with the inversion of chromosome 1 include the following: dysmorphic features (short stature, depressed nasal bridge, low set ears, and hypertelorism), microcephaly, deafness, ectodermal dysplasia (absence of sweating glands, hypotrichosis, hypodontia) (Figure 2.3), repeated miscarriages, infertility (absence of ovarian, uterine hypoplasia, oligospermia), mental retardation and developmental delay, psychiatric disorders (schizophrenia, autism), congenital cataracts, blindness, heart defects, and urogenital hydronephrosis [5-8].

At present, it has not been possible to relate no clinical sign specific or congenital anomaly with the bearers of this variant chromosomal abnormality.



**Figure 2:** Dysmorphic features are presented (short stature, depressed nasal bridge, low set ears, hypertelorism), microcephaly, deafness, hypodontia, mental retardation, and development delay.



**Figure 3:** There is a bone age according to the chronological order, without skeletal abnormalities, except for a slight kyphosis

---

## Conclusión

When a person has an inversion, there is an increased risk for offspring to have an incorrect amount of genetic material. This can lead to have children with birth defects and/or abnormal development or a higher percentage of abortions. The possible outcome of a pregnancy for an individual with an inversion is quite complicated and depends on how big it is, where it is located and what type of inversion it is. The clinical examination is not conclusive for diagnosis. Because of the risk of chromosomal abnormalities in the offspring, a chromosomal study should be offered to all direct relatives, in order to identify carriers of the inversions, and thus provide genetic counseling and, eventually, a prenatal diagnosis in case of pregnancy.

## References

1. Dinulos MB (1997) *HuBio 554 medical genetics. Clinical Cytogenetics (III)*. Washington: Fall.
2. Thompson M (1996) *Genetics in medicine, 4 th ed.* Barcelona: Masson 199.
3. Lindberg L, K, PELTO BORGSTRÖM GH (1992) Familial pericentric inversion (3) (p12q24). *Hum Genet* 89: 433-436.
4. Morel F, B, L'échangeur - Rue j. a. auxenfants Guerif D, et al. (2007) Meiotic segregation analysis in spermatozoa of pericentric inversion carriers using fluorescence in situ hybridization. *Hum Reprod* 22: 136-141.
5. Martinez M, Farini V, C, Perandones muhlmann m (2007) reproductive risk in patients with appointments of an heir: relevance of the evaluation and preconceptional and prenatal genetic counseling. *Bioanalysis* 18: 21-24.
6. Kaiser P (1988) The cytogenetics of mammalian autosomal rearrangements. In: Alan R, ed. *Pericentric inversions: their problems and clinical significance*. New York: Liss Inc 163-247.
7. Gardner RJM, Sultherland GR (1996) *Chromosome abnormalities and genetic counseling. Oxf Monogr Med Genet* 29: 139-152.
8. Anton E, White J, Egozcue J, Vidal F (2005) Sperm studies in investment heterozygote carriers: a review. *Cytogenet Genome Res* 111: 297-304.
9. Yong Jeong S, Young Kim B, Yu Jae E (2010) De novo pericentric inversion of chromosome 9 in congenital anomaly. *Yonsei Med J* 51: 775-778.
10. Martin MJ, abrisqueta ja (1983) Unusual pericentric inversion, inv(9)(p13q11) in a phenotypically normal family. *Human Genet* 64: 100.
11. Rivas Alpizar E, Rojas Quintana P, Reyes Pérez A (2005) pericentric inversion of chromosome 1. Presentation of a case Pericentric inversion of chromosome 1. A Case Report. *ISSN* 2221-2434.

**Copyright:** ©2018 Moises Alejandro Alatorre Jiménez, et al. This is an open-access article distributed under the terms of the Creative Commons Attribution License, which permits unrestricted use, distribution, and reproduction in any medium, provided the original author and source are credited.