

Pericapsular Nerve Block as Analgesic Method for Patients with Hip Fracture

Sofía Doria Castro^{1*}, Nixon Martin Burbano Erazo², María José Durango de la Ossa³, David Alejandro Henao Jordan⁴, Gabriel Andrés Torres Ayala⁵, Sandra Catalina Ramirez Palacio⁶, Juan Andrés Rojas Lesmes⁷, Eduardo Luis Pallares Cujia⁸, Yussef David Sakr Nassar⁹

¹Fourth Year Anesthesiology Resident, Universidad San Carlos de Guatemala

²General Physician, Universidad Tecnológica de Pereira, Colombia

³General Physician, Universidad del Sinú de Montería, Colombia

⁴General Physician, Fundación Universitaria San Martín, Cali, Colombia

⁵General Physician, Pontificia Universidad Javeriana, Bogotá, Colombia

⁶General Physician, Universidad Pontificia Bolivariana, Medellín, Colombia

⁷General Physician, Fundación Universitaria Juan N. Corpas, Bogotá, Colombia

⁸General Physician, Fundación Universitaria San Martín, Bogotá, Colombia

⁹General Physician, Universidad del Sinú, Colombia

*Corresponding author

Sofía Doria Castro, Fourth Year Anesthesiology Resident, Universidad San Carlos de Guatemala, Colombia

Submitted: 14 Nov 2021; Accepted: 24 Nov 2021; Published: 18 Jan 2022

Citation: Sofía Doria Castro, Nixon Martin Burbano Erazo, María José Durango de la Ossa, David Alejandro Henao Jordan, Gabriel Andrés Torres Ayala, Sandra Catalina Ramirez Palacio, Juan Andrés Rojas Lesmes, Eduardo Luis Pallares Cujia, Yussef David Sakr Nassar. (2022). Pericapsular Nerve Block as Analgesic Method for Patients with Hip Fracture. *J Anesth Pain Med* 7(1): 11-16.

Abstract

Today we are facing the time of the opioid crisis, in which pain management, in the different areas of study, has become more and more complicated for health personnel. Patients with hip fracture, who among their main population at risk are the elderly, require greater safety and greater pain control time. New analgesic techniques have been under development, including a recent one by which the nerves of the pericapsular group or PENG block are blocked, specifically of the anterior capsule of the hip joint, mainly sensitive nerves with little motor involvement. This technique varies slightly in its method of performance and in the anesthetic used according to current reviews. Because it is novel, the largest amount of information found in the literature comes from reports and case reports or letters to the editor; therefore, it is not yet possible to extrapolate the results to a general population, but knowledge of these studies will allow progress in the comprehensive management of these patients.

Key Words: Hip Fracture, Analgesia, Hip Pain, Peng Block.

Introduction

The 3-in-1 block and femoral block are one of the most commonly used methods for analgesic management in patients with hip fractures, but as it does not block the obturator nerve, since it is at a higher level than that achieved by these methods, it may not provide sufficient analgesia in such patients. Since 2018, Giron et al described a new method based on the knowledge of the sensory innervation of the anterior capsule of the hip, which includes the deposit of local anesthetic in the fascial muscle plane between the psoas muscle and the iliopubic eminence, with results satisfactory clinical trials in the 5 patients in their study. Since then, different reports and case reports have been published that support the findings found by Giron, et al. This procedure can be useful throughout the patient's perioperative period. In this article, a short review will be made of the different reviews of the cases and their conclusions regarding the subject.

Methodology

A systematic bibliographic search of the updated medical literature on PENG block and its relationship with analgesic management in patients with hip fracture was carried out, using databases such as: Pubmed, Science direct, Google Scholar and EMBASE until November 5, 2021. Descriptors such as PENG block, analgesic management in hip fractures, PENG block and hip fractures were used. Review articles were used as originals regardless of their year of publication.

Results

In the elderly population, due to lower bone density and multiple underlying diseases, one of the most common orthopedic emergencies is hip fracture, which is also associated with high morbidity and mortality [1, 5].

For pain management, the most commonly used methods are opioid-type systemic analgesics that, among others, increase the incidence of side effects such as nausea, vomiting, sedation and constipation, which is directly reflected in longer hospital stays or late discharges [1].

During this time, the opioid crisis is more solid, which has evidenced the need for new analgesic techniques that provide greater safety and more time for pain control, including perioperative pain [9].

Sensory innervation of the anterior capsule of the hip, first described in 1948 by Gardner, is provided by the obturator nerve, accessory obturator nerve, and proximal branches of the femoral nerve [3]. Publications of recent anatomical descriptions have revealed landmarks to access these nerves through ultrasound-guided procedures, such as the anterior-inferior iliac spine and the il-

ioipubic eminence that reach the femoral and obturator accessory nerve and the inferior medial acetabulum that reach the obturator nerve [9, 4].

The PENG (pericapsular nerve group) block is a new ultrasound-guided analgesic technique, first described at the end of 2018 by Giron-Arango et al [1, 5]. Through this, analgesia is provided through a regional block in the anterior capsule of the hip joint, with little involvement of motor innervation, which has proven to be a better option than the 3-in-1 block, femoral block and block of the iliac fascia as traditional methods in analgesic management in patients with pathologies related to said anatomical site since the latter do not block the obturator nerve [1]. Currently, it has been considered that this anesthetic technique could not only be indicated in hip fractures but also to reduce procedure-related hip pain, in vaso-occlusive crises due to sickle cell anemia and in osteoarthritis and even for interventions not associated with the hip [10].

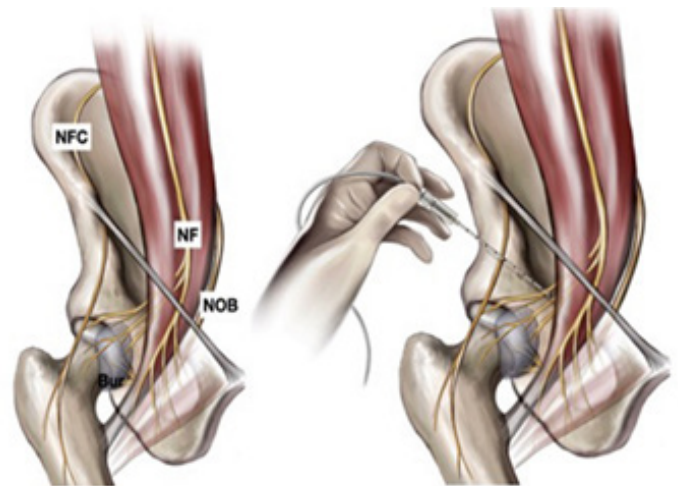


Figure 1. Left: anatomy of the innervation of the hip joint. Right: Approach to the PENG block from lateral to medial

To perform the block, patients are placed supine and a pillow or blanket under the ipsilateral knee may be used for support to provide slight hip flexion and decrease tension on the iliopsoas muscles [1, 9]. In some descriptions, the convex ultrasound probe (low frequency) is used for patients over 70 kg and linear probe (high frequency) for patients under 70 kg [1,13]. The bone mark of the anterior superior iliac spine (ASIS) is located and the probe is placed in a longitudinal plane over it and aligned with the pubic branch by rotating the probe 45 ° to observe the iliopubic eminence in the depth, the psoas muscle with its tendon in proximity to the iliopubic eminence, the most superficial and medial femoral artery and vein [9, 11-13].

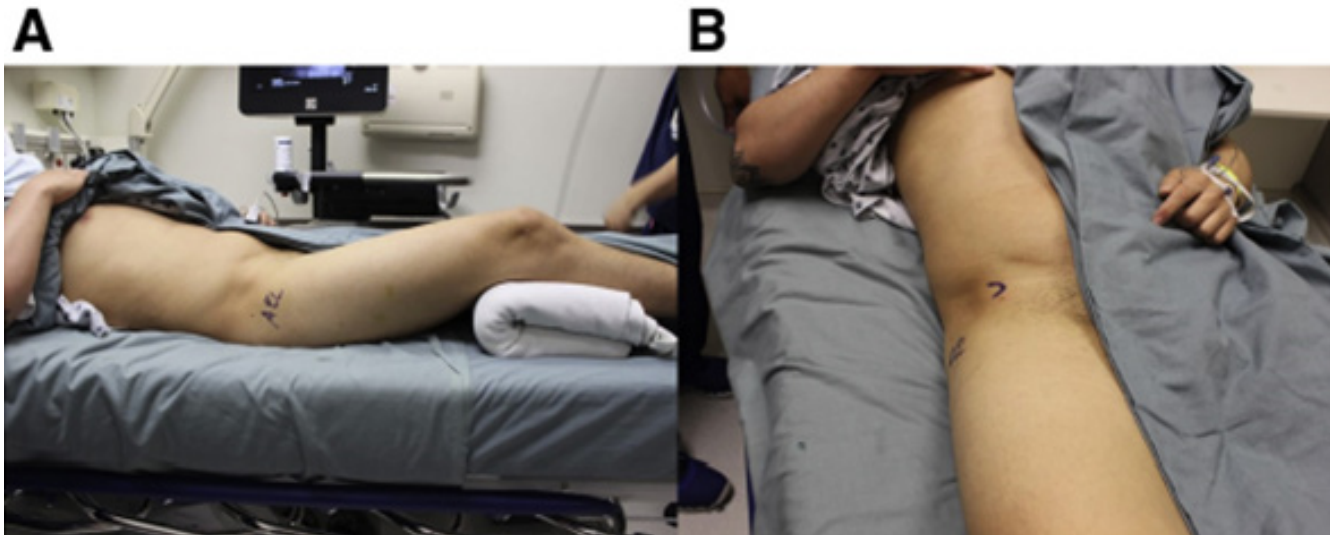


Figure 2: A. Position of the patient to perform the PENG block. B. The ESIA is searched, palpated, and marked as a reference to perform the procedure.

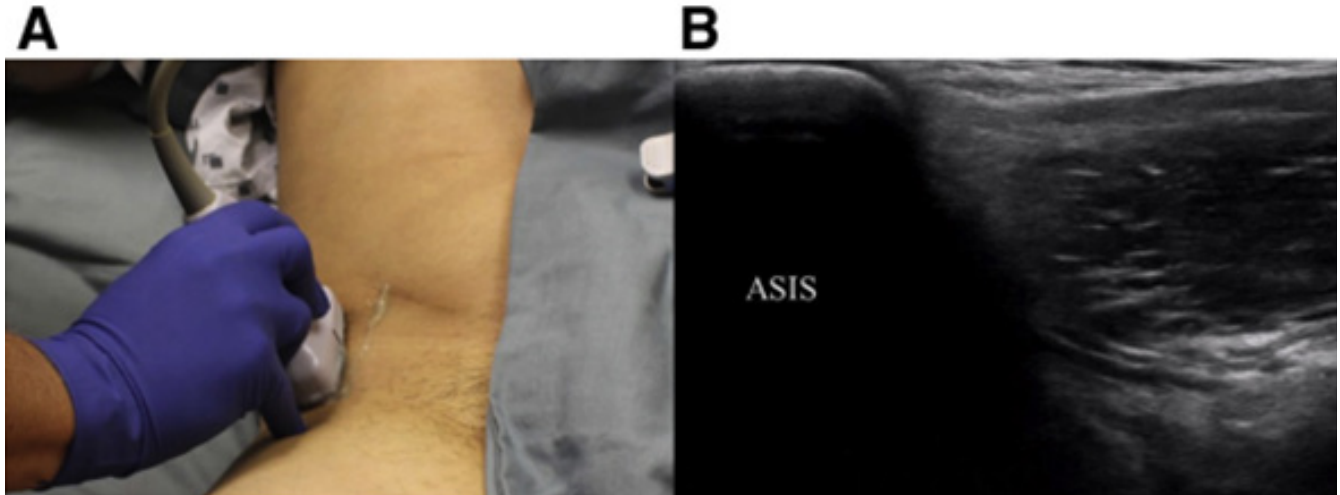


Figure 3 A. Placement of the probe longitudinally on the ESIA in the previously made mark. B. Ultrasound view of the upper pole of the ASE probe.

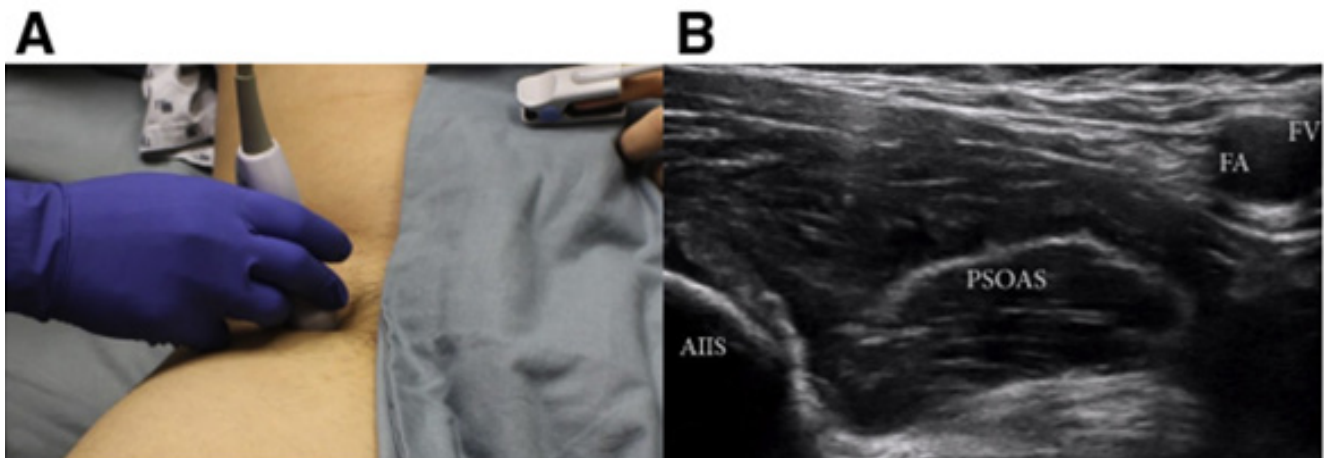


Figure 4. Position to perform the PENG lock. A. Probe aligned with the superior pubic ramus. B. Ultrasound view where key anatomical structures are labeled: Inferior Anterior Iliac Spine (AIIS), Femoral Artery (FA), Femoral Vein (FV), Psoas Muscle Tendon (PSOAS).

The needle (100mm, 22G // 80mm, 20G; according to the literature reviewed) is inserted at an angle of 45 ° to 60 ° to place the tip in the musculofascial plane between the psoas in the anterior part and the pubic branch in the posterior (this point may vary according to the literature and according to the operator's expertise; the complete review of the procedure is not the objective of this article), then a negative aspiration is performed and the anesthetic is

injected while the adequate elevation is observed in the image and the dispersion of the liquid [1-2, 9, 11-13]. The type and quantity of anesthetic used will be independent of the method used, in the current literature there are cases with a single injection of ropivacaine 0.5% and 4mg of dexamethasone at 20cc and others with lidocaine 1% with epinephrine and bupivacaine 0.25% at 30cc total [1, 6, 9, 13].

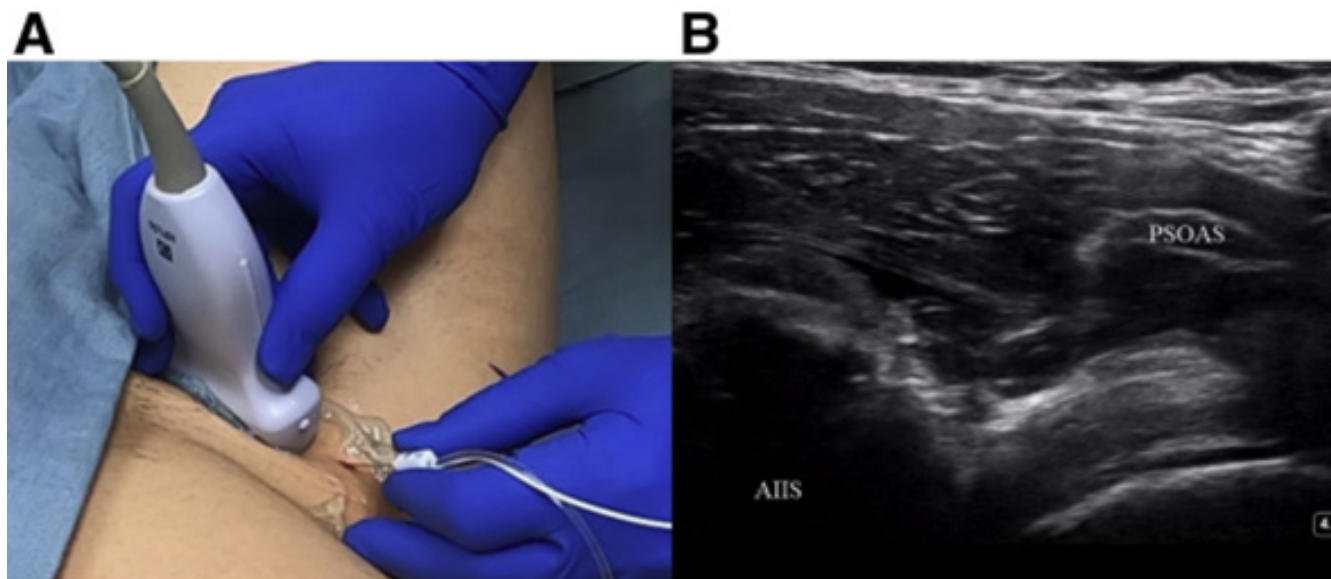


Figure 5. Position of the needle for the PENG block. A. With the probe aligned, the needle is inserted at a 50 ° angle from lateral to medial. B. View of the ultrasound after the injection of the anesthetic, demonstrating the increase in fluid under the psoas tendon.

Some disadvantages associated with the method have been described as not reaching the lateral femoral cutaneous nerve that provides analgesia in the lateral region of the thigh and it is there where the entrance incisions are made for the surgical approach in patients with hip fracture [1].

Discussion

Giron-Arango et al, in 2018, published an innovative pericapsular nerve group block technique for the analgesic management of patients with hip fracture. In their article, they describe the procedure and its effectiveness in 5 patients with hip fracture 30 minutes after the procedure, and in which all reported significant decrease in pain through clinical scales and additionally, they did not have quadriceps weakness as one of the the expected complications to the process [5, 8].

Since then, the PENG block has been considered a new anesthetic technique that has been under development, initially used for analgesic management in patients with hip fractures but which has currently expanded its indications, although most of the medical literature comes from case reports and letters to the editor [2, 13].

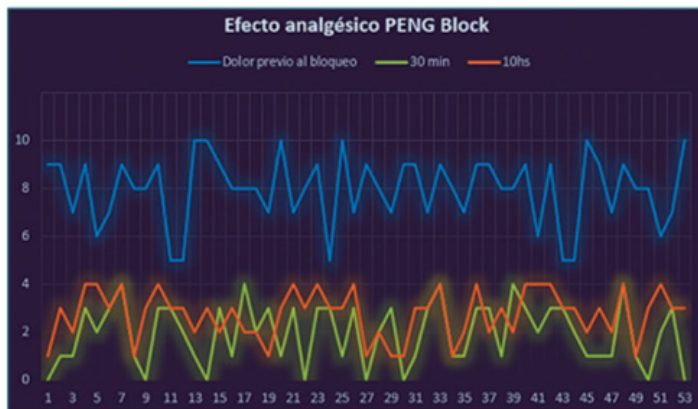
A scoping review published in 2020, by Morrison et al, reaffirms that the largest amount of current information on analgesia and anesthesia through PENG block in hip fractures and surgeries comes

from reports and case series, within which, all, it is described that such a procedure provides sufficient analgesia or anesthesia and that its transient secondary motor side effects occur when the local anesthetic is deposited in an unwanted location [7].

In 11 case reports, the use of PENG block as the sole technique for the management of pathologies related to the hip (fractures, dislocations, surgeries) has been effective in providing analgesia with the reduction or no additional use of oral or intravenous analgesics [7]. On the other hand, another 9 studies that include both adults and children, describe that the use of the PENG block in combination with local anesthetic infiltration or block of other nerves (such as the femoral nerve or lateral femoral cutaneous nerve) also provides sufficient analgesia with necessity minimal or no opioid requirement after 72 postoperative hours (arthroplasty, arthroscopy or hip fracture surgeries) [7].

A descriptive observational study carried out between May and November 2019 in a Hospital in Argentina, with a total of 53 patients, highlighted the benefit of the use of the PENG block as a perioperative strategy in patients with hip fracture by directly affecting the subjectivity of pain (evaluated by the Visual Analog Scale - VAS) with improvement in this parameter in all patients at 30 minutes and up to 10 hours after the procedure. The authors conclude that the PENG block provides very good analgesia and

can be used both preoperatively, during patient transfer, and postoperatively, thereby directly reducing opioid use and hospital stay [1]. (Figure 1)



Graph 1. Analgesic effect of the PENG blockade demonstrated in the study by Molinelli, et al.

Morrison et al, also report up to 10 studies that show differences in the technique used for PENG block, such as the use of curvilinear or linear probes. Another 19 studies with the use of a single dose of analgesics during the procedure and 1 only with a catheter for continuous infusion of local anesthetic. None of the above required greater analgesia 72 hours after surgical procedures [7].

Of the most commonly reported complications resulting from the procedure include infection, bleeding, neuropathies, and systemic toxicity due to the volume and delivery of anesthetic. Quadriceps muscle weakness can occur secondary to femoral nerve block [6, 13]. Due to the recent nature of the subject, there is no more information on the side effects of the procedure in the literature, which is a point to be addressed in future studies.

Conclusion

The publications on the subject in question have been quite emphatic on the efficacy and usefulness of the PENG block as an analgesic management in patients, not only with hip fractures but also for use in pathologies involving said joint. As it is a recently appearing method, it requires studies with larger cohorts that allow the experience of small population groups to be scaled to a recommendation for generalized use due to the lack of evidence or existing controversy on points such as quantity, concentration or anesthetic ideal to use, precise indications and contraindications. Even so, with what is known, we could anticipate the fact that this novel method, in the near future, will allow a new vision in the control of pain in patients and even, if it could be thought, apply its principles in different parts of the body economy [14-20].

References

1. Molinelli M, Romero J, Uranga S, Josefina Bartolini, Nicolás Caputo, et al. (2020) Efecto analgésico del bloqueo PENG (grupo de nervios pericapsulares) en pacientes con fractura de cadera. *Rev Chil Anest* 49: 141-145.

2. Del Buono R, Padua E, Pascarella G, Fabio Costa, Gaetano Terranova, et al. (2021) Pericapsular nerve group block: an overview. *Minerva Anestesiologica* 87: 458-466.
3. Garner M, Alshameeri Z, Sardesai A, Khanduja V (2017) A prospective randomized controlled trial comparing the efficacy of fascia iliaca compartment block versus local anesthetic infiltration after hip arthroscopic surgery. *Arthroscopy* 33: 125-132.
4. Short AJ, Barnett JJG, Gofeld M, Ehtesham Baig, Karen Lam, et al. (2018) Anatomic study of innervation of the anterior hip capsule: Implication for image-guided intervention. *Reg Anesth Pain Med* 43: 186-192.
5. Girón-Arango L, WH Peng P, Chin K, Richard Brull, Anahi Perlas, et al. (2018) Pericapsular Nerve Group (PENG) Block for Hip Fracture. *Regional Anesthesia and Pain Medicine* 43: 859-863.
6. Berlioz B, Bojaxhi E (2021) PENG Regional Block. *Stat-Pearls – NCBI* 2021.
7. Morrison C, Brown B, Lin D (2020) Analgesia and anesthesia using the pericapsular nerve group block in hip surgery and hip fracture: a scoping review. *Reg Anesth Pain Med* 46: 169-175.
8. Acharya U, Lamsal R (2020) Pericapsular Nerve Group Block: An Excellent Option for Analgesia for Positional Pain in Hip Fractures. *Case Reports in Anesthesiology*. 2020: 1830136.
9. Fericola SD, Tannehill J, Tucker C, W Robert Volk MD, Jonathan F, et al. (2021) The Pericapsular Nerve Group Block for Perioperative Pain Management for Hip Arthroscopy. *Arthroscopy Techniques* 10: 1799-1803.
10. Wyatt KE, Pranav H, Henery T, Joyce Liu C (2020) Pericapsular nerve group blockade for sickle cell disease vaso-occlusive crisis. *Journal of Clinical Anesthesia* 66: 109932.
11. Zaragoza Lemus G, Portela Ortiz JM, Díaz-Guevara G (2020) Bloqueo del grupo de nervios pericapsulares (PENG) para cirugía de cadera. *Revista Mexicana de Anestesiología*, 43: 69-72.
12. Mancera Rangel M, Hernández Rodríguez D, Céspedes Korrodi MÁ, Zaragoza Lemus G (2021) Colocación de catéter ecoguiado para bloqueo PENG continuo en Cirugía de Cadera. *Revista Mexicana de Anestesiología* 44: 233-236.
13. Reza PC, Vázquez MG, Álvarez SL (2021) Nuevos bloqueos capsulares ecoguiados para cirugía de cadera: una revisión narrativa. *Revista Española de Anestesiología y Reanimación* 2021.
14. Del Buono R, Padua E, Pascarella G, Corina Gabriela Soare, Enrico Barbara, et al. (2020) Continuous PENG block for hip fracture: a case series. *Reg Anesth Pain Med* 45: 835-838.
15. Azogue Sempertegui, MARIA ALEJANDRA (2020) Bloqueo PENG vs bloqueo de fascia iliaca como analgesia postoperatoria en pacientes adultos sometidos a cirugías de cadera: ensayo clínico.
16. Nieves De La Torre, PF (2021) Bloqueo continuo del grupo nervioso pericapsular para analgesia de fracturas de cadera. *Repositorio Institucional Universidad de Antioquia* <http://hdl.>

handle.net/10495/20275.

17. Kukreja P, Avila A, Northern T, Dangle J, Kolli S (2020) A Retrospective Case Series of Pericapsular Nerve Group (PENG) Block for Primary Versus Revision Total Hip Arthroplasty Analgesia. *Cureus* 12: 8200.
18. Prado Kittel C, Zumelzu Sánchez P, Palma Licandeo A, Faúndez Lillo G, Ellenberg Oyarce K et al. (2020) Continuous pericapsular nerve group blockade as analgesia for fracture of the posterior column and wall of the acetabulum; a case report and description of infusion regimen for extending analgesic effect to the distal femoral area. *Revista Española de Anestesiología y Reanimación (English Edition)* 67: 159-162.
19. BravoMD D, AlisteMD J, LayeraMD S, JaraMD Á (2020) Bloqueos de extremidad inferior. *Rev Chil Anest*, 49: 28-46.
20. Guay J, y Kopp S (2020) Bloqueos de nervios periféricos para fracturas de cadera en adultos. *Base de datos Cochrane de revisiones sistemáticas* 2020.

Copyright: ©2022 Sofía Doria Castro, et al. This is an open-access article distributed under the terms of the Creative Commons Attribution License, which permits unrestricted use, distribution, and reproduction in any medium, provided the original author and source are credited.