

Outcome of Unstable Pertrochanteric Fractures in High-Risk Geriatric Treated with External Fixators

Yu Liang*, Shaojing Liu and Fenglin Zhong

Department of Orthopaedics, Panzhihua Municipal Central Hospital, Sichuan, China

*Corresponding author

Yu Liang, MD, Department of Orthopaedics, Panzhihua Municipal Central Hospital, Panzhihua, No. 34 on the Street of Yi kang, East Area of Panzhihua City, Province Sichuan, China

Submitted: 06 May 2021; Accepted: 14 May 2021; Published: 17 May 2021

Citation: Yu Liang, Shaojing Liu and Fenglin Zhong (2021) Outcome of Unstable Pertrochanteric Fractures in High-Risk Geriatric Treated with External Fixators. *Int J Ortho Res*, 4(2): 46-52.

Abstract

Background: To review the outcome of high-risk geriatrics with unstable pertrochanteric fractures treated with external fixator. **Methods:** Eighteen consecutive patients with pertrochanteric fractures were operated with external fixator by using closed reduction technique. AO type, accompanying diseases, operating time, transfused blood units, duration of hospitalization, complications, healing time and mortality were recorded. Patients were followed clinically and radiologically for two years at least. The Harris Hip Score was used to document hip function at each regular follow-up.

Results: Fifteen patients with average age of 71.5 years were available for final evaluation. The mean operating time was 41.1 min and union was achieved in all cases with an average time of 16 weeks. The mean Harris Hip Score at one, three, six, twelve and twenty-four months postoperatively was 42.07 ± 8.55 ; 55.07 ± 11.62 ; 70.07 ± 10.32 ; 86.27 ± 9.06 and 89.27 ± 8.81 respectively. Complications included all the patients undergoing loss of some motion in the knee and four of them had to experience revision surgery because of knee stiffness, ten cases of pin-tract infections, seven cases of deep venous thrombosis, two cases of migration of the screws and two cases limb shortening

Conclusions: The use of external fixator in high-risk geriatric provided a satisfactory long term efficacy, but the short term functional results were quite unsatisfactory owing to high complication rate. Therefore, the advantages and disadvantages should be fully weighed when using external fixators, which was especially suitable for those patients who could not tolerate prolonged operative time and open surgery.

Key words: Outcome, Pertrochanteric fractures, Geriatric, External fixator.

Introduction

Pertrochanteric fractures are one of the most common fracture types in the elderly and are associated with a high risk of mortality and functional disability. Surgery is usually indicated, bringing about pain relief, early weight-bearing, and an early return to the preinjury functional level [1-3]. However, over time, in patients 65 years or older associated with hip fracture have had an increase in comorbidities, moreover, the increase of preexisting medical conditions were highly significant factors correlated with patient mortality [4-6]. Therefore, the management of hip fracture for serious medical conditions remains challenging.

Some authors put forward that external fixation techniques, es-

pecially for high-risk elderly patients, which fully adheres to the concept of minimally invasive surgery, its biomechanical features are attractive, fixation is rapid, surgical reduction is maintained and postoperative complications have been minimal [7, 8]. Nevertheless, compared to subcapital fractures the pertrochanteric ones are observed in older ages whose life expectancy is decreased and even lower or no walking expectancy, the long-term functional outcome of unstable pertrochanteric fractures for geriatric treated with external fixators has been rarely reported, the purpose of this study is to review our experience with the use of external fixation for unstable pertrochanteric fractures, and to assess patient satisfaction using generic outcome instruments [1, 9].

Materials and Methods

This study had been approved by the Institutional Review Board of the authors' affiliated institutions and informed consent was obtained from participants to be included in the study. We retrospectively reviewed medical records for geriatric patients undergoing pertrochanteric fracture and treated with external fixation during January 2013 to December 2017. Inclusion criteria included age above 60 years, unstable pertrochanteric fracture, and American Society of Anesthesiologists (ASA) grades III or IV [10]. In a word, the indications for using the external fixator were severe fracture involved with the proximal femur where traditional methods of open reduction and internal fixation were deemed unsuitable. Exclusion criteria included dementia, hemiplegic paralysis, severe osteoarthritis, open fractures, neurological and psychiatric disorders that would hamper assessment, pathological fracture and previous hip fracture. Eighteen patients with unstable fractures according to the Orthopaedic Trauma Association classification system (Types A2.2, A2.3, A3.1, A.3.2, and A.3.3) were treated, in which two part fractures with comminution of the posteromedial cortex, subtrochanteric extension, or a reverse obliquity pattern were considered unstable [11, 12].

All operations were implemented under epidural anesthesia, the patients were positioned on a fracture table in the supine position with the contralateral limb widely abducted. The fracture was reduced by applying traction and internal rotation to the injured limb in a position of slight abduction. When fracture reduction is achieved, no further traction is applied and care must be taken not to change the limb position throughout the remainder of the procedure. Fracture reduction must be checked with fluoroscopy-both anteroposterior and lateral views. Two guidewires were placed on the front of hip joint, which were respectively proved to locate in top one-third and bottom one-third of the femoral neck and head under anteroposterior fluoroscopy. Furthermore, two long, self-tapping, and hydroxyapatite coated 6.5 mm Schanz screws were inserted first in a parallel to either one of the guidewires under lateral fluoroscopy and advanced to within 10 mm from the subchondral bone of the head. Attention was paid to ensure that the tip of the schanz pin was at least 5 mm far from the articular surface to prevent penetration. Then, a unilateral, external fixator frame with uncoated stainless steel pins, which attached to the proximal pins, acted as a template for the introduction of the two distal pins, the two distal screws were inserted perpendicular to the long axis of the proximal femoral shaft and were implanted to a depth of two screw threads beyond the opposite bone cortex. The duration of surgery was determined as starting at the time of skin incision and ending when the final pin was secured to the fixator frame.

Postoperatively, all patients underwent a progressive physiotherapy measures, mobilization of the knee and ankle was encouraged 6 to 12 hours after surgery, as tolerated, sitting on bed or on a chair on the first postoperative day, and active hip movements were also started under the supervision and guidance of physiotherapists. Pin sites were cleaned daily with povidone iodine and a family member was instructed how to take care of the surgical wound after discharge.

The patients were scheduled to be followed up clinically and radiologically at 1,3,6,12, 24 months. Radiologic examination included anteroposterior and oblique views of the operated hip. Union was defined by the presence of trabeculae bridging the fracture site or obvious periosteal callus within the fracture line, then, the patients were allowed to fully weight bearing without any facility, if the fracture site was not displaced after continuous walking for two weeks, the external fixator was totally removed in our outpatient clinic. A fracture was determined to have a nonunion when no bridging callus formation was visible on both frontal and lateral hip radiographs after a minimum period of 15 weeks.

Besides, the quality of fracture reduction, as shown by the immediate postoperative radiographs, was evaluated according to the classification described by Baumgaertner et al. [13]. The reduction was considered good when normal or slight valgus alignment was evident on the anteroposterior radiograph, less than 20° of angulation on the lateral radiograph, and no more than 4 mm of displacement of any fragment. An acceptable reduction was characterized by a reduction that met the criterion of a good reduction with respect to either alignment or displacement, but not both. Finally, a poor reduction did not meet any of the above criteria.

In a word, accompanying diseases, operating time, transfused blood units, duration of hospitalization, complications, healing time and mortality were recorded at final follow-up. The Harris hip score was adopted to assess patient-activity status, any residual pain, claudication, and hip mobility [14], the explanation of outcome using the Harris hip score was as follows: <70 (poor result), 70–79 (fair result), 80–89 (good result) and >90 (excellent result), Paired t-test was used to evaluate for statistically significant difference in the change of HHS from one to three months postoperatively, from three to six months postoperatively, from six to twelve months postoperatively and from twelve to twenty-four months postoperatively. The level of significance was set at 5%.

Result Clinical Results

This prospective cohort study consisted of 18 consecutive patients who were treated with the Orthofix pertrochanteric external fixator from January 2013 to December 2017, three patients were lost to follow up due to mortality and remote rural areas and finally functional outcome data at one, three, six, twelve and twenty-four months after the surgical intervention was available for 15 patients.

Eight were men and seven were women with average age 71.5 (60–88) years (Table 1). All the patients were suffering from one or more accompanying diseases (Table 1). The distribution of the fractures according to the A.O. Classification is presented in Table 1. The first post-operative day, 80% of the patients sat on a chair or the edge of a bed, and 33.3% walked on the second day with the help of the medical staff. Mean duration of operation was 41 (30–60) min. Hemoglobin less than 9 g/dL was observed, at least once during the hospitalization period, in 86.7% of the patients (13 patients), the treatment of 11 of the patients did not necessitate any blood transfusion, for the remaining 4 patients were needed. Finally, all patients healed well, the average time to union was 16 weeks (range, 14–20 weeks),

Table 1: Demographic data and concomitant disease of all patients in the study

Case	Age/sex	Mechanism	A.O.Classification	Concomitant Diseases	ASA grade	Surgery Time(min)	Time to Union(weeks)	Complications	Final HHS
1	74/M	Fall	A2.2	IC, AF, PAH	IV	55	16	Pin-site infection (PSI)	86
2	63/F	PC	A2.2	Traumatic brain injury	IV	36	14	DVP, PE, knee stiffness	96
3	66/F	Fall	A2.2	Liver cirrhosis	III	30	14	PSI	90
4	72/M	PC	A2.3	Traumatic brain injury	IV	42	17	DVP	94
5	77/M	PC	A3.3	COPD; pressure sores	III	38	20	PSI, DVP	79
6	68/M	Fall	A3.1	Severe pneumonia (SP)	IV	40	14	Nil	97
7	88/F	Fall	A3.2	SP; pressure sores	IV	47	18	DVP, PSI, limb shortening	68
8	74/M	Fall	A3.3	CHD; hypertension	III	34	17	PSI	88
9	73/F	Fall	A3.1	Pulmonary heart disease	IV	36	16	Migration of screw	82
10	71/M	PM	A3.2	CHD; hypertension	III	44	15	DVP, PE, PSI, knee stiffness	94
11	81/F	Fall	A3.2	SP; pressure sores	IV	60	18	PSI, limb shortening	80
12	60/M	PC	A2.3	Traumatic brain injury	IV	33	14	DVP, PE, knee stiffness	100
13	62/M	PC	A3.1	Liver contusion	IV	44	15	DVP, PE, PSI, knee stiffness	96
14	71/F	Fall	A2.3	Diabetes, CRF	III	38	17	PSI, migration of screw	92
15	70/F	Fall	A2.2	Diabetes, CRF	III	40	16	PSI	97

HHS: Harris hip score; PC: Pedestrian vs car; PM: Pedestrian vs motorbicycle; IC: ischemic cardiomyopathy; AF: atrial fibrillation; COPD: chronic obstructive pulmonary disease; CHD: coronary heart disease; PAH: pulmonary arterial hypertension; CRF: chronic renal failure; DVP: deep venous thrombosis; PE: pulmonary embolism;

Surprisingly, loss of some motion in the knee occurred in fifteen patients as pain in the entrance of the screws when the mobilization of the knee joint was encouraged, and its extent depended mostly on the severity of the pain, which led to many patients could not wear shoes and socks by themselves due to squatting on toes could not be accomplished in their daily life. An average

of 60 degrees of range of motion of the knee was lost in these fifteen patients at one month after surgery. At one-year follow-up, four patients had to be operated again for knee stiffness while the remaining still lost some motion of knee joint and further surgical interventions were not required.

Ten pin-tract infections, most of which resolved with local care and antibiotics, only one patient pin-tract problems necessitated removal of the apparatus sooner than desired, and a brace was substituted. Finally, the fracture healed with an acceptable position after removal of the external fixator at three months, manipulation was carried out and then a walking brace was worn for an additional four weeks.

The most serious complications were deep venous thrombosis that affected 7 patients. 4 patients were transferred to orthopedics from neurosurgery at least five days after vehicle accident, who were all associated with closed head trauma at the time of accident, when preoperative preparation was administered, deep vein thrombosis were founded in these patients and three of them presented with pulmonary embolism. Another one with a sever pneumonia was admitted three days after fall from stand because consensus was not achieved among family member at that moment, similarly, deep vein thrombosis was discovered on admission. The others were detected as complaining continuous pain of the calf after discharge from hospital.

In two cases, migration of the screws further into the femoral head was observed at the follow-up X-rays and in one of them the screws penetrated into the joint space. These cases were treated with withdrawal of the screws and controlled loading of the affected limb until the fracture union and the subsequent removal of the screws.

Radiological Results

The quality of the final reduction was rated as good in 60% of patients (9 patients), acceptable in 27% (four patients), and poor in 13% (two patients). This result was mainly attributed to an increased incidence of varus position of the fracture (greater than 10°) in these unstable fractures of patients (Figure 1). Besides, slight convergence of the proximal screws was noticed in 33% of patients.

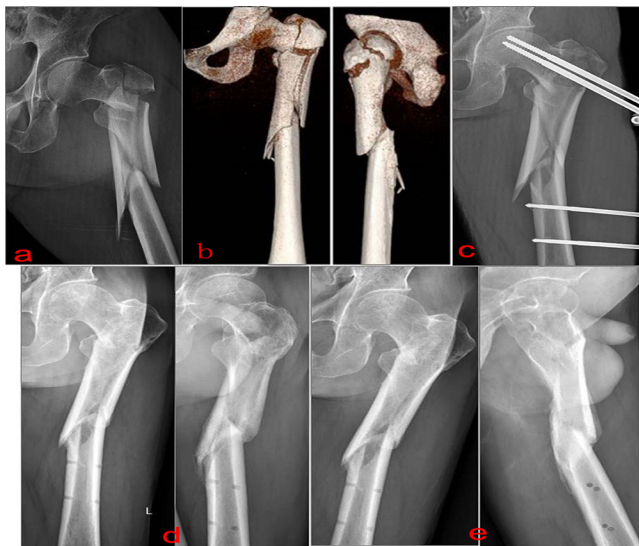

Figure 1: A 77-year-old male, AO type 31 A3.3. a. Preoperative anteroposterior X-ray; b. Preoperative 3-D CT scan; c. Immediate postoperative anteroposterior X-Ray; d.6 months post-operative anteroposterior and oblique X-ray, patient full weight bearing;

e.12 months post-operative anteroposterior and lateral X-ray, the quality of the final reduction was rated as poor.

Functional Outcomes

The mean HHS at one, three, six, twelve and twenty-four months postoperatively was 42.07 ± 8.55 ; 55.07 ± 11.62 ; 70.07 ± 10.32 ; 86.27 ± 9.06 and 89.27 ± 8.81 respectively. Paired t-test showed that the progressive improvement in HHS from one to twenty-four months postoperatively was significant ($p=0.000$, 95% CI: 8.3 to 17.7; $p = 0.000$, 95% CI: 10.7 to 19.3, $p = 0.000$, 95% CI: 12.9 to 19.5; $p = 0.002$,95% CI: 1.3 to 4.7; respectively). At twenty-four months postoperatively, excellent, good, fair and poor outcome was seen in 9 patients, 4 patients, 1 patient and 1 patient respectively. Figure 2 showed the trend in the improvement of HHS and Figure 3 displayed the variation tendency of each item of HHS postoperatively during the follow-up period. Of the fifteen pertrochanteric fractures, one patient (Case 7) got the worst HHS 68 and another one patients gained the best HHS 100 (Case 12) at final follow-up.

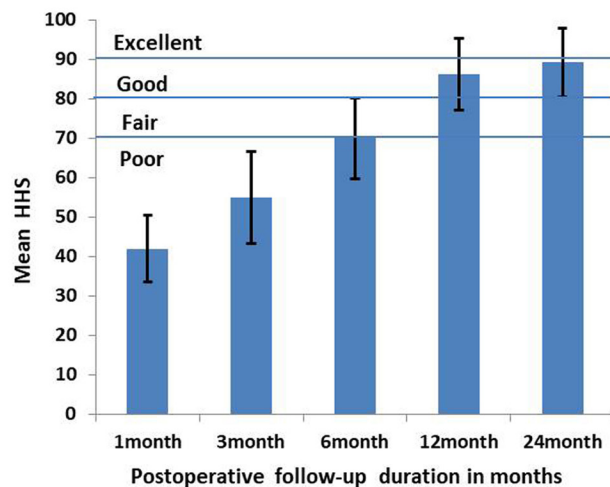


Figure 2: The explanation of outcome using the Harris hip score was as follows: < 70 (poor result), 70–79 (fair result), 80–89 (good result) and > 90 (excellent result).

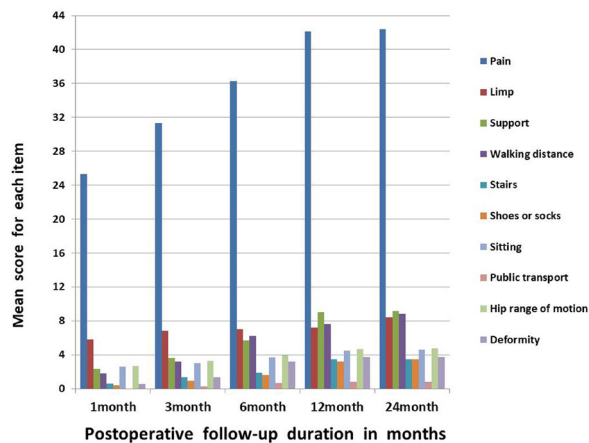


Figure 3: The trends of each item of the Harris hip score during the follow-up period.

Discussion

It is widely accepted that the treatment of pertrochanteric fractures in high-risk geriatric is to offer rigid fixation at fracture site allowing early mobilization as soon as possible so as to reduce morbidity and mortality. As pertrochanteric fractures are mainly emerged in elderly patients where the rate of the accompanying diseases is added [1, 9]. Therefore, the surgeon has to choose a method that its application will be fast, with a simple preoperative planning, which should be as minimally invasive as possible, with minimal blood loss and one that ensures the rapid mobilization of the patient and his/her discharge from hospital. The final result of this decision will be the decrease of postoperative complications and deaths and the assurance of an as early as possible return of the elderly patients to the walking condition they had before the fracture with the least medical expense. The external fixation meets these requirements [1, 15].

Though intramedullary nailing has also been the most commonly used procedure to treat unstable pertrochanteric fractures as its biomechanically and biologically property is superior to extra medullary implants, but it has its own set of technical difficulties and complications [16-20]. Firstly, anatomic reduction was the primary goal for pertrochanteric fractures since no anatomical reduction inevitably leads to intramedullary nailing implant malpositioning, and which was closely related with mechanical failure of internal fixation of extracapsular proximal femoral fracture in this fragile population, hence, prolonged operative time was needed in order to achieve anatomical reduction, on the contrary, to some extent malreduction was acceptable when external fixator was applied, especially for these elderly patients have associated medical problems of hypertension, diabetes mellitus, ischaemic heart disease and poor general condition labelling them high risk surgical candidates for open reduction and internal fixation of their fractures [18, 21].

Secondly, blood loss could aggravate functional outcomes and increase mortality in patients with hip fracture by lowering hemoglobin levels. Carmelo et al. reported that the mean visible blood loss was 226ml in the Proximal Femoral Nail Antirotation group versus 285ml in the Trochanteric Gamma3 Nail group observed intraoperatively in the treatment of intertrochanteric fractures [22], which did not contain hidden blood loss after surgery. Similarly, Foss et al. found that the overall blood loss was 1473 mL greater than that observed intraoperatively in patients undergoing hip surgery, and Yu et al. further reported 277.2 ± 7.6 mL hidden blood loss in patients undergoing proximal femoral nail anti-rotation (PFNA) for intertrochanteric fractures [23, 24]. Oppositely, there was hardly any bleeding occurred in these patients treated with external fixator intra- and post-operatively.

Contrary to our findings, however, Zhang et al. reported that the long term functional outcome studies on HHS value in pertrochanteric fractures at 36 months postoperatively was lower than the HHS at one month postoperatively, compared to their mean HHS was 80.51 ± 2.91 at one month postoperatively whilst our mean HHS was only 42.07 ± 8.55 . It was probable that better explanation in our study was owing to the patients associated with higher risk accompanying disease preoperatively [25]. With the cooperation between the physiotherapist and the patient gradually strengthened

over time, the patients HHS tended to improve in the first twelve months, tended to plateau between twelve to twenty-four months postoperatively even though revision surgery were performed for four patients who were dissatisfied with functional outcome because of knee stiffness, which was in accordance with results from previously published studies [26, 27].

Of course, the longer term follow-up in these patients with proximal femoral fracture was challenging due to loss to follow-up bias and high mortality, but it could be speculated that HHS tend to decrease with age in the geriatric population that sustained intertrochanteric fracture and treated with exterior fixator [25, 28, 29].

Despite the mentioned benefits above, the complication rates of the technique- and patient-related could not be considered negligible and knee stiffness, pin-tract infection, deep venous thrombosis, varus angulation of the fracture (greater than 10°), and limb shortening were too frequently encountered. In the current study, 15 cases knee joint stiffness or joint mobility declined, 9 cases pin-tract infection, these results were approximately consistent with the findings of the similar bibliography in regard to femur fracture treated with external fixator, knee stiffness and pin-tract infection were problems inherent with the use of this method, Babar had reported that fourteen patients with close comminuted fractures of the shaft of the femur were treated with external fixation, as a result, 11 lost an average of 34 (0-75) degrees of range-of-motion in their knees, likewise, Zhang et al. claimed that 14 cases knee joint stiffness were observed in the treatment for femoral nonunion with segmental bone defect with monolateral external fixation [30, 31].

External fixator had an adverse impact on the activity and function of knee joint and some factors might be attributed to this phenomenon. Above all, the extension and contraction mobilization of the thigh muscles were greatly limited by screws inserted into the femur, which lead to the activity of knee joints worsen below the entrance of the screws due to it impede the movement of the iliotibial band, vastus lateralis and vastus intermedius when knee is flexed, namely, screws block the knee motion. Secondly, adhesions and tissue degeneration were usually occurred between muscles or between muscles and aponeurosis as a result of injury caused by screws when implanting, especially deteriorated if knee motion was repeatedly happened since it would inevitably lead to the inflammatory reaction because these organizations and screws that were rubbed against each other.

It was a living proof that most patients complained of irritation and pain in the opening site of entrance of the screws when knee exercising, worse still, some of them undergone local pyogenic infection. In turn, the adhesions and tissue degeneration would further affect knee mobilization. Unfortunately, four patients had to be hospitalized again and be treated for knee stiffness owing to the inflammatory reaction of the soft tissue that finally lead to these organization fast degeneration, lower elasticity, and even fibrosis. As expected, which were totally consistent with our intraoperative finding. From the reasons mentioned above, it might be speculated that soft tissue adhesions and degeneration was the main cause that affect knee return to the preinjury level even though the external fixator was removed after fracture healed.

In accordance to Kazemian study, of the twenty pertrochanteric fractures, ten patients had pin track infection, similarly, there were nine pin-track infection in our study, no chronic osteomyelitis occurred and all were treated with frequent pin care together with oral antibiotics [20].

It was reported that the preoperative prevalence rate of deep-vein thrombosis associated with fractures about the hip was 2.6%~29.8%, what's more, Aging and Delayed surgery have been proved to be risk factors of deep venous thrombosis for patients with hip fractures, to be more specific, the incidence increased each day from 14.5% if surgery was delayed >1 day to 33.3% if surgery was delayed >7 days despite prophylactic anticoagulation [32-36]. In our group, four patients who for head injury and pulmonary infection experienced a delay of >5 days from the time of injury until time of surgery and developed pulmonary embolus preoperatively for an overall incidence of thromboembolic disease of 26.7%. Therefore, on one hand, it was of paramount important that mechanical measures were immediately performed to minimize deep venous thrombosis or clinically detected pulmonary embolism when patients upon admission if pharmacological prophylaxis was contraindication, on the other hand, to shorten delayed surgery as soon as possible, a comprehensive, multidisciplinary cooperation was indeed needed to ensure that established protocols were consistently implemented, which would ensure a uniform and high standard of care for these high risk elderly patients with intertrochanteric fractures.

In our study, varus angulation of the fractures (greater than 10°) with subsequent limb shortening were two cases and this might be on account of significant convergence of the proximal pins with respect to the middle of the femoral neck, besides, another explanation could be the applied device configuration might influence the rate of malreduction and malunion, particularly in these unstable fractures cohort, as a result of increased working length of the spanning external fixator, since a shorter working length should probably increase the rigidity and strength of the construct and the overall fracture stability.

There are several limitations to our study. First, the small sample size may have introduced bias. However, the focus of our study was to assess the 2-year follow-up functional and radiographic outcomes of the external fixator in the treatment of unstable pertrochanteric fractures in elderly patients as open reduction and internal fixation was relative contraindications, an area that has not been studied extensively in the literature. Despite the small sample size, it was still possible to provide useful information with regard to predict the long-term functional outcome of these patients. Second, this study had problems inherent to its retrospective nature. Finally, because of the observational nature of this study, we may not have addressed all potential confounding variables in our analyses. Nevertheless, this study provides preliminary objective evidence about the effect of unstable proximal femur fractures treated with external fixation. Despite these limitations, this study presents long-term follow-up results and evaluates the causes that impact the clinical outcome of patients undergoing fixation.

In conclusion, the use of external fixator in high-risk geriatric provided a satisfactory long term efficacy, but the short term func-

tional results were quite unsatisfactory owing to high complication rate. Therefore, the advantages and disadvantages should be fully weighed when using external fixators, which was especially suitable for those patients who could not tolerate prolonged operative time and open surgery.

Acknowledgements

The authors gratefully thank those surgeons and patients who made this study possible.

Reference

1. Petsatodis G, Maliogias G, Karikis J, Christodoulou AG, Venetsanakis G, et al. (2011) External fixation for stable and unstable intertrochanteric fractures in patients older than 75 years of age: a prospective comparative study. *J Orthop Trauma* 25: 218-223.
2. Parker MJ, Das A (2013) Extramedullary fixation implants and external fixators for extracapsular hip fractures in adults. *Cochrane Database Syst Rev* 28: CD000339.
3. Succi AR, Casemyr NE, Leslie MP, Baumgaertner MR (2017) Implant options for the treatment of intertrochanteric fractures of the hip: rationale, evidence, and recommendations. *Bone Joint J* 99-B: 128-133.
4. Brauer CA, Coca-Perraillon M, Cutler DM, Rosen AB (2009) Incidence and mortality of hip fractures in the United States. *JAMA* 302: 1573-1579.
5. Kenzora JE, McCarthy RE, Lowell JD, Sledge CB (1984) Hip fracture mortality. Relation to age, treatment, preoperative illness, time of surgery, and complications. *Clin Orthop Relat Res* 186: 45-56.
6. Cher EWL, Allen JC, Howe TS, Koh JSB (2019) Comorbidity as the dominant predictor of mortality after hip fracture surgeries. *Osteoporos Int* 30: 2477-2483.
7. Moroni A, Faldini C, Pegreff F, Hoang-Kim A, Giannini S (2005) Osteoporotic pertrochanteric fractures can be successfully treated with external fixation. *J Bone Joint Surg Am* 87: 42-51.
8. Yousry AH, Chotai PN, El Ghazaly SA, Fayyad TA, Abdelgawad AA (2015) Outcomes of trochanteric external fixation for geriatric inter-trochanteric hip fractures. *J Orthop* 12: 174-178.
9. Kourtzis N, Pafilas D, Kasimatis G (2001) Management of pertrochanteric fractures in the elderly patients with an external fixation. *Injury* 32: SD115-28.
10. Owens WD, Felts JA, Spitznagel EL Jr (1978) ASA physical status classifications: a study of consistency of ratings. *Anesthesiology* 49: 239-243.
11. Marsh JL, Slongo TF, Agel J, Broderick JS, Creevey W, et al. (2007) Fracture and dislocation classification compendium - 2007: Orthopaedic Trauma Association classification, database and outcomes committee. *J Orthop Trauma* 21: S1-133.
12. Lorch DG, Geller DS, Nielson JH (2004) Osteoporotic pertrochanteric hip fractures: management and current controversies. *Instr Course Lect* 53: 441-454.
13. Baumgaertner MR, Curtin SL, Lindskog DM, Keggi JM (1995) The value of the tip-apex distance in predicting failure of fixation of peritrochanteric fractures of the hip. *J Bone Joint Surg Am* 77: 1058-1064.
14. Harris WH (1969) Traumatic arthritis of the hip after disloca-

- tion and acetabular fractures: treatment by mold arthroplasty. An end-result study using a new method of result evaluation. *J Bone Joint Surg Am* 51: 737-755.
15. Karn NK, Singh GK, Kumar P, Singh MP, Shrestha BP, et al. (2009) Management of trochanteric fractures of the femur with external fixation in high-risk patients. *Int Orthop* 33: 785-788.
 16. Radaideh AM, Qudah HA, Audat ZA, Jahmani RA, Yousef IR, et al. (2018) Functional and Radiological Results of Proximal Femoral Nail Antirotation (PFNA) Osteosynthesis in the Treatment of Unstable Pertrochanteric Fractures. *J Clin Med* 7: 78.
 17. Socci AR, Casemyr NE, Leslie MP, Baumgaertner MR (2017) Implant options for the treatment of intertrochanteric fractures of the hip: rationale, evidence, and recommendations. *Bone Joint J* 99: 128-133.
 18. Jones HW, Johnston P, Parker M (2006) Are short femoral nails superior to the sliding hip screw? A meta-analysis of 24 studies involving 3,279 fractures. *Int Orthop* 30: 69-78.
 19. Craig NJ, Sivaji C, Maffulli N (2001) Subtrochanteric fractures. A review of treatment options. *Bull Hosp Jt Dis* 60: 35-46.
 20. Kazemian GH, Manafi AR, Najafi F, Najafi MA (2014) Treatment of intertrochanteric fractures in elderly highrisk patients: dynamic hip screw vs. external fixation. *Injury* 45: 568-572.
 21. Morvan A, Boddart J, Cohen-Bittan J, Picard H, Pascal-Mousselard H, et al. (2018) Risk factors for cut-out after internal fixation of trochanteric fractures in elderly subjects. *Orthop Traumatol Surg Res* 104: 1183-1187.
 22. D'Arrigo C, Carcangiu A, Perugia D, Scapellato S, Alonzo R, et al. (2012) Intertrochanteric fractures: comparison between two different locking nails. *Int Orthop* 36: 2545-2551.
 23. Foss NB, Kehlet H (2006) Hidden blood loss after surgery for hip fracture. *J Bone Joint Surg Br* 88: 1053-1059.
 24. Yu W, Zhang X, Wu R, Zhu X, Hu J, et al. (2016) The visible and hidden blood loss of Asia proximal femoral nail anti-rotation and dynamic hip screw in the treatment of intertrochanteric fractures of elderly high- risk patients: a retrospective comparative study with a minimum 3 years of follow-up. *BMC Musculoskelet Disord* 17: 269.
 25. Zhang H, Zeng X, Zhang N, Zeng D, Xu P, et al. (2017) INTERTAN nail versus proximal femoral nail antirotation-Asia for intertrochanteric femur fractures in elderly patients with primary osteoporosis. *J Int Med Res* 45: 1297-1309.
 26. Babhulkar S (2017) Unstable trochanteric fractures: Issues and avoiding pitfalls. *Injury* 48: 803-818.
 27. Vishwanathan K, Akbari K, Patel AJ (2018) Is the modified Harris hip score valid and responsive instrument for outcome assessment in the Indian population with pertrochanteric fractures? *J Orthop* 15: 40-46.
 28. Nazrun AS, Tzar MN, Mokhtar SA, Mohamed IN (2014) A systematic review of the outcomes of osteoporotic fracture patients after hospital discharge: morbidity, subsequent fractures, and mortality. *Ther Clin Risk Manag* 10: 937-948.
 29. Zhou S, Liu J, Zhen P, Shen W, Chang Y, et al. (2019) Proximal femoral nail anti-rotation versus cementless bipolar hemiarthroplasty for unstable femoral intertrochanteric fracture in the elderly: a retrospective study. *BMC Musculoskelet Disord* 20: 500.
 30. Babar IU (2004) External fixation in close comminuted femoral shaft fractures in adults. *J Coll Physicians Surg Pak* 14: 553-555.
 31. Zhang Q, Zhang W, Zhang Z, Zhang L, Chen H, et al. (2017) Femoral nonunion with segmental bone defect treated by distraction osteogenesis with monolateral external fixation. *J Orthop Surg Res* 12: 183.
 32. Hefley FG Jr, Nelson CL, Puskarich-May CL (1996) Effect of delayed admission to the hospital on the preoperative prevalence of deep-vein thrombosis associated with fractures about the hip. *J Bone Joint Surg Am* 78: 581-583.
 33. Cho YH, Byun YS, Jeong DG, Han IH, Park YB (2015) Preoperative Incidence of Deep Vein Thrombosis after Hip Fractures in Korean. *Clin Orthop Surg* 7: 298-302.
 34. Xing F, Li L, Long Y, Xiang Z (2018) Admission prevalence of deep vein thrombosis in elderly Chinese patients with hip fracture and a new predictor based on risk factors for thrombosis screening. *BMC Musculoskelet Disord* 19: 444.
 35. Di Minno G, Tufano A (2004) Challenges in the prevention of venous thromboembolism in the elderly. *J Thromb Haemost* 2: 1292-1298.
 36. Smith EB, Parvizi J, Purtill JJ (2011) Delayed surgery for patients with femur and hip fractures-risk of deep venous thrombosis. *J Trauma* 70: E113-116.

Copyright: ©2021 : Yu Liang, et al. This is an open-access article distributed under the terms of the Creative Commons Attribution License, which permits unrestricted use, distribution, and reproduction in any medium, provided the original author and source are credited.