

Ocular Rosacea: Treatment with Rifaximin, a Non-Systemic Antibiotic

Leonard B Weinstock^{1,2} and Trisha L Myers²

¹Washington University School of Medicine, St Louis, MO, US

²Specialists in Gastroenterology, LLC, St Louis, MO, US

*Corresponding author

Leonard B. Weinstock, 11525 Olde Cabin Road, St Louis, MO 63141, US, Tel: 314-997-0554; Fax: 314-997-5086; E-mail: lw@gidoctor.net.

Submitted: 10 Nov 2016; Accepted: 28 Nov 2016; Published: 03 Dec 2016

Abstract

Background: Rosacea is associated with Crohn's disease, liver disease, chronic pancreatitis, achlorhydria, *Helicobacter pylori* and recently with idiopathic small intestinal bacterial overgrowth (SIBO). Two publications demonstrated that rifaximin, a non-absorbed, gut-directed antibiotic for SIBO led to improvement in facial rosacea. Ocular manifestations occur in up to 58% of rosacea patients and include dry eyes, foreign body sensation, photosensitivity, eyelid inflammation, neovascularization and corneal ulcers.

Methods: Patients who had been diagnosed with ocular rosacea by four ophthalmologists were referred for SIBO testing using the lactulose breath test (LBT). All were refractory to rosacea therapy. An open-label, IRB-approved trial of rifaximin 550 mg/3x/day for 10-14 days was performed in LBT-positive subjects. Ten and twenty days after ending rifaximin, subjects were queried if their eye symptoms had marked, moderate or mild improvement or if they were unchanged.

Results: Twenty four patients (21F/3M), mean age 59 with facial involvement in 4 were tested. The LBT was positive in 9/24 (38%). LBT-positive subjects had chronic gastrointestinal symptoms in 63% vs., 33% in LBT-negative subjects. Rifaximin was prescribed to 9 LBT-positive subjects. Insurance denied the prescription in one subject. One subject was lost was to follow up. Improvement in ocular rosacea symptoms was marked (4), moderate (1) and mild (2).

Conclusions: Rifaximin therapy led to improvement in ocular rosacea in the setting of SIBO. Dysregulation of the innate immune system as a result of gastrointestinal inflammation could lead to an increase in systemic cytokines and microbial antigens/antibodies in the skin and eyelids leading to activation of rosacea.

Introduction

Ocular manifestations occur in up to 58% of patients with rosacea and include telangiectasia, corneal ulcers and vascularization, and sensitivity to light [1]. Rosacea has been associated with inflammatory bowel disease, chronic liver disease, chronic pancreatitis, achlorhydria, *Helicobacter pylori* and, recently, with small intestinal bacterial overgrowth (SIBO) [2]. One hypothesis is that dysregulation of the innate immune system as a result of GI inflammation caused by infection or bacterial overgrowth could lead to an increase in cytokines and antimicrobial molecules in the skin [2]. Topical and systemic antibiotics are common therapies for facial and ocular rosacea, suggesting that elimination of bacteria and the immune alterations they elicit is effective; however, because bacteria within the GI tract may be involved in rosacea pathophysiology, use of a non-systemic antibiotic may also be beneficial [2]. A placebo-controlled trial showed that rifaximin, a non-systemic antibiotic, resolved flushing, papules, and pustules in patients with facial rosacea concomitant with eradication of small intestinal bacterial overgrowth (SIBO) [3]. A subsequent study

led to similar findings [4]. The present case series extends these observations to patients with ocular rosacea which has hitherto now not been reported.

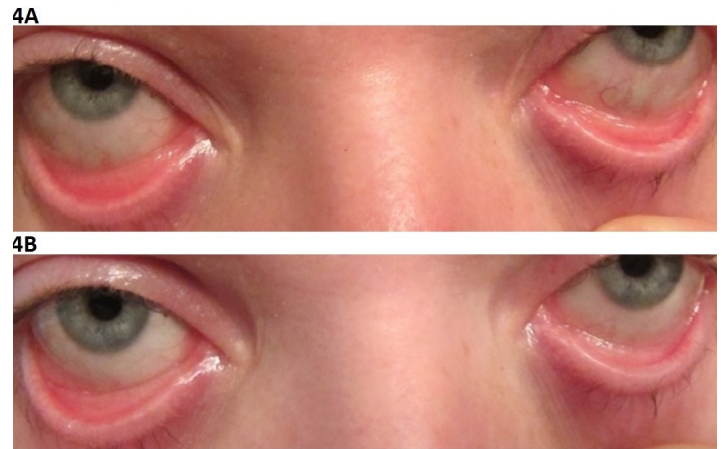
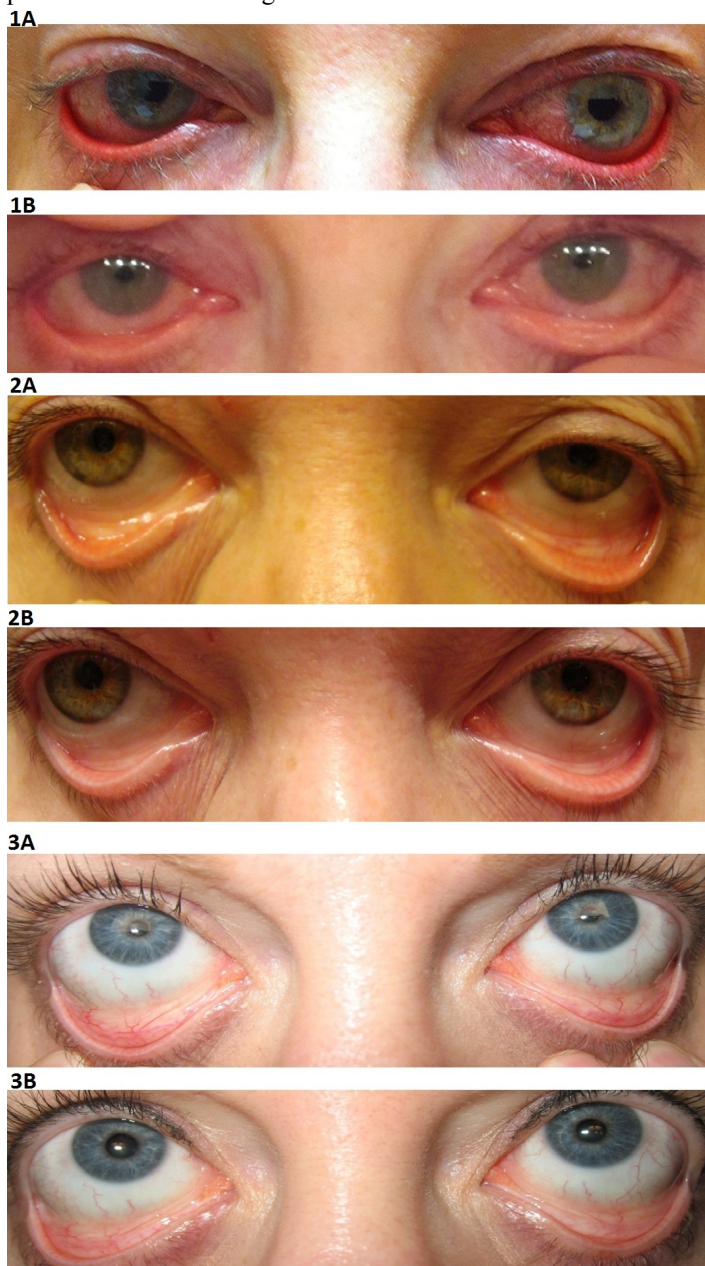
Methods

Four patients who had been diagnosed with ocular rosacea by an ophthalmologist were referred to a gastroenterologist. All patients were refractory to medical therapy for rosacea and underwent a lactulose breath test (LBT) to ascertain the presence of SIBO. The LBT procedure consisted of collections of breath samples at baseline and every 15 minutes for 90 minutes after ingestion of 10 g of lactulose mixed in 250 ml of water. Hydrogen and methane content in the samples were analyzed by gas chromatography (QuinTron DP Plus MicroLyzer™; QuinTron Instrument Company, Milwaukee, WI). Rifaximin (XIFAXAN®, Salix Pharmaceuticals, Inc, Morrisville, NC) 400 mg three times daily for 10 -14 days was offered to patients as part of our standard clinical practice of treatment given for SIBO. As part of our standard clinical practice treating patients with SIBO patients

were asked to complete a self-report questionnaire that queried clinical improvement at 10 and 20 days after completing therapy. Responses were “clear or marked improvement,” “moderate improvement,” “mild improvement,” or “unchanged”.

Results

Twenty-four patients (21F/3M, mean age 59) were evaluated. The LBT was positive in 9 of the 24 patients (38%). Eight patients were treated with rifaximin. Insurance denied the prescription in one patient. LBT-positive patients had chronic gastrointestinal symptoms in 63% versus 33% in LBT-negative patients. One patient was lost to follow up. Improvement in ocular rosacea symptoms was marked (4), moderate (1), and mild (2). Thus, rifaximin therapy led to improvement in ocular rosacea in 77.8% of patients in the setting of SIBO. Before and after therapy for 4 patients are shown in Figures 1-4.



Figures 1-4: (A) Patient with ocular manifestations of rosacea before treatment with rifaximin. (B) Rifaximin 1200 mg/d for 10-14 days significantly reduced conjunctival erythema - this was maintained 20 days after therapy ended.

Discussion

Treatment with rifaximin, a gut-directed antibiotic, improved symptoms in patients with ocular rosacea in this small case series. Given that rosacea is an inflammatory disorder and that SIBO may increase systemic endotoxin levels, the observed symptom improvement with rifaximin may be the result of SIBO eradication concomitant with a decrease in inflammatory processes [5]. In a rodent model of colitis, rifaximin reduced bacterial translocation and decreased the production of inflammatory cytokines within the GI tract [6].

This suggests that rifaximin influences inflammatory processes, a theory that is strengthened by *in vitro* data showing that rifaximin antagonizes the effect of tumor necrosis factor α in colonic epithelial cells [7]. Given the improvement of rosacea with rifaximin therapy observed in our case study and in previous clinical trials in facial rosacea, the effect of rifaximin on ocular rosacea deserves further study [3,5].

Acknowledgement

Leonard B. Weinstock, MD is on the Salix Pharmaceuticals Speakers Bureau. No support was received for this clinical study. Dr Weinstock was responsible for the design and conduct of the study; interpretation of the data; and preparation, review, and approval of the research letter. Trisha Myers has no disclosures.

References

1. Stone DU, Chodosh J (2004) Ocular rosacea: an update on pathogenesis and therapy. *Curr Opin Ophthalmol* 15: 499-502.
2. Yamasaki K, Gallo RL (2009) The molecular pathology of rosacea. *J Dermatol Sci* 55: 77-81.
3. Parodi A, Paolino S, Greco A, Drago F, Mansi C, et al. (2008) Small intestinal bacterial overgrowth in rosacea: clinical effectiveness of its eradication. *Clin Gastroenterol Hepatol* 6: 759-764.
4. Bauer TM, Schwacha H, Steinbrückner B Brinkmann FE,

-
- Ditzen AK, et al. (2002) Small intestinal bacterial overgrowth in human cirrhosis is associated with systemic endotoxemia. *Am J Gastroenterol* 97: 2364-2370.
5. Weinstock LB, Steinhoff M (2013) Rosacea and small intestinal bacterial overgrowth and rosacea: prevalence and response to rifaximin. *J Am Acad Dermatol* 68: 875-876.
 6. Fiorucci S, Distrutti E, Mencarelli A, Barbanti M, Palazzini E, et al. (2002) Inhibition of intestinal bacterial translocation with rifaximin modulates lamina propria monocytic cells reactivity and protects against inflammation in a rodent model of colitis. *Digestion* 66: 246-256.
 7. Mencarelli A, Migliorati M, Distrutti E (2010) Rifaximin is a Human Pregnane X Receptor Activator in Human Colon Epithelial Cells and Regulate Detoxification Pathway. *Gastroenterology* 138: S-422.

Copyright: ©2016 Weinstock LB and Myers TL. This is an open-access article distributed under the terms of the Creative Commons Attribution License, which permits unrestricted use, distribution, and reproduction in any medium, provided the original author and source are credited.