

Mini-Invasive Treatment for Cellulite Blemishes: 15 Months of Experience

Roberto Dell'Avanzato*, L'Albereta Relais and Chateaux

Medical Department of Espace Chenot Health Wellness & Spa
Via Vittorio Emanuele 23 - 25030 Erbusco (BS) - Italy

***Corresponding author**

Roberto Dell'Avanzato, Medical Department of Espace Chenot Health Wellness & Spa, Via Vittorio Emanuele 23 - 25030 Erbusco (BS) – Italy, E-mail: dellavanzato@hotmail.it

Submitted: 16 Jan 2018; **Accepted:** 23 Jan 2018; **Published:** 31 Jan 2018

Abstract

Introduction: In October 2016 I started, as one of the first in Europe, my experience with a new procedure that represents the only FDA-cleared minimally invasive treatment clinically proven to improve the cellulite blemishes for nearly four years in only one session.

Materials and Methods: We report our experience after 15 months in 50 patients (48F; 2M) with cellulite treated in a single session. Follow-up were scheduled after 7 days (T7), 14 days (T14), 30 days (T30), 90 days (T90) and 180 days (T150) for all the 50 patients; 13 patients (1M) had a medical check at 12 months and 3 patients (1M) at 15 months. Outcome measures included subject photographs, Cellulite Severity Scale (CSS) and Global Aesthetic Improvement Scale (GAIS) assessment. Patient satisfaction and pain rating were also recorded. The treatment takes 45-60 minutes. Cellulite dimples are marked and the device is applied to stretch and stabilize tissue in a vacuum chamber, while local anesthesia is delivered. Then, a precise minimally-invasive subcutaneous release of the connective bands (TS-GS: stabilized-guided subcision) is performed with a micro-blade, without cuts or incisions. We have safely treated 6 to 45 sites in one session. After treatment, a light compression is applied and patients are able to return promptly to their daily life.

Results: The procedure treated successfully the primary structural cause of cellulite blemishes in all the 50 patients. Patient satisfaction was 87% at T90 in 50 patients (48F; 2M), 95% at T180 in 50 patients, 97% at 12 months in 13 patients (1M) and 100% at 15 months in 3 patients (1M). Transient treatment-related adverse events were mild in severity and the most common side effects reported were soreness and bruising. Among 50 patients, 95% had bruising at T7, 23% at T14 and no patient had bruising at T30. Soreness is reported in 100% of patients at T7, 19% at T14, 4% at T30 and 0% at T90. Global Aesthetic Improvement Scale (GAIS) and Visual Analog Scale (VAS) are also reported.

Conclusions: This revolutionary FDA-cleared procedure for the cellulite puckering, combines a proven approach with an innovative technology to treat the primary structural cause of cellulite blemishes in posterior thighs and buttocks. This study confirms his safety, and efficacy with vacuum-assisted precise tissue release for the treatment of cellulite, which is also strengthened by patients satisfaction.

Introduction

I've been one of the first physician selected in Italy from Merz Italia in October 2016 and one of the first in Europe to offer Cellfina (Ulthera, Inc, Mesa, Arizona) for the treatment of cellulite [1-14]. Cellfina represent the only FDA-cleared minimally invasive treatment clinically proven to improve the cellulite blemishes in posterior thighs and buttocks for nearly four years in only one session [15-20]. Cellulite refers to the dimpled appearance of skin, which is estimated to affect approximately 85% of post-pubertal women of all races [15,21,22]. This means that 1.4 billion of female worldwide have cellulite and 80% of them (1.1 billion) are concerned with

their cellulite; 98% of them are motivated to do something [23,24]. Therefore, over 1 billion women worldwide who have cellulite want to do something [24]. The appearance of cellulite has been associated with behavioral changes and can negatively affect self-esteem [25]. Although the etiology of cellulite is not completely understood, the anatomical structures associated with cellulite have been studied: fibrous septa connect the skin to underlying tissue at select points, are oriented perpendicular to the skin surface and pull down on the dermis and this result in dimpled, bumpy skin [17-26]. In a previous study, results of the MRI analysis showed that cellulite depressions on the buttocks were significantly associated with the presence of

underlying fibrous septa; fibrous septa were visualized in 96.7% of the area with cellulite depressions and all the fibrous septa found in the examined areas were perpendicular to the skin surface [27]. Current treatments for cellulite include non-invasive procedures that generally target the fat cells instead of the septa. Treatments directed specifically at the fibrous septa includes subcision laser liposuction and other laser treatments where the most effective procedure is represented by Endolift (Dell'Avanzato technique) performed with a 200-300 micron fiber connected to a 1470nm diode laser instead of the application of a 1440-nm Nd:YAG laser cannula too aggressive in comparison with the Endolift procedure [28-46]. Subcision, a tissue release technique, has been utilized for many years with discontinuous results worldwide [30-47]. Cellfina has refined subcision with both depth and area control providing reproducible, safe and certified results with little downtime due to an external system with excellent safety profile and effectiveness, that allows to complete the procedure in a medical setting, in local anesthesia. The optimal candidate is a patient in the 20/50 year range classified with mild or moderate cellulite dimples at rest and in dynamic, with mild skin laxity at rest, with stable weight. Although cellulite is uncommon in men, we have successfully treated two male patient with the Cellfina procedure.

Materials and Methods

We report our experience after 15 months in 50 patients (48F; 2M) between 18 to 71 year range (mean 37.3), with body mass index (BMI) <35 (mean 23.7). Ethnicity was the following: 34 white, 10 black (1M), 4 asian, 2 hispanic (1M). Patients were divided in 6 classes according to the Fitzpatrick skin type: class I and II , class III , class IV , class V and VI (2M) [13,26,9].

Regarding the two male patient treated, the first was a 45 years-old male with a gonadotropin-releasing hormone deficiency and low testosterone levels; the second was a 34 years-old male with BMI <35. All the patients received a single session of treatment.

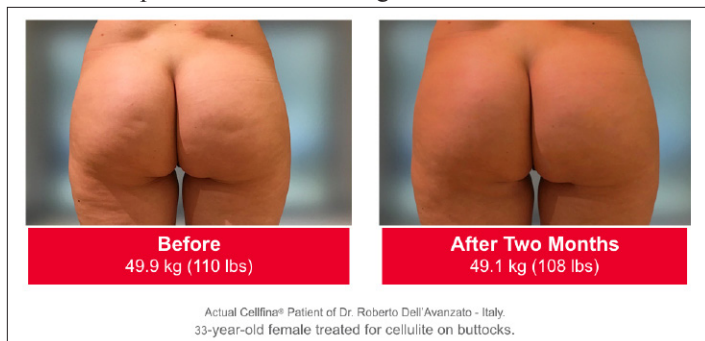


Figure 1: Before and After a single procedure

Outcome measures included patient photographs with an appropriate overhead lighting to accentuate contour irregularities, control of the weight, Cellulite Severity Scale (CSS) and Global Aesthetic Improvement Scale assessment. Patient satisfaction and pain rating were also recorded. None of the 50 patients change the weight by more than 10%, otherwise they would be excluded from the present study. Follow-up assessments were scheduled after 7 days (T7), 14 days (T14), 30 days (T30), 90 days (T90) and 180 days (T150) for all the 50 patients; 13 patients (1M) had a medical check at 12 months and 3 patients (1M) at 15 months. The treatment takes between 45 to 60 minutes. The procedure starts marking the cellulite while standing, with a pre-marked photos printed in my hand. It's always

better that the patient has seen the marked photos in order to be able to understand and confirm the plan. Once the patient is in a prone position, we disinfect the skin with a solution not to remove the preoperative markings. Following the marking, the device is applied to stretch and stabilize the tissue in a vacuum chamber, than the anesthetic solution is infiltrated using the Cellfina System's 22-gauge multi-hole needle at a depth of 6 mm or 10 mm. Once all the areas have been infiltrated with anesthesia, a precise minimally-invasive subcutaneous release of the connective bands (TS-GS: stabilized-guided subcision) is performed with a micro-blade, without cuts or incisions, to release the tissue underneath the marked areas. We have safely treated 6 to 45 sites in one session with a range of 15-30 sites in 73% of cases, 6-14 sites in 20% and 31-45 in 7%. After treatment, a light compression is applied during the one-two weeks following the procedure and patients are able to return promptly to their daily life. Immediately after the procedure, patients are dressed with absorbent bandages until the next day, underneath a compressive garments, because of the leakage of anesthesia fluid. It's better to limit the exercise for 3-4 days after the procedure in order to reduce swelling and bruising. Transient treatment-related adverse events were mild in severity and the most common side effects reported were soreness and bruising. No seromas has been reported in all the 50 patients.

Results

Patient satisfaction was 87% at T90 in 50 patients (48F; 2M), 95% at T180 in 50 patients, 97% at 12 months in 13 patients (1M) and 100% at 15 months in 3 patients (1M). Bruising was the only relevant side effect. Nevertheless among 50 patients, 95% had bruising at T7, 23% at T14 and no patient had bruising at T30. In our series, soreness is reported in 100% of patients at T7 and usually can last for several days: 19% at T14, 4% at T30 and 0% at T90. The default depth of choice is 6 mm, but if there is a site too close is better to perform the adjacent release at 10 mm of depth to avoid the connection of sites at the same depth. This avoids problems encountered during the early development of the device where aggressive connection of sites at a single depth led to larger contiguous areas of release, which took longer time to heal and more seromas that were common with the old subcision. Dr. Hexel referred that in the postoperative period after subcision all the patients had pain, bruises and hemosiderosis. The Hexsel Cellulite Severity Scale (CSS) is a current evaluation tool to measure cellulite severity [16-48]. The Hexsel CSS rates each of 5 domains of cellulite (number of evident depressions, depression depth, morphologic skin surface alterations, skin laxity, flaccidity, or sagging, and Nürnberger and Müller classification) from "0" (no alteration) to "3" (most severe). The simplified Cellulite Severity Scale (CSS) assessment used in this study is the one developed and validated in the Kraminer et al. Multicenter Pivotal Study in which the two key clinical morphologic features of cellulite were quantified: (A) number of evident depressions in the treatment area and (B) average depth of the depressions [15]. Regarding the Global Aesthetic Improvement Scale (GAIS), which assesses the improvement in cellulite, showed that the mean baseline CSS score of 3.6 decreased to 1.2 at T90 ($p < 0.001$) and 1.1 at T180 ($p < 0.001$); in the 13 patients controlled after 12 months the score remained 1.1 ($p < 0.001$); in the 3 patients controlled at 15 months, it decrease to 1.0 ($p < 0.001$). Visual Analog Scale (VAS) from 0 to 10, is used to check the level of pain during the anesthetic infiltration (a mean score of 3.8 similar with other cosmetic procedures), it was 2.2 at T7, 1.8 at T14 and 0 from T90 onwards.

Conclusions

This revolutionary FDA-cleared procedure for the cellulite puckering, combines a proven approach with an innovative technology to treat the primary structural cause of cellulite blemishes. The results of this study showed that a single treatment with a novel controlled tissue release system improved the appearance of cellulite on posterior thighs and buttocks. This study confirmed the safety, efficacy and patient satisfaction with vacuum-assisted precise tissue release in the treatment of cellulite and showed that with a proper patient selection and technique, the Cellfina procedure delivers outstanding results and patient satisfaction.

References

1. Dell'Avanzato R (2016) A revolutionary mini-invasive treatment for cellulite blemishes: initial experiences and outcomes. Proceed. 12th Aesthetic and Anti-aging Medicine European Congress (AMEC); Oct 21-22, 2016; Paris, France.
2. Dell'Avanzato R (2017) A revolutionary mini-invasive treatment for cellulite blemishes: initial experiences and outcomes. Proceed. 19th World Congress of the International Master Course on Aging Science (IMCAS); Jan 26-29, 2017; Paris, France.
3. Dell'Avanzato R (2017) A revolutionary mini-invasive treatment for cellulite blemishes: initial experiences and outcomes after 3 months. Proceed. 9th American-Brazilian Aesthetic Meeting (ABAM); Feb. 24-27, 2017; Park City, Utah, USA.
4. Dell'Avanzato R, Rossetti E (2017) A revolutionary mini-invasive treatment for cellulite blemishes: initial experiences and outcomes after 3 months. Proceed. 20th International Congress of Aesthetic Medicine and Surgery (SIES - VALET); Feb 24-26, 2017; Bologna, Italy.
5. Dell'Avanzato R (2017) A revolutionary mini-invasive treatment for cellulite blemishes: initial experiences and outcomes after 6 months. Proceed. 4th Italian Aesthetic Medical Federation Congress (FIME); Apr 1, 2017; Bologna, Italy.
6. Dell'Avanzato R (2017) A revolutionary mini-invasive treatment for cellulite blemishes: initial experiences and outcomes after 6 months. Proceed. 15th Aesthetic & Anti-Aging Medicine World Congress (AMWC); April 6-8, 2017; Monte-Carlo, Principauté de Monaco.
7. Dell'Avanzato R (2017) A revolutionary mini-invasive treatment for cellulite blemishes: initial experiences and outcomes after 6 months. Proceed. 38th National Congress of the Italian Society of Aesthetic Medicine (SIME); May 12-14, 2017; Rome, Italy.
8. Dell'Avanzato R (2017) A revolutionary mini-invasive treatment for cellulite blemishes: One year of experience. Proceed. Clinical+Cosmetic+Reconstructive EXPO (CCR) Congress; Oct 5-6, 2017; London UK.
9. Dell'Avanzato R (2017) A revolutionary mini-invasive treatment for cellulite blemishes: One year of experience. Proceed. 19th International Congress of Aesthetic Medicine (Agorà); Oct 12-14, 2017; Milan, Italy.
10. Dell'Avanzato R (2017) A revolutionary mini-invasive treatment for cellulite blemishes: One year of experience. Proceed. 7th International Conference and Expo on Cosmetology, Trichology & Aesthetic Practices; Oct 26-28, 2017; Paris, France.
11. Dell'Avanzato R (2017) A revolutionary mini-invasive treatment for cellulite blemishes: One year of experience. Proceed. 12th Forum Risk Management - Dec 1th, 2017; Florence, Italy.
12. Dell'Avanzato R (2017) A revolutionary mini-invasive treatment for cellulite blemishes: 15 months of initial experience. Proceed. 20th World Congress of the International Master Course on Aging Science (IMCAS); Feb 1-3, 2017; Paris, France.
13. Dell'Avanzato R (2018) A revolutionary mini-invasive treatment for cellulite blemishes: 15 months of initial experience. Proceed. 33rd Hawaii Plastic Surgery Symposium; Feb 17-18, 2018; Honolulu, Hawaii, USA.
14. Dell'Avanzato R (2017) A revolutionary mini-invasive treatment for cellulite blemishes: 15 months of initial experience. Proceed. 21st International Congress of Aesthetic Medicine and Surgery (SIES - VALET); Feb 23-25, 2017; Bologna, Italy.
15. Kaminer MS, Coleman III WP, Weiss RA, Robinson DM, Coleman WP 4th et al. (2015) Multicenter pivotal study of vacuum-assisted precise tissue release for the treatment of cellulite. *Dermatol Surg* 41: 336-347.
16. Green JB, Cohen JL (2015) Cellfina observations: pearls and pitfalls. *Semin Cutan Med Surg*. 34: 144-146.
17. Green JB, Cohen JL, Kaufman J, Metelitsa AI, Kaminer MS (2015) Therapeutic approaches to cellulite. *Semin Cutan Med Surg* 34: 140-143.
18. Kaminer MS, Coleman WP 3rd, Weiss RA, Grossman J (2016) Tissue Stabilized-Guided Subcision for the Treatment of Cellulite: A Multicenter Pivotal Study with Two-Year Follow-up. *Dermatol Surg* 42: 1213-1216.
19. Kaminer MS, Coleman WP 3rd, Weiss RA, Robinson DM, Grossman J (2017) A Multicenter Pivotal Study to Evaluate Tissue Stabilized-Guided Subcision Using the Cellfina Device for the Treatment of Cellulite With 3-Year Follow-Up. *Dermatol Surg* 43: 1240-1248.
20. Christman MP, Belkin D, Geronemus RG, Brauer JA (2017) An Anatomical Approach to Evaluating and Treating Cellulite. *J Drugs Dermatol* 16: 58-61.
21. Sainio EL, Rantanen T, Kanerva L (2000) Ingredients and safety of cellulite creams. *Eur J Dermatol* 10: 596-603.
22. US Census Bureau. <https://www.census.gov/programs-surveys/international-programs.html>.
23. Avram MM (2004) Cellulite: a review of its physiology and treatment. *J Cosmet Laser Ther* 6: 181-185.
24. Global Cellulite Survey of 1,318 women, conducted by Harris Poll for Merz, 2015.
25. Hexsel D, Hexsel CL, Weber MD (2010) Social impact of cellulite and its impact on quality of life. In: Goldman MP, Hexsel D, editors. *Cellulite pathophysiology and treatment*. 2nd ed. London: Informa; 2010.
26. Omi T, Sato S, Kawana S (2013) Ultrastructural assessment of cellulite morphology: clues to a therapeutic strategy? *Laser Ther* 22: 131-136.
27. Hexsel D, Abreu M, Rodrigues Y, et al. (2009) Side-by-side comparison of areas with and without cellulite depressions using magnetic resonance imaging. *Derm Surg* 35: 1-7.
28. Orentreich DS, Orentreich N (1995) Subcutaneous incisionless (subcision) surgery for the correction of depressed scars and wrinkles. *Dermatol Surg* 21: 543-549.
29. Alam M, Omura N, Kaminer MS (2005) Subcision for acne scarring: technique and outcomes in 40 patients. *Dermatol Surg* 31: 310-317.
30. Hexsel DM, Mazzuco R (2000) Subcision: a treatment for cellulite. *Int J Dermatol* 39: 539-544.
31. Hexsel D, Dal'Forno T, Soirefmann M, et al. (2010) Reduction of cellulite with subcision. In: Alam M, Pongprutthipan M, editors. *Body rejuvenation*. New York: Springer; 2010.
32. Dell'Avanzato R (2016) Laser Liposuction: is it the real gold-

- standard for the mini-invasive subcutaneous fat reduction? Proceed. 12th Aesthetic and Anti-aging Medicine European Congress (AMEC); Oct 21-22, 2016; Paris, France.
33. Dell'Avanzato R (2017) Micro Liposculpture Laser assisted: 12 years of personal experience. Proceed. 19th World Congress of the International Master Course on Aging Science (IMCAS); Jan 26-29, 2017; Paris, France.
 34. Dell'Avanzato R (2017) Micro Liposculpture Laser assisted: 12 years of personal experience. Proceed. 20th International Congress of Aesthetic Medicine and Surgery (SIES - VALET); Feb 24-26, 2017; Bologna, Italy.
 35. Dell'Avanzato R (2017) Micro Liposculpture Laser assisted: 12 years of personal experience. Proceed. 15th Aesthetic & Anti-Aging Medicine World Congress (AMWC); April 6-8, 2017; Monte-Carlo, Principauté de Monaco.
 36. Dell'Avanzato R (2017) Laser Liposuction: is it the real gold-standard for the mini-invasive subcutaneous fat reduction? Proceed. 38th National Congress of the Italian Society of Aesthetic Medicine (SIME); May 12-14, 2017; Rome, Italy.
 37. Dell'Avanzato R (2017) Micro Liposculpture Laser assisted: 12 years of personal experience. Proceed. 19th International Congress of Aesthetic Medicine (Agorà); Oct 12-14, 2017; Milan, Italy.
 38. Toledo L (1991) Syringe liposculpture: a two-year experience. *Aesth Plast Surg* 15: 321-326.
 39. Dell'Avanzato R (2017) Endolift Laser: 12 years of personal experience in face and body soft-lifting. Proceed. 4th Italian Aesthetic Medical Federation Congress (FIME); Apr 1, 2017; Bologna, Italy.
 40. Dell'Avanzato R (2016) Endolift Laser: 12 years of personal experience in face and body soft-lifting. Proceed. 12th Aesthetic and Anti-aging Medicine European Congress (AMEC); Oct 21-22, 2016; Paris, France.
 41. Dell'Avanzato R (2017) Endolift Laser: 12 years of personal experience in face and body soft-lifting. Proceed. 19th World Congress of the International Master Course on Aging Science (IMCAS); Jan 26-29, 2017; Paris, France.
 42. Dell'Avanzato R (2017) Endolift Laser: 12 years of personal experience in face and body soft-lifting. Proceed. 20th International Congress of Aesthetic Medicine and Surgery (SIES - VALET); Feb 24-26, 2017; Bologna, Italy.
 43. Dell'Avanzato R (2017) Endolift Laser: 12 years of personal experience in face and body soft-lifting. Proceed. 15th Aesthetic & Anti-Aging Medicine World Congress (AMWC); April 6-8, 2017; Monte-Carlo, Principauté de Monaco.
 44. Dell'Avanzato R (2017) Endolift Laser: 12 years of personal experience in face and body soft-lifting. Proceed. 38th National Congress of the Italian Society of Aesthetic Medicine (SIME); May 12-14, 2017; Rome, Italy.
 45. Dell'Avanzato R (2017) Endolift Laser: 12 years of personal experience in face and body soft-lifting. Proceed. 19th International Congress of Aesthetic Medicine (Agorà); Oct 12-14, 2017; Milan, Italy.
 46. DiBernardo B, Sasaki G, Katz BE, et al. (2013) A multicenter study for a single, three-step laser treatment for cellulite using a 1440-nm Nd:YAG laser, a novel side-firing fiber, and a temperature-sensing cannula. *Aesthet Surg J* 33: 576-584.
 47. Orentreich DS, Orentreich N (1995) Subcutaneous incisionless (subcision) surgery for the correction of depressed scars and wrinkles. *Dermatol Surg*. 21: 543-549.
 48. Hexsel DM, Dal'forno T, Hexsel CL (2009) A validated photonumeric cellulite severity scale. *J Eur Acad Dermatol Venereol*. 23: 523-528.

Copyright: ©2018 Roberto Dell'Avanzato. This is an open-access article distributed under the terms of the Creative Commons Attribution License, which permits unrestricted use, distribution, and reproduction in any medium, provided the original author and source are credited.