

Licorice (*Glycyrrhiza Glabra*) Accelerates the Burn Wound Healing in Rats and Inhibits Growth of Skin Pathogens In-Vitro

Mohsen Zabihi^{1*}, Pooya Taherifard², Ali Mohammad Ranjbar^{3*}, Fatemeh Shishehbor⁴

¹Department of Pharmacology, School of Pharmacy, Shahid Sadoughi University of Medical Sciences, Yazd, Iran

²School of Pharmacy, Shahi Sadoughi University of Medical Sciences, Yazd, Iran

³Corresponding author: Department of Pharmacognosy, School of Pharmacy, Shahid Sadoughi University of Medical Sciences, Yazd, Iran

⁴School of Pathology, Shahid Sadoughi University of Medical Sciences, Yazd, Iran

*Corresponding author

Mohsen Zabihi, Department of Pharmacology, School of Pharmacy, Shahid Sadoughi University of Medical Sciences, Yazd, Iran

Ali Mohammad Ranjbar, Department of Pharmacognosy, School of Pharmacy, Shahid Sadoughi University of Medical Sciences, Yazd, Iran

Submitted: 02 Apr 2021; Accepted: 05 Apr 2021; Published: 07 Apr 2021

Citation: Mohsen Zabihi, Pooya Taherifard, Ali Mohammad Ranjbar, Fatemeh Shishehbor (2021) Licorice (*Glycyrrhiza Glabra*) Accelerates the Burn Wound Healing in Rats and Inhibits Growth of Skin Pathogens In-Vitro. *Toxi App Phar Insig* 4: 27-32.

Abstract

Background: Skin heat damage is considered as one of the most devastating condition and may cause some morbidities and mortalities. Licorice (*Glycyrrhiza glabra*) is used in traditional Iranian medicine to treat burns.

Methods: Second- and third-degree burns on the dorsal skin in rats were induced under general anesthesia by a metal plate (2 cm in diameter). The wounds were treated topically with 6 concentrations of licorice root hydroalcoholic extract, silver sulfadiazine cream (1%) or normal saline as control for 21 days. Subsequently, the macroscopic and the histopathologic parameters including epithelialization, neutrophil migration, angiogenesis, collagen formation and wound contraction were evaluated. The anti-bacterial effects of the extract on some pathogens of wound infections including *Staphylococcus aureus*, *Pseudomonas aeruginosa* and *Acinetobacter* spp were also studied in-vitro.

Results: Topical application of Licorice root hydroalcoholic extract at higher concentrations than 8% accelerated the wound healing process, and increased the contraction and shrinkage of the burn. Licorice root extract inhibited the growth of *Staphylococcus aureus* and *Pseudomonas aeruginosa* without any inhibitory effect on the growth of *Acinetobacter baumannii*.

Conclusion: Licorice is a promising remedy for accelerating wound healing in skin burns.

Keywords: Licorice, *Glycyrrhiza Glabra*, Wound Healing, Burn, Skin, Anti-Bacterial, Rats

Introduction

Burn is one of the most common injuries worldwide. Different types of burn by heat, electricity, chemicals, or radioactive materials cause damages to skin, muscles, mucosa, or air ways [1].

In the United States, more than one million burn victims require medical care, and about 45,000 of them need to be hospitalized each year. In the UK burns account for 1% of the workload and 0.014% of hospital admissions [2].

Burns are divided into four types based on the severity of skin

damage. In the first-degree burn, only skin epidermis is involved and the burn site becomes red and swollen. While skin damage affects the dermis in addition to epidermis, second-degree burn occurs with painful blisters. All of the skin layers are damaged in third-degree burn and the muscles, tendons, or bone, involve in fourth-degree burn [3].

Management of burns includes non-pharmacological and pharmacological interventions including cooling, wound washing in chemical burns, wound dressing, prescribing analgesics, and so on [4].

The healing of burn wounds significantly depends on the bacterial infection of the burn site. Topical silver sulfadiazine commonly is used as a topical antimicrobial substance in burns. It improves infected wounds, nevertheless, it delays the establishment of epidermis and prolongs the recovery period [5]. There are some botanical application of herbal medicines to improve (deleted) for wound healing in burns [6, 7].

Licorice (glycyrrhiza glabra) root and rootstock extract is used in Iranian traditional medicine to treat skin burns. *Licorice* root and rootstock contains glycyrrhizin, glycyrrhizic acid, potassium and calcium salts, coumarin, flavones, volatile oils, herbal sterols, high amounts of glucose, sucrose, asparagine, albumin, resins, essential oils, flavonoids, licoflavanol, glabrone, glabridin (anti-Oxidant), and lycoricidine [8]. *Licorice* root extract is effective against some species of streptococcus, staphylococcus, HIV, hepatitis A, and herpes infections [9]. Furthermore, glabridin (found in the plant roots) is utilized for anti-inflammatory, anti-scar and anti-microbial purposes [10]. We aimed to evaluate the effect of hydroalcoholic *Licorice* root extract on the histopathologic parameters in second- and third-degree burns in rats.

Materials and Methods

Licorice Root Extract Preparation

The dried *Licorice* root were obtained from medicinal plants market of Yazd, Iran. The scientific name and the quality were confirmed with a quality assurance number was obtained from the Faculty of Pharmacy, Shahid Sadoughi University of Medical Sciences (SSU0042). *Licorice* root was pulverized by a mill and then the *licorice* hydroalcoholic root extract was obtained by percolation method. The dry extract was prepared by evaporating the solvent at 40°C and it was standardized. The different concentrations of the extract (8, 11, 14, 17, 20 and 23%) were prepared by normal saline as a solvent.

Animals

Ninety-six healthy male Wistar rats (200–250g) were purchased of the animal house of Shahid Sadoughi University of Medical Sciences, Yazd, Iran. The rats were housed in groups of 6 in temperature and humidity-controlled room (20–23°C, 50–60%) with a 12 hours light/dark cycle and free access to standard food and water. The animals were kept and handled according to the local guidelines of care and work with laboratory animals in Shahid Sadoughi University of Medical Sciences (IR.SSU.MEDICINE.REC.1398.055).

Burn Induction

Experimental burn was induced according to Shanmoga method with some modifications [11].

The dorsal skin in the rats was burned under general anesthesia with intraperitoneal (i.p.) injections of ketamine hydrochloride (50 mg/kg - ROTEXMEDICA- Germany) and xylazine (10 mg/kg -Westberg) by a metal plate (2 cm in diameter).

The hairs behind the rats were shaved and uniform second- (upper epidermis) and third-degree burns (Hypodermis) were induced. They were performed using a stainless-steel device at a temperature of 100°C for 8- and 13-seconds skin contact, respectively according to the histopathological parameters (Figure 1).

The freshly prepared extract was applied to the burn site twice a day for 21 days since the first day of the burn induction.

Eight separate groups of rats (n=6) were considered for each type of burn. Control group: The rats were treated with normal saline topically. Positive control group: Treatment was performed by topical silver sulfadiazine cream 1%. Experimental groups: The rats were treated with the different concentrations of *Licorice* root hydroalcoholic extract (8, 14, 17, 20 and 23%).

The animals were kept in separate cages with free access to food and water and treated twice a day for 21 days. They were weighted weekly. Eventually, the rats were sacrificed and the entire layer of burnt skin was removed and maintained in a 10% formalin for histopathological examinations.

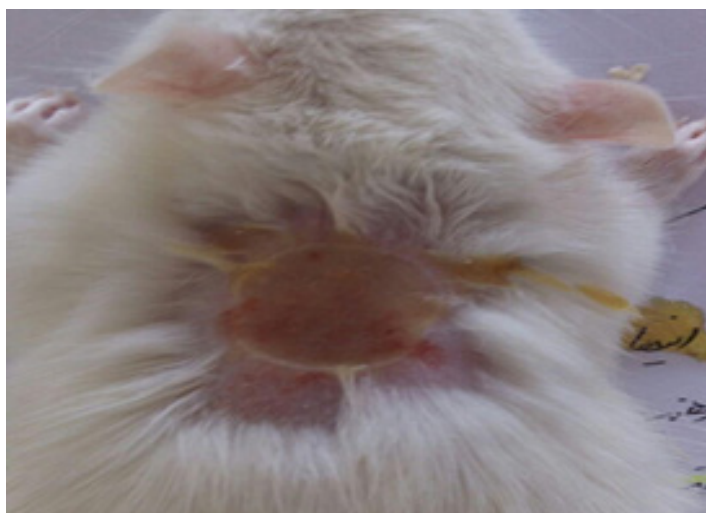


Figure 1: Burns induced on the skin behind the rats.

Histopathological Evaluation

The skin samples were fixed in 10% formalin, and in the tissue processing system, different stages of dehydration, clarification with xylol and paraffinization were performed.

Sections with a thickness of 5-6 microns were prepared from the tissue, and placed in water and alcohol to remove the wrinkles. Then the specimens were drained off with a lam dipped in albumin-glycerin glue.

Coloring was done by hematoxylin and eosin. Then the histopathologic criteria including epithelialization, angiogenesis, collagen formation, polymorphonuclears (PMNs) migration and wound contraction were scored (1 to 10 scores) under an optical microscope with a magnification of 10 and 40 times in blind condition.

Antibacterial Test

Staphylococcus aureus, *Pseudomonas aeruginosa* and *Acinetobacter baumannii* were removed from freezing medium, set in room temperature, cultured on nutrient agar medium using lawn culture method and incubated at 37°C for 24 hours.

McFarland Standard is used to standardize the approximate number of bacteria (1.5×10^8) and cultured on Mueller-Hinton agar (MHA).

Ten wells were made on MHA culture using sterile Pasteur pipette. The bottom of the plates was covered with MHA medium. Different concentrations of the extract transferred to the wells containing bacteria and MHA. The plates were incubated at 37°C for 24 hours.

Statistical Analysis

Data are expressed as mean ± S.E.M which were analyzed by one-way analysis of variance (ANOVA) followed by Tukey's post hoc test. All statistical analyses were made by using SPSS software (version 19).

Results

The weight of the animals did not change significantly during the study. From the second day, their behavior was normal in all groups. Histological images have shown in the figures 2-5.

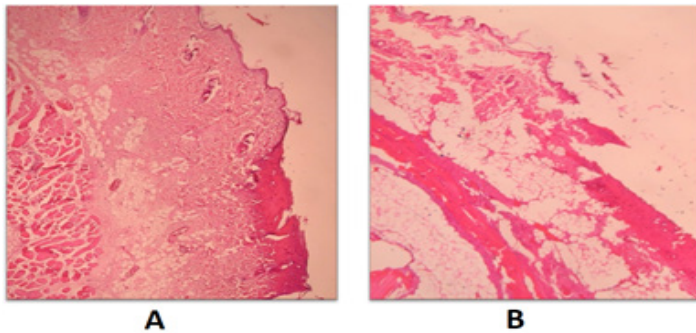


Figure 2: Histopathological presentation of second-degree (A) and third-degree (B) burnt skin in rats in the control groups. There are severe angiogenesis, thin epidermis or areas without epidermis and a large number of PMNs.

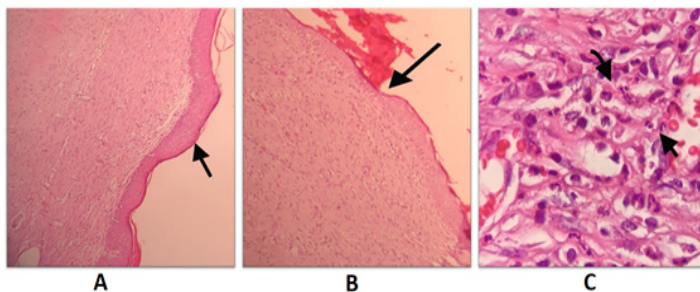


Figure 3: Histopathological presentation of burnt skin in rats in *Licorice* root hydroalcoholic extract groups after 21 days of treatment. A: second-degree burn group; thick and complete epithelialization. B: third-degree burn group; thin and complete epithelialization. C: third-degree burn group; a large number of PMNs.

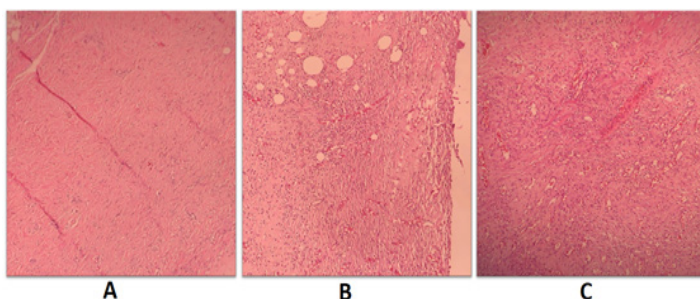


Figure 4: Histopathological presentation of burnt skin in rats in *Licorice* root hydroalcoholic extract groups after 21 days of

treatment. A: second-degree burn group; mild angiogenesis. B: third-degree burn group; moderate angiogenesis. C: third-degree burn group; severe angiogenesis.

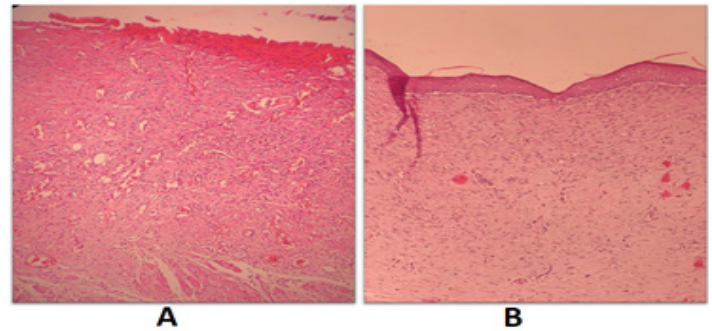


Figure 5: Histopathological presentation of burnt skin in rats after 21 days of treatment. A: third-degree burn group treated with normal saline; without epithelialization, severe angiogenesis, a large number of PMNs and amorphous collagen. B: second-degree burn group treated with *Licorice* root hydroalcoholic extract; complete epithelialization, mild angiogenesis, a low number of PMNs and disorganized collagen.

Polymorphonuclears Migration

Polymorphonuclears migration was scored according to: PMNs count ≥ 40, score = 0; 10 < PMNs < 40, score = 1 and PMNs count < 10, score = 2.

Licorice root hydroalcoholic extract 11% showed a significant difference compared to control group in second-degree burn. *Licorice* root extract in concentrations of 11, 17, 20 and 23% inhibited PMNs migration more than silver sulfadiazine 1% cream (P < 0.05). In all the concentrations, *Licorice* inhibited PMNs migration in third-degree burn (P < 0.05) (figure 6).

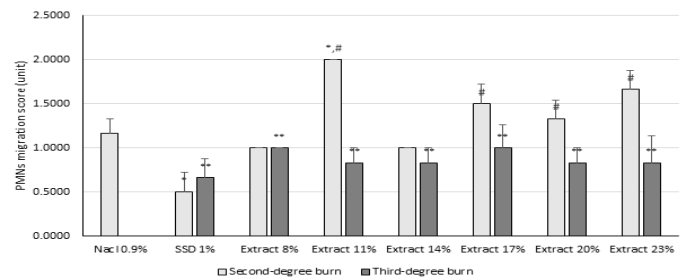


Figure 6: Effect of *Glycyrrhiza glabra* root hydroalcoholic extract on polymorphonuclears (PMNs) migration. Data are analyzed as mean ± S.E.M, (n=6). *P < 0.05 compared to control (NaCl 0.9%) in second-degree burn, #P < 0.05 compared to silver sulfadiazine (SSD) 1% cream, **P < 0.05 compared to control in third-degree burn. One-way ANOVA followed by Tukey's post hoc test.

Collagen Formation

Both *Licorice* in all applied concentrations and normal saline induced collagen formation in both second- and third-degree burns. In all of the groups, collagen formation was induced more than silver sulfadiazine (P < 0.05) in second-degree burn (figure 7).

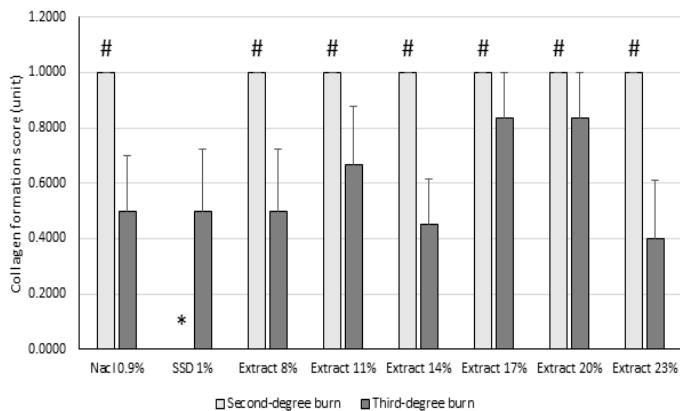


Figure 6: Effect of *Glycyrrhiza glabra* root hydroalcoholic extract on collagen formation. Data are analyzed as mean \pm S.E.M, (n=6). *P<0.05 compared to control (NaCl 0.9%), #P<0.05 compared to silver sulfadiazine (SSD) 1% cream. one-way ANOVA followed by Tukey's post hoc test.

Epithelialization

Licorice root hydroalcoholic extract (17, 20 and 23%) increased epithelialization in second-degree burn compared to both of normal saline and silver sulfadiazine 1% cream. Concentration of 20% showed the best effect. There was no increase in epithelialization in third-degree burn (P<0.05) (figure 8).

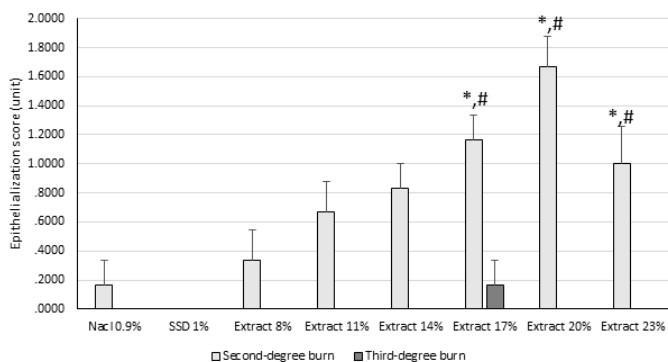


Figure 8: Effect of *Glycyrrhiza glabra* root hydroalcoholic extract on epithelialization. Data are analyzed as mean \pm S.E.M, (n=6). *P<0.05 compared to control (NaCl 0.9%) group, #P<0.05 compared to silver sulfadiazine (SSD) 1% cream. one-way ANOVA followed by Tukey's post hoc test.

Angiogenesis

Licorice root hydroalcoholic extract 14% and 23% inhibited angiogenesis in compared to normal saline in second-degree burn.

There was no significant reduction in angiogenesis in third-degree burn in control and treatment groups (figure 9).

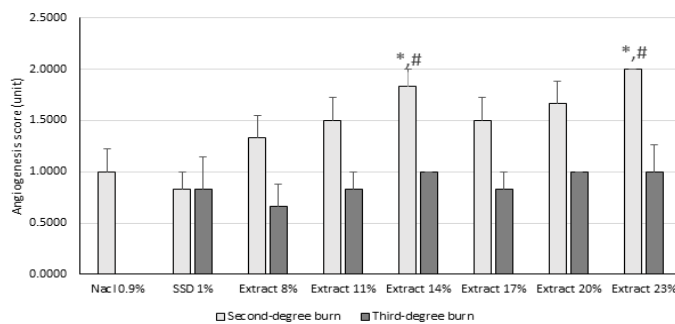


Figure 9: Effect of *Glycyrrhiza glabra* root hydroalcoholic extract on angiogenesis. Data are analyzed as mean \pm S.E.M, (n=6). *P<0.05 compared to control (NaCl 0.9%) group, #P<0.05 compared to silver sulfadiazine (SSD) 1% cream. one-way ANOVA followed by Tukey's post hoc test.

Skin Contraction

Skin contraction is the portion of epithelialization of burnt area. Some concentrations of *Licorice* root extract (14-23%) increased skin contraction compared to both control and silver sulfadiazine 1% cream (figure 10).

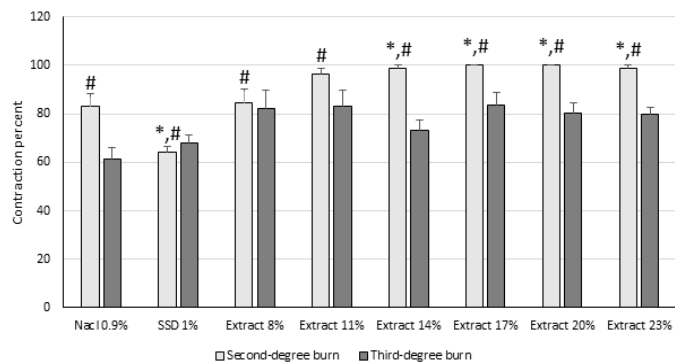


Figure 10: Effect of *Glycyrrhiza glabra* hydroalcoholic root extract on skin contraction. Data are analyzed as mean \pm S.E.M, (n=6). *P<0.05 compared to control (NaCl 0.9%) group, #P<0.05 compared to silver sulfadiazine (SSD) 1% cream. one-way ANOVA followed by Tukey's post hoc test.

Total Score

Total score was calculated from all of the histopathological scores. *Licorice* root extract (>11%) improved total score in second-degree burn. Silver sulfadiazine decreased total score compared to control group. There was no significant difference between the groups in third-degree burn (figure 11).

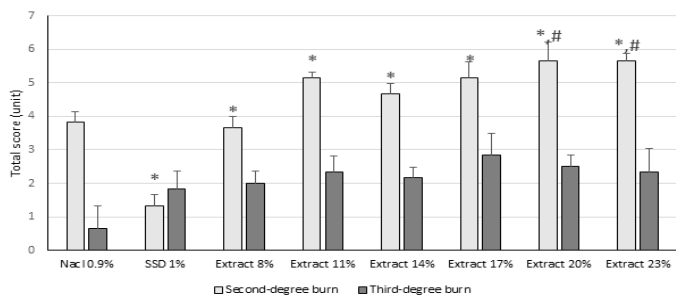


Figure 11: Effect of *Glycyrrhiza glabra* hydroalcoholic root extract on total score of wound healing. Data are analyzed as mean \pm S.E.M, (n=6). *P<0.05 compared to control (NaCl 0.9%) group, #P<0.05 compared to silver sulfadiazine (SSD) 1% cream. one-way ANOVA followed by Tukey's post hoc test.

Anti-Bacterial Effects

A brief evaluation showed *Licorice* root hydroalcoholic extract has anti-bacterial effects against some of the bacteria. It had no effect against *Acinetobacter baumani* (figure 12).

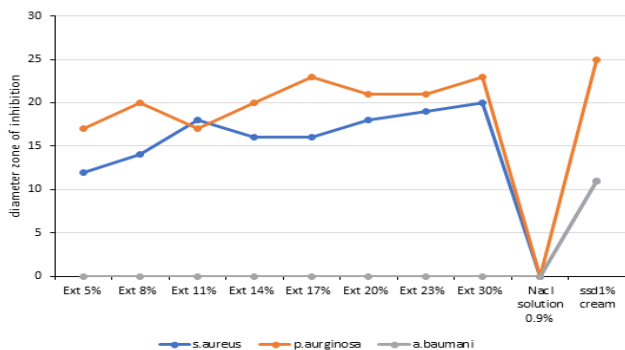


Figure 12: Effects of the various compounds against the bacteria. EXT, *Licorice* root extract; ssd, silver sulfadiazine.

Discussion

Skin injuries can be caused by a variety of causes, such as burns, surgery, trauma, and etc. The process of skin repair is similar in all of these skin lesions [12].

Wound healing is accomplished in three steps including inflammatory, cell proliferation, and remodeling. The inflammatory phase in which leukocytes, especially neutrophils, penetrate the damaged tissue, the cell proliferation phase in which fibroblasts, keratinocytes, epithelial, and endothelial cells, grow, proliferate, and reproduce the extracellular matrix and granular tissue at the site of the wound, and eventually, remodeling phase, in which angiogenesis, collagen accumulation and crosslinking, granulation and fibroplasia formation, and then epithelial layer formation, contraction, and shrinkage occur. In the wound healing process, each of these steps does not begin with the completion of another step, but overlaps [13].

In general, the wound healing process lasts 3-4 months, and if completely healed, 70% of the skin will be repaired (not the hair follicles or blood vessels). Disorganized collagens will be seen after 21 days, and linear collagens after 3-4 months [14]. The process of wound healing is directly related to the reduction of PMNs, mild

angiogenesis, and increased collagen levels and epithelialization [15].

Penetration of microorganisms into deep layers of damaged skin and subsequent infections is one of the most important reasons for the delay in the healing process of burn wounds [16].

Glycyrrhizic acid, is one of the most abundant compounds in *licorice* extract. Glycyrrhizic acid belongs to the saponins, has a structure similar to adrenal secreted glucocorticoids, and in addition to its anti-inflammatory properties, also has antibacterial properties [17, 18]. This property allows it to accelerate the healing process of burn wound by inhibiting the proliferation of microorganisms [19]. The flavones in *licorice* extract are also anti-inflammatory compounds that can reduce wound inflammation and accelerate wound healing [20]. Isoliquiritigenin (ILTG), a flavonoid found in *licorice*, shows a clear inhibitory effect on COX-2 and iNOS and decreases PGE2 [21]. The *licorice* root derived isoflavan glabridin increases the function of osteoblastic MC3T3-E1 cells, and induces collagen formation [22].

The results of this study show that topical application of *licorice* root hydroalcoholic extract in concentrations higher than 8% not only inhibit the growth of some skin pathogens in burn, but also accelerate the wound healing process in burns. *Licorice* increased skin contraction and shrinkage by affecting the wound healing factors. Accordingly, the best results were observed at concentrations of 20% and 23%. The anti-inflammatory and antimicrobial effects of *Licorice* contents such as Glycyrrhizic acid, Isoliquiritigenin and glabridin can accelerate the healing process of burn wounds.

Conclusion

The findings show that the hydroalcoholic extract of *Glycyrrhiza glabra* (*Licorice*) root has positive effects on the healing process of wound in second-degree burns. Considering the antibacterial effects of this herbal medicine, it can be a promise to clinical use in skin burns.

References

- Li H, Tan J, Zhou J, Yuan Z, Zhang J, et al. (2017) Wound management and outcome of 595 electrical burns in a major burn center. *Journal of surgical research* 214: 182-189.
- Pruitt B, Wolf SE, Mason A (2012) Epidemiological, demographic, and outcome characteristics of burn injury. *Total burn care* 4: 15-45.
- Meckler G, Quereshi N, Al-Mogbil M, Kentab O (2016) Tintinalli's emergency medicine: a comprehensive study guide. New York: McGraw-Hill.
- Marx J, Walls R, Hockberger R (2013) *Rosen's Emergency Medicine-Concepts and Clinical Practice E-Book*: Elsevier Health Sciences.
- De Gracia C (2001) An open study comparing topical silver sulfadiazine and topical silver sulfadiazine-cerium nitrate in the treatment of moderate and severe burns. *Burns* 27: 67-74.
- Ayyanar M, Ignacimuthu S (2009) Herbal medicines for wound healing among tribal people in Southern India: Ethnobotanical and Scientific evidences. *International Journal of Applied Research in Natural Products* 2: 29-42.
- Maver T, Maver U, Stana Kleinschek K, Smrke DM, Kreft S (2015) A review of herbal medicines in wound healing. *Inter-*

- national journal of dermatology 54: 740-51.
8. Chin YW, Jung HA, Liu Y, Su BN, Castoro JA, et al. (2007) Anti-oxidant constituents of the roots and stolons of licorice (*Glycyrrhiza glabra*). Journal of agricultural and food chemistry 55: 4691-4697.
 9. Gupta VK, Fatima A, Faridi U, Negi AS, Shanker K, et al. (2008) Antimicrobial potential of *Glycyrrhiza glabra* roots. Journal of ethnopharmacology 116: 377-380.
 10. Račková L, Jančinová V, Petříková M, Drábíková K, Nosál R, et al. (2007) Mechanism of anti-inflammatory action of liquorice extract and glycyrrhizin. Natural product research 21: 1234-1241.
 11. Priya KS, Gnanamani A, Radhakrishnan N, Babu M (2002) Healing potential of *Datura alba* on burn wounds in albino rats. Journal of ethnopharmacology 83: 193-199.
 12. Sharabiani MT, Aylin P, Bottle A (2012) Systematic review of comorbidity indices for administrative data. Medical care 2012: 1109-1118.
 13. Li J, Chen J, Kirsner R (2007) Pathophysiology of acute wound healing. Clinics in dermatology 25: 9-18.
 14. Gourdie RG, Potts JD (2013) Compositions and methods for tissue engineering, tissue regeneration and wound healing. Google Patents.
 15. Schreml S, Szeimies R-M, Prantl L, Landthaler M, Babilas P (2010) Wound healing in the 21st century. Journal of the American Academy of Dermatology 63: 866-881.
 16. Edwards R, Harding KG (2004) Bacteria and wound healing. Current opinion in infectious diseases 17: 91-96.
 17. Parvaiz M, Hussain K, Khalid S, Hussain N, Iram N, et al. (2014) A review: Medicinal importance of *Glycyrrhiza glabra* L.(Fabaceae family). Global J Pharmacol 8: 8-13.
 18. Kim HK, Park Y, Kim HN, Choi BH, Jeong HG, et al. (2002) Antimicrobial mechanism of β -glycyrrhetic acid isolated from licorice, *Glycyrrhiza glabra*. Biotechnology letters 24: 1899-1902.
 19. Cazander G, Jukema GN, Nibbering PH (2012) Complement activation and inhibition in wound healing. Clinical and Developmental Immunology.
 20. García-Lafuente A, Guillamón E, Villares A, Rostagno MA, Martínez JA (2009) Flavonoids as anti-inflammatory agents: implications in cancer and cardiovascular disease. Inflammation Research 58: 537-552.
 21. Takahashi T, Takasuka N, Iigo M, Baba M, Nishino H, et al. (2009) Isoliquiritigenin, a flavonoid from licorice, reduces prostaglandin E2 and nitric oxide, causes apoptosis, and suppresses aberrant crypt foci development. Cancer science 95: 448-453.
 22. Choi E-M (2005) The licorice root derived isoflavan glabridin increases the function of osteoblastic MC3T3-E1 cells. Biochemical pharmacology 70: 363-368.

Copyright: ©2021 Mohsen Zabihi, et al. This is an open-access article distributed under the terms of the Creative Commons Attribution License, which permits unrestricted use, distribution, and reproduction in any medium, provided the original author and source are credited.