

## Lichen Planus and Its Management: An Update and Observation

Mohammad A Hye \*

Department of Dermatology, Jalalabad Ragib-Rabeya Medical College, Ragib-Rabeya Medical College Road, Patantula, Sylhet-3100, Bangladesh

## \*Corresponding author

Mohammad A Hye, Professor, Department of Dermatology, Jalalabad Ragib-Rabeya Medical College, Ragib-Rabeya Medical College Road, Patantula, Sylhet-3100, Bangladesh, Tel: +88 01711737043; E-mail: mohammadhye@hotmail.com

Submitted: 19 Dec 2017; Accepted: 26 Dec 2017; Published: 05 Jan 2018

## Abstract

Lichen planus (LP) is an inflammatory muco-cutaneous disease characterised by shiny, flat-topped papules and plaques. It affects around 1% of the population. The disease is usually self-limiting and benign in nature. However, some varieties of LP may cause considerable discomfort and recalcitrant in nature. So, treatment depends on appreciating the type, severity and nature of the disease. There are a good numbers of options for treating different types of LP. Few types of LP are difficult to treat and needs aggressive treatment to prevent complications like hair or nail loss. Author examined and summarized the published literature involving the treatment or management of LP. It is found that the large scale, evidence based trials are only few in number. At present, it is quite difficult to standardisation of treatment. This review outlines the ongoing trial and current treatment options. It is needed to assimilation and summarization of the recent findings to treat the critical cases in a more effective way.

## Introduction

Lichen planus is a distinctive entity in dermatology due to its characteristic violaceous, flat-topped papules with Wickham's striae on the surfaces of lesions. It involves mucous membranes in a significant proportion of patients; only mucous membrane involvement is not uncommon. As a sole manifestation of LP, oral disease make up 15- 35% of the patient group, but up to 65% of patients with classical cutaneous LP have concomitant oral disease. LP can affect the mucosal surfaces of the mouth, vagina, oesophagus, conjunctiva, urethra, anus, nose and larynx Hair and nail involvement is also present but not common [1].

## Histopathology

LP has distinct histopathological features [Fig.1]

- A band like cell infiltrate in upper dermis
- Basal cell damage. Mainly T cells are present in cell infiltrate.

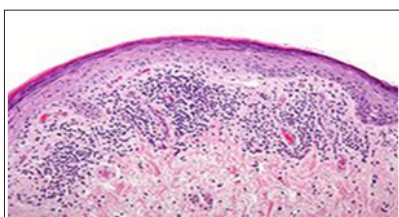


Figure1: Histopathology of Lichen planus

## Prevalence

The prevalence of lichen planus (LP) is estimated at around 1%. Erasmus Wilson (1869) in his lecture notes mentioned that LP was an uncommon disease. He found only 51 cases among 10,000 of all types of skin diseases within a period of 5 years [2-4].

## Pathogenesis

## Pathogenesis of LP still remains elusive

There is now a general consensus that LP is an immunologically-mediated disease, where basal cell damage occurs due to a complex interaction between keratinocytes, Langerhan's cells and T cells [5]. Drugs as causative agents or triggering factors of LP were considered in the 1920s. In 1929, Lortab-Jacob proposed that lichenoid eruption was secondary to arsenic used in the treatment of syphilis [6].

The importance of drugs became evident during World War II following development of large numbers of LP in servicemen taking antimalarial drugs [7]. The list of drugs, which are reported in the literature as causative agents of LP [8].

**Table 1:** The list of drugs, which are reported in the literature as causative agents of LDE.

Common inducer of LDE	Less common inducer of LDE
Gold	Captopril
Methyldopa	Naproxen
β Adrenergic blocking agents	Dapsone
Penicillamine	Arsenicals
Quinidine	Iodides
The list of drugs, which are reported in the literature as causative agents of LDE*.	Phenothiazine derivatives
Synthetic antimalarial	5-Fluorouracil
Ethambutol	Chloropropamide
Furosemide	Streptomycin
Spirolactone	Ca++ channel blocker
Thiazide diuretics	Sulphonyl urea
	Ketoconazole
	Tetracycline
	Carbamazine

### Associated conditions

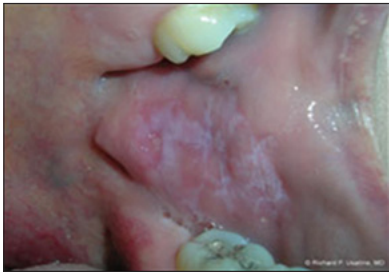The link between LP and chronic hepatitis C (HCV) continues to be investigated and debated. Chronic HCV infection has been reported in 20 to 38 % of patient with oral and / or cutaneous LP, in a report while other studies do not substantiate any link [9,10]. The review from the Mayo clinic suggests that patients with either the onset or exacerbation of LP, should be assessed for HCV\*.

### Treatment

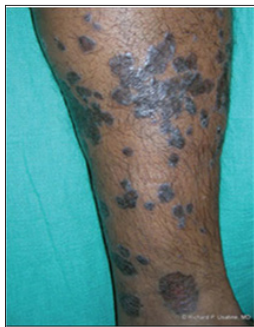LP is usually a self-limiting benign disease some form of the disease may persist for a long duration and may cause a range of morbidity. Treatment depends on appreciation of the following:

- Severity of symptoms.
- Natural course of the disease.
- Triggering factors
- Associated conditions
- Complications of disease.

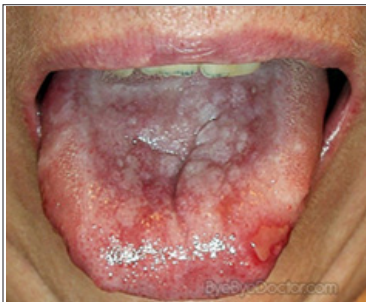In general, spontaneous remission of cutaneous LP after one year occurs in 64% to 68% of patients [11]. Cutaneous LP with involvement of mucous membrane [Fig.1] persists longer. The reported mean duration of oral LP is about 5 years, while the erosive form of oral LP may not spontaneously resolve.



**Figure 1:** Oral LP  
Some variants of LP may cause considerable discomfort.

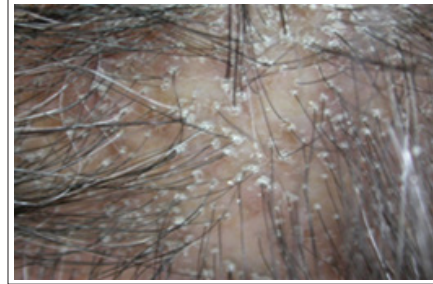

**Figure 2:** Hipertrophic LP  
Hypertrophic LP [Fig.2] is more pruritic than the usual cutaneous LP.

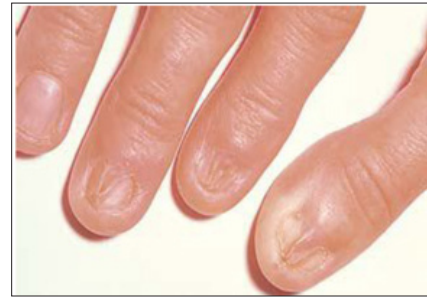

**Figure 3:** Oral erosive LP

The erosive type of oral LP [Fig.3] is very painful and may cause difficulty in eating.



**Figure 4:** Lichen Planu-pilaris  
Lichen plano-pilaris [Fig4] and lichen planus of nails [Fig.5] are important for their probable complications of scarring alopecia and loss of nails respectively.



**Figure 5:** Nail LP

More aggressive forms of treatment are needed for the following variants of LP---

- Erosive LP,
- Hypertrophic LP,
- Lichen plano-pilaris and
- LP of nails.
- LP in Genital Organ

Various drugs and physical treatments have been proposed. The development of new medications and different uses of older drugs gives patients with these diseases numerous therapeutic options. Since the time of Erasmus Wilson (1869), different form of treatment of LP have been tried but none has proved to be curative. Wilson treated his patients with arsenic, bitters, quinine etc. Arsenic was regarded as a miracle drug in the past, but now a days, its use is not supported by dermatologists. Standard therapy for LP includes topical and systemic steroids, retinoids and PUVA.

Many patients with uncomplicated diseases respond to these medications, those who do not improve may require different therapies. Avoidance of exacerbating drugs unless necessary, and minimizing trauma to skin and mucosal tissue are routinely recommended.

### Corticosteroid

Corticosteroids remain the most widely used treatment in LP. They have been found to be effective in both cutaneous and oral lichen planus. Systemic, intralesional and topical steroids including creams, ointments and pesseries have been used. Prednisolone has been found to has good results in the treatment of LP and may result in sustained remission after successful tapering of the dosage. A prednisolone dosage of 30-60mg/day is recommended. The mean

duration of treatment is 6 weeks [12]. Different dosage regimens have also been proposed. Prednisone 5-10mg/day for 3 to 5 weeks was successful in 3 cases of LP of nails [13].

Megadoses of methylprednisone (1gm intravenously on 3 consecutive days monthly) resulted in a favourable response in a patient with severe resistant LP of skin, genitalia and scalp [14]. In one study, 38 patients with cutaneous LP were treated by either prednisone 30mg/day or placebo; the median time for LP to clear was 18 weeks in the corticosteroid group and 29 weeks in the placebo group [15]. In one study, a Prednisolone dosage of 10 to 50mg/day was successfully used in erosive oral LP [16].

Tapering of dosage or withdrawal of the drugs can cause relapse or flare up of disease. In such cases, addition of other drugs may be helpful. Camisa, et al. reported the beneficial effect of dapson in controlling disease, which relapsed on lowering of the dose of prednisolone [17]. Acitretin has been used in association with steroids to bring the disease into remission [18].

### Topical Steroids

Topical corticosteroids are widely used drugs in the treatment of cutaneous LP. But surprisingly only few clinical trials are available in the medical literature regarding use of them in cutaneous LP. However some good reports have been published on treatment of oral LP. In one study, fluocinolone in an adhesive base, showed good response, compared with placebo group. The efficacy of 0.1% fluocinolone acetonide was tested against that of 0.1% triamcinolone acetonide to treat oral LP in one study [19]. Fluocinolone was found to be more effective than triamcinolone [20]. It has also been reported that betamethasone valerate is also effective in treatment of oral LP [21].

### Intralesional Steroid

Intra dermal injection of triamcinolone acetonide is sometimes helpful in certain variants of LP. It has been reported that 5 mg/ml intradermal injection in the posterior nail fold, given 3 times at an interval of 2 to 4 weeks in 11 patients with LP of the nails resulted in improvement in 7 of them [22].

### Retinoids

According to some authors, retinoids are the first line therapy for treatment of LP. Acitretin has shown a relatively good efficacy in the treatment of LP [23]. A double blind vs. placebo trial was carried out on 65 patients with cutaneous LP [24]. Treatment consisting of 30 mg of acitretin per day for 8 weeks resulted in a good response in 64% of patients, in contrast to 13% in placebo group. Both topical 0.1% tretinoin and 0.1% isotretinoin have been successfully used in the treatment of oral LP but not cutaneous disease [25]. However, after withdrawal of systemic or topical retinoids, recurrence is common [25].

### Cyclosporine

Oral cyclosporine has been used in some uncontrolled clinical trials in severe cutaneous LP resistant to other treatment. In one study, a complete response was obtained with doses ranging from 1 to 6 mg/kg/day without relapse during several months of follow-up [26]. Pruritus disappeared after 1 to 2 weeks of treatment and clearance of the rashes was noted in a mean time of 6 weeks. Due to toxic effects of systemic cyclosporine, local forms of cyclosporine have been tried. Cyclosporine under occlusion has been efficacious for genital and hypertrophic lesions. Cyclosporine (500 mg) rinses for 5

min each day were helpful in oral lichen planus, without significant side effects [27]. However, topical cyclosporine is very expensive and may only be justified in recalcitrant cases.

### Photochemotherapy

Psoralen ultra-violet A (PUVA) photo chemotherapy is usually successful in generalised cutaneous LP. A cure rate of 75% was reported in one open study after 8 weeks of treatment. It has also been shown that bath PUVA therapy is effective in treatment of LP; 11 of 12 patients with resistant LP were cured or significantly improved with bath PUVA therapy [28]. Patients with widespread LP may respond to narrowband or broadband UV-B Therapy [29].

### Griseofulvin

The polyene antifungal griseofulvin has been used for treatment of LP. In one study, 86% of the patients had complete disappearance of lesions after 3 of 6 months of treatment [30]. In another study, griseofulvin was not found to be an agent producing clinical relief [31].

### Metronidazole

Oral metronidazole has been tried for treatment of LP for long. A complete response or significant improvement (78.9%) of generalised LP was observed with metronidazole 500mg twice daily for 20 to 60 days [32].

### Tacrolimus

Therapy with 0.1% topical tacrolimus ointment twice daily for one month led to complete resolution of labial ulceration. Intraoral ulceration also resolved after 3 months of daily application. Both maintained in remission after one year without maintenance therapy [33]. More recently, a dramatic response was observed in 2 cases of severe recalcitrant erosive oral LP within 4 weeks of topical tacrolimus treatment [34].

### Aloe Vera Gel

In a randomized controlled trial, aloe vera gel was found effective in the treatment of oral LP. It is also effective in genital LP [35].

### Laser

Carbon-dioxide laser evaporation was successfully tried in one study in treatment of painful oral lichen planus where topical steroids were unsuccessful [36]. In another study oral lichen planus was successfully treated by using 308-nm excimer laser [37].

### Photodynamic Therapy

Recently, the use of Photodynamic therapy (PDT) has been expanding due to its numerous advantages. Five clinical studies are found in medical literatures regarding treatment of oral LP by PDT. The studies revealed that it is quite effective in the treatment of oral LP [38].

### Sulfasalazine

A randomised double blind study revealed that sulfasalazine at a dose of 2.5 g/day for 6 weeks was very effective in generalized LP [39]. It showed significant improvement in lesions (78%) and pruritus (79%) in patients of generalized LP.

### Apremilast

Apremilast may be effective in treatment for Erosive oral LP but double - blinded controlled trials are lacking [40].

## Methotrexate

Oral methotrexate has been found to be useful in treatment of generalized LP in a recent study [41].

## Antimalarial Drugs

It is reported that oral erosive lichen planus was successfully treated by antimalarial drugs [42].

## Mycophenolate Mofetil

In a recent report, erosive genital lichen planus was successfully managed with mycophenolate mofetil [43].

## Rituximab

Esophageal lichen planus (ELP) is a rare condition with unknown prevalence that can sometimes be underestimated due to the subtle and nonspecific findings. Rituximab, a chimeric monoclonal antibody, was successfully treated in a case of ELP [44].

## Author's observation

Several author tried to standardized the treatment of LP. But it is still a difficult task.

After analysing the recent search in medical literature following recommendations are proposed:

1. Classic cutaneous LP: Topical - Topical steroid, Systemic- Cyclosporine, Griseofulvin, Metronidazole, Dapsone.
2. Heparthrophic LP: Topical-Potent steroid, Systemic- Oral prednisolone, Oral Retinoid. Others -Intralesional Steroid. Oral LP/ Symptomatic LP/Recalcitrant oral LP: Topical- Topical steroid, Topical Retinoid, Topical Tacrolimus, Topical Cyclosporin, Topical Alovera gel. Systemic- Oral Prednisolone, Oral Retinoid, Apremelast, Antimalarial drugs. Others- Photodynamic Therapy, CO2 Laser, 308 excimer laser.
3. Lichen Plano-pilaris: Topical- Potent steroid. Systemic- Oral Prednisolone. Others- Intralesional steroid.
4. LP Nail: Oral Prednisolone. Intralesional steroid.
5. Genital LP: Topical- steroid, Topical Tacrolimus, Topical Cyclosporine, Topical Alo vera. Systemic- Oral steroid, Mycophenolate Mofetil.
6. Oeophageal LP: Systemic steroid. Oral Rutiximab.

## Conclusion

Lichen planus comprises an important aspect of dermatology. This disease has many clinical types and varied outcome with a numbers of complications. Treatment depends on clinical types and extent of complications. In the medical literature, there are numbers of clinical trials and reports, but a good numbers of standard trials are absent. In this paper, there was an initiative to assimilate and summarize the necessary data regarding treatment from the medical literature. But it is very difficult task. *The lot of research works are needed for standardization of treatment*

## References

1. Dilip K, Kachhawa V, Kalla G, Gupta LP (1995) A clinico-aetiological profile of 375 cases of lichen planus. *Ind J Dermatol Venereol Leprol* 61: 276-279.
2. Wilson E (1869) Lectures on cutaneous medicine and diseases of the skin by Erasmus Wilson. *J Cutan Med Dis Skin* 3: 105-132.
3. In India, the prevalence of LP varied slightly in different study. In one report, it was 0.76%\* but in another report it was 1.4%(3).
4. Singh OP, Kanwar AJ (1976) Lichen planus in India. An appraisal of 441 cases. *Int J Dermatol* 15: 752-756.

5. Shegal VN, Regal VL (1974) Lichen planus: on appraisal of 147 cases. *Ind J Dermatol Venereol* 40: 104-106.
6. Shiohara T, Moriya N, Tanaka Y, Arai Y, Hayakawa J, Chiba M, et al. (1988) Immunopathological study of lichenoid skin diseases. Correlation between HLA-DR positive keratinocytes or langerhans cells and epidermotropic T cells. *J Am Acad Dermatol* 18: 67-74.
7. Almeyda J, Levantine A (1971) Drug reactions XVI: Lichenoid drug eruptions. *Br J Dermatol* 85: 604-607.
8. Nisbet T (1945) New cutaneous syndrome occurring in New Guinea and adjacent islands: preliminary report. *Ann Dermatol Syph* 52: 221-225.
9. Daoud SM (1999) editors. *Dermatology in general Medicine*. 5th ed. New York: Macgraw Hill 561-581.
10. Daoud MS, Gibson LE, Daoud S, Rokea A.el-Azhary (1995) Chronic hepatitis C and skin diseases: A review. *Mayo Clin Proc* 70: 559-564.
11. Irvine C, Irvine F, Champion RH (1991) Long term follow up of lichen planus. *Acta Derm Venereol* 71: 242-244.
12. Oliver GF, Winklemann RK (1993) Treatment of lichen planus. *Drugs* 45: 56-65.
13. Scott MJ Jr, Scott MJ (1979) Ungual lichen planus. *Arch Dermatol* 115: 1197-1199.
14. Snyder RA, Schwartz RA, Schneider JS, Elias PM (1982) Intermittent megadoses corticosteroid therapy for generalised lichen planus. *J Am Acad Dermatol* 6: 1089-1090.
15. Kellel JK, Ead RD (1990) Treatment of lichen planus with a short course of oral prednisolone. *Br J Dermatol* 123: 550-551.
16. Silver S, Lozada-Nur F, Migliorati C (1985) Clinical efficacy of prednisone in the treatment of patients with oral inflammatory oral diseases: a study of 55 patients. *Oral Surg Oral Med Oral Pathol* 59: 360-363.
17. Camisa C, Neff JC, Rossana C, Barrett JL (1986) Diagnosis by immunofluorescence and treatment with dapsone. *J Am Acad Dermatol* 14: 464-469.
18. It in PH, Schiller P, Gilli L (1994) Isolated LP of the lips. *Br J Dermatol* 132: 1000-1002.
19. Voute AB, Schulten EA, Langendijk PN, Kostense PJ, van der Waal I, et al. (1993) Fluocinonide in an adhesive base for the treatment of oral lichen planus: A double blind placebo controlled clinical study. *Oral Surg Oral Med Oral Pathol* 75: 181-185.
20. Thongprason K, Luangjarmekorn L, Sererat T, Taweasap W (1992) Relative efficacy of fluocinonide compared with trimcinolone acetonide in treatment of oral lichen planus. *J Oral Pathol Med* 21: 456-458.
21. Cawson RA (1968) Treatment of oral lichen planus with betamethasone. *BMJ* 1: 86-89.
22. Abell E, Samman PD (1973) Intradermal triamcinolone treatment of nail dystrophies. *Br J Dermatol* 89: 191-197.
23. Cribier B, Frances C, Chosidow O (1998) Treatment of Lichen planus. Evidence-based medicine analysis of efficacy. *Arch Dermatol* 134: 1521-1528.
24. Ortenne JP, Thivolet J, Sannwald C (1978) Oral photochemotherapy in the treatment of Lichen planus. *Br J Dermatol* 99: 315-318.
25. Cribier B, Frances C, Chosidow O (1998) Treatment of Lichen planus. Evidence-based medicine analysis of efficacy. *Arch Dermatol* 134: 1521-1528.
26. Higgins EM, Munro CS, Friedmann PS (1989) Cyclosporin A in the treatment of Lichen Planus. *Arch Dermatol* 125: 1436.
27. Eisen D (1990) Effect of topical cyclosporine rinse on oral

- lichen planus. A double blind analysis. N Engl J Med 323: 290.
28. Kersher M, Volkenandt M, Lehmann P, Plewig G, Röcken M (1995) PUVA-bath photochemotherapy in Lichen Planus. Arch Dermatol 131: 1210-1211.
  29. Pavlotsky F, Nathanson N, Kriger G, Shpiro D, Trau H (2008) Ultraviolet B treatment for cutaneous LP : our experience with 50 patients. Photodermatol Pfotoimminol Photomed 24: 83-86.
  30. Levy A, Stempler D, Yzuc S (1986) Treatment of lichen planus using griseofulvin. Int J Dermatol 25: 405.
  31. Massa MC, Rogers RS (1981) Griseofulvin therapy of lichen planus. Acta Derma Venereol 61: 547-550.
  32. Buyuk AY, Kavala M (2000) Oral metronidazole treatment of LP. J Am Acad Dermatol 43: 260-262.
  33. Lener EV, Brieva J, Schachter M, West LE, West DP, et al. (2001) Successful treatment of erosive LP with topical tacrolimus .Arch Dermatol 137: 419-422.
  34. Shichinohe R, Shibaki A, Nishie W, Tateishi Y, Shimizu H, et al. (2006) Successful treatment of severe recalcitrant erosive oral lichen planus with topical tacrolimus. Eur J Dermatol 20: 66-68.
  35. Choonhakarn C, Busaracome P, Sripanidkulchai B, Sarakarn P (2008) The efficacy of aloe vera l gel in he treatment of oral lichen planus, a randimized cotro[lled trial. Br J Dermatol 158: 573-577.
  36. Van der Ham PS, Egges M, van der Wal JE, Roodenburg JL (2008) CO2 laser evaporation in oral lichen planus. Int J of Oral Maxilifac Sur 37: 630-633.
  37. Liu Wei- Bing WB, Sun LW, Yang H, Wang YF (2017) Treatment of oral lichen planus using 308-nm excimer laser. Dermatol Ther 28833900.
  38. Mostafa Diana (2015) D J Clin Med Res 7: 393-399.
  39. Fazel N (2015) Cutaneous Lichen Planus: A Systemic review of treatments. J Dermatolog Treat 26: 280-283.
  40. Abu Hilal M, Walsh S, Shear N (2016) Treatment of recalcitrant oral lichen planus and desquamative gingivitis with oral apremilast. J Dermatol Case Rep 10: 56-57.
  41. Kanwar A, De D (2013) Methotrexate for treatment of lichen planus: old drug, new indication. J Eur Acad Dermatol Venerol 27: 410-413.
  42. Rivas-Tolosa Navcy N, Requena C, Llombart B, Alcalá R, Serra-Guillén C, et al. (2016) Antimalarial drugs for the treatment of Oral Erosive Lichen Planus. Dermatology 232: 86-90.
  43. Rivas-Tolosa Navcy N, Requena C, Llombart B, Alcalá R, Serra-Guillén C, et al. (2016) Antimalarial drugs for the treatment of Oral Erosive Lichen Planus. Dermatology 232: 86-90.
  44. Deen K (2015) J dermatol 42: 311-314.
  45. Goñi Esarte S, Arín Letamendía A, Vila Costas JJ, Jiménez Pérez FJ, Ruiz-Clavijo García D, et al. (2013) Rituximab in rescue therapy in refractory esophageal lichen planus. Gastroynterol Hepatol 36: 264-267.

**Copyright:** ©2018 Mohammad A Hye. This is an open-access article distributed under the terms of the Creative Commons Attribution License, which permits unrestricted use, distribution, and reproduction in any medium, provided the original author and source are credited.