

# Lemierre Syndrome: A Forgotten Disease, Complicated by Nocardial Necrotizing Fasciitis and Pyomyositis of Right Calf

Richmond Ronald Gomes

Associate Professor, Medicine, Ad-din Women's Medical College Hospital, Dhaka Bangladesh

## \*Corresponding author

Richmond Ronald Gomes, Associate Professor, Medicine, Ad-din Women's Medical College Hospital, Dhaka Bangladesh.

Submitted: 01 Jan 2022; Accepted: 29 Jan 2022; Published: 12 Feb 2022

**Citation:** Richmond Ronald Gomes. (2022). Lemierre Syndrome: A Forgotten Disease, Complicated by Nocardial Necrotizing Fasciitis and Pyomyositis of Right Calf. *Archives of Infect Diseases & Therapy*, 6(1), 118-123.

## Abstract

Once coined the "Forgotten Disease," Lemierre's syndrome also known as human necrobacillosis is a rare condition that results from oropharyngeal infection with an obligate anaerobic gram-negative bacterium *Fusobacterium necrophorum* characterized by septic thrombophlebitis of the internal jugular vein, high fevers, and metastatic septic emboli. Necrobacillosis is the English term describing the necrotic abscesses associated fusobacterium sepsis. Most cases of *F. necrophorum* occur in association with an antecedent pharyngitis or head/neck infection; We describe an unusual case of necrobacillosis later complicated by lower extremity nocardial pyomyositis and necrotizing fasciitis in a 9-year-old otherwise healthy female child with a history of a preceding pharyngotonsillitis which required incision and drainage with surgical washout in addition to long term systemic broad antibiotics.

**Keywords:** Lemierre Syndrome, *Fusobacterium Necrophorum*, Necrobacillosis, Septic Thrombophlebitis, Pyomyositis

## Introduction

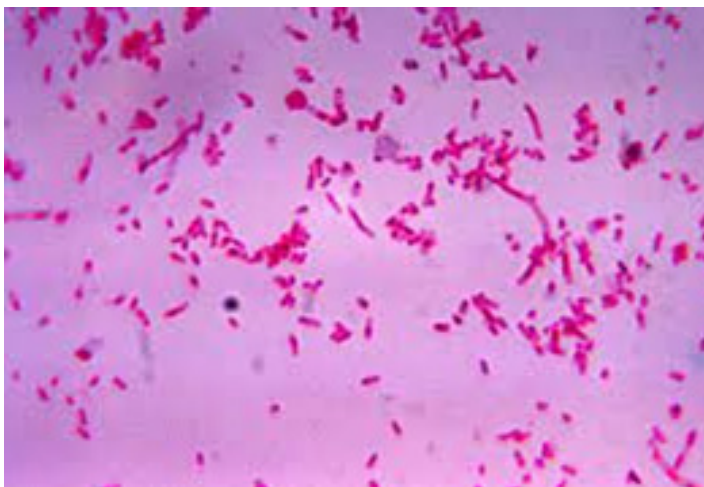Lemierre Syndrome (LS), also known as human necrobacillosis, was first described in 1900 by Courmont and Cadebut in 1936, the French bacteriologist Andre Lemierre published a report detailing the link between septicemia and pharyngitis that he had observed while working at the Claude Bernard Hospital in Paris [1]. The postanginal septicemia which now bears his name is most often precipitated by a suppurative oropharyngeal infection. The infection is typically caused by the gram-negative, anaerobic *Fusobacterium necrophorum*. *Fusobacteria* can be found as normal flora in the upper respiratory tract of humans [2]. Other anaerobic bacteria have been identified as sources of infection, but these are atypical [3]. The disease mostly affects young, otherwise healthy adults. The first symptom is typically a sore throat secondary to exudative tonsillitis or peritonsillar abscess. The infection then spreads into adjacent structures, such as the internal jugular vein and carotid artery. Thrombophlebitis of the neck veins can cause pain, swelling, and dysphagia. Sepsis with complicating metastatic spread of septic micro emboli is the typical progression of illness [4]. The most common site of metastatic spread is the lungs, with 85% of cases demonstrating pulmonary infiltrates [5]. Other feared complications include spread of infection along the carotid sheath and into the mediastinum [4]. Mortality rate before advent of antibiotics was extremely high, with 18 of Andre Lemierre's 20 iden-

tified patients succumbing to their disease [1]. In the modern era of medicine, mortality rates range from 6.4 to 17% [6,7]. Timely recognition and prompt treatment are cornerstone's in prevention of complications.

## Case Report

An otherwise healthy 9-years-old female child from rural Bangladesh presented with 1-week history of sore throat and high fever. The pain was continuous and was radiating to the right ear and the right side of the neck. The pain was aggravated by swallowing both solid and liquid diet. The pain was also aggravated by neck movements. There was no breathing difficulty. 4 days before, she had started amoxicillin by a local physician (250 mg od) for suspected streptococcal acute pharyngotonsillitis, obtaining only partial relief of the throat pain. She denied any recent dental procedures or tooth infections. She had no significant past medical history and was taking no medications. On examination, she was alert, conscious but hypotensive (blood pressure 90/50 mm of Hg), her temperature in the emergency department was 104° Fahrenheit, and her heart rate was 120 beats per minute (bpm), respiratory rate 15 breaths per minute. Neck palpation revealed swollen neck with fullness and tenderness in the anterior and posterior cervical lymph nodes bilaterally. She was unable to open his mouth more than 1.5-2 inches due to pain and swelling. Her oropharynx ap-

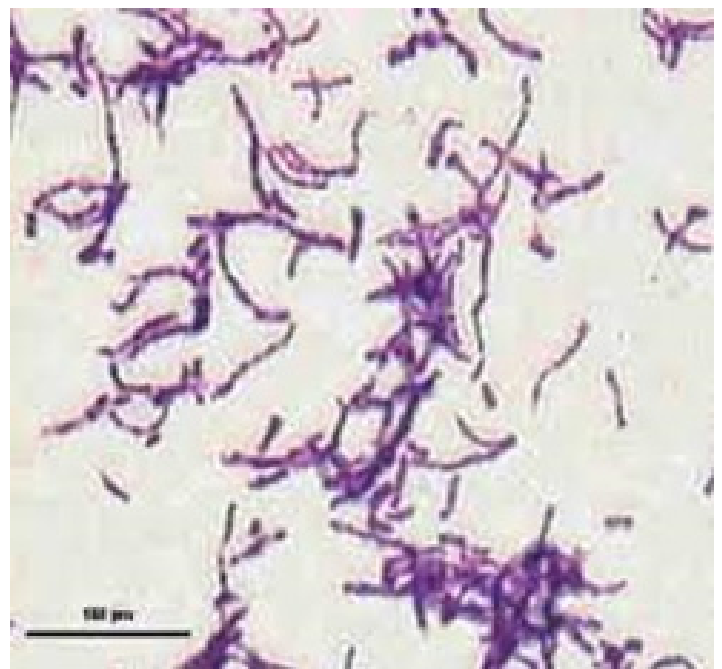
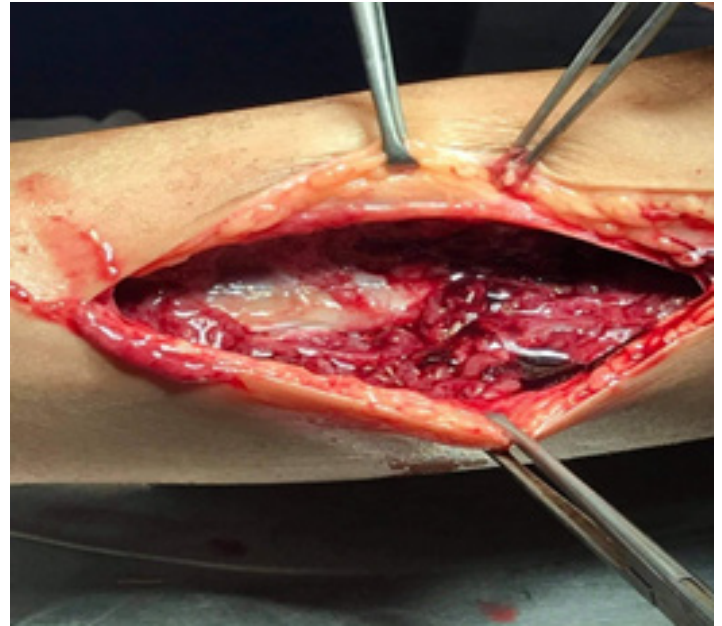
peared erythematous. On respiratory system examination, she had good air entry bilaterally without wheezes or crackles. Laboratory tests showed neutrophilic leukocytosis (white blood cells count  $16.26 \times 10^9/L$ , neutrophils 87%), and elevated C-reactive protein (135.9mg/dL). An unexpectedly high procalcitonin value (29.4 ng/mL) raised the suspicion of bacterial sepsis. Other lab reports were normal: creatinine was 1.03mg/dl, glucose 105mg/dl, albumin low at 2.6, sodium 138 mmol/L, potassium 3.7mmol/L, and alanine aminotransferase (ALT) 30U/L. The chest radiograph showed a right perihilar infiltrate. After drawing blood culture (aerobic, anaerobic culture was not available), an empirical treatment with meropenem was started. Two days later, the patient was still febrile and mildly lethargic, with toxic appearance. Blood culture failed to reveal growth of any organism. A neck ultrasound was performed, showing multiple enlarged cervical lymph nodes, bilateral peritonsillar multiloculated enhancing fluid collections. It also showed punctate foci within the right internal jugular vein, which was thought to represent partial thrombosis. Surgical debridement was done and as wound swab gram stain showed *Fusobacterium necrophorum*, an anaerobic gram-negative rod in Figure 1, intravenous clindamycin was added to meropenem.



**Figure 1:** Gram staining of neck collection showing fusiform gram-negative bacilli (*Fusobacterium necrophorum*)

Five days later, which she noted right calf pain that she attributed to “slipping and hyperextending her ankle”. On local examination Her right calf was moderately swollen compared to the left and was tender. She had good pulses in both dorsalis pedis and posterior tibialis in both legs in addition to full range of motion in his ankles. A right lower extremity ultrasound was ordered due to the pain and swelling in his right calf. This study was negative for deep vein thrombosis. There was edema within the fascial compartments between the gastrocnemius and soleus muscles, as well as in the superficial fascia. A crescent-shaped sub fascial fluid collection was also noted over the medial head of the gastrocnemius muscle, indicative of right lower leg fasciitis. The decision was made to proceed with incision and drainage of the fluid collection, in addition to a debridement of the right leg necrotizing fasciitis in Figure 2. Abscess drainage resulted in approximately 500 ml

of purulent foul-smelling fluid, some of which was sent for gram stain and culture. A wash out of the right lower extremity wounds would be performed several days later with subsequent placement of negative pressure wound dressing. Gram smear in Figure 3 showed Gram-positive filamentous bacteria which were weakly acid fast (*Nocardia* sp).



**Figure 2 and 3:** Showing necrotizing fasciitis of right calf and gram stain showing branching gram-positive bacilli respectively.

She was initiated on treatment with intravenous amoxicillin and clavulanic acid. With regular dressing and antibiotic treatment her condition improved. On discharge, antibiotics were switched to oral form. There was a plan to continue clindamycin for 6 weeks

and amoxicillin and clavulanic acid for 6 months. On follow up, 4 weeks later she was asymptomatic and doing well.

## Discussion

The increased use of antibiotics to treat pharyngitis has led to a decreased occurrence of Lemierre's Syndrome, earning it the moniker "the forgotten disease." One source states incidence in the early 1990s was as low as 0.8-1.5 per million persons per year [8]. However, there have been an increased number of cases reported over the last 20 years [9]. There have been several proposed reasons for this increase in incidence. One possible cause is a decreased use of antibiotics to treat uncomplicated pharyngitis. Another postulate is that improved anaerobic culturing techniques have led to increased detection of *Fusobacterium* infection. Yet another theory is that the increased number of cases is due to emerging antibiotic resistance amongst *Fusobacterium* species. A recent study showed the resistance rate to erythromycin was as high as 15% amongst strains of *Fusobacterium necrophorum* [10]. Penicillin resistance has also been reported due to production of beta-lactamase by some strains of *Fusobacterium necrophorum* [11].

The first case of human necrobacillosis was reported in 1900 by Courmont and Cade [12]. This was followed by a report in 1936 by Lemierre, which identified a series of patients with *Fusobacterium* spp. infections; since this report, the eponym "Lemierre's syndrome" has been used to describe *Fusobacterium* spp. infections of the internal jugular vein complicated by metastatic abscesses [1]. In both original and recent case descriptions, most patients had an antecedent pharyngotonsillitis presenting as a sore throat and pharyngeal hyperemia. In a recent review among 87% of cases, the primary source of infection was the palatine tonsils and peritonsillar tissue [6]. Up to one third of patients presents a mixed infection frequently with streptococci and other gram-negative anaerobes.

*F. necrophorum* is a non-spore-forming gram-negative anaerobic rod belonging to the normal flora of the oropharynx and is recognized as the causal agent of approximately 10% to 20% of pharyngitis cases in adolescents [2, 13-15]. The disease is often initially misdiagnosed as a viral pharyngitis, especially mononucleosis [2]. Several clinical clues can be helpful in distinguishing Lemierre's syndrome from mononucleosis. For instance, mononucleosis typically presents with more generalized lymphadenopathy in contrast to the more localized cervical lymphadenopathy of Lemierre's syndrome. Another clue, and one of the most typical findings of a Lemierre's syndrome, is the presence of lung infiltrates. In young patients with pharyngitis, the presence of concurrent lung lesions should raise the clinical suspicion for Lemierre's syndrome. Critical to the diagnosis of Lemierre's syndrome is the prompt collection of blood cultures and the culturing of any fluid drained from abscesses that may be present. However, *Fusobacterium necrophorum* takes at least 48 hours to grow in culture and sometimes as long as seven days, so clinicians may find it necessary to treat empirically while awaiting culture results [2].

Infection typically occurs in distinct stages beginning with phar-

ngitis followed by local invasion into the pharyngeal space leading to thrombophlebitis of the internal jugular vein. Timing of the second stage is variable, but usually occurs within one week. Patients with Lemierre's syndrome may have a preceding bacterial or viral (e.g., infectious mononucleosis) pharyngitis, which may contribute to the translocation of the *Fusobacterium* spp. into the deep spaces of the neck. The third stage of infection is metastatic spread, most commonly to the lungs (80%) followed by the joints (17%); occasionally, the liver, spleen, bones, kidneys, and meninges are involved [6]. Today, the term "Lemierre's syndrome" is used to describe *Fusobacterium* spp. infections originating not only in the pharynx, but in any structure in the head and neck (e.g., otitis, sinusitis, mastoiditis, parotitis, odontogenic infection, or facial skin infection) [7].

Most cases of classic Lemierre's syndrome occur in young, otherwise healthy, adults, ages 16-23 years, with a propensity for development among males [10]. Necrobacillosis may occur in association with a primary infection of the skin, genitourinary or gastrointestinal systems, as *F. necrophorum* is part of the normal flora of these areas as well as in the oropharynx [16]. Bacteremia may occur when host defenses are compromised and the organism penetrates the mucosal surfaces such as cancer patients undergoing chemotherapy who develop mucositis. The diagnosis of Lemierre's syndrome requires full awareness of this rare condition and high index of clinical suspicion. The disease should be suspected in young patients with history of oropharyngeal infection who failed to improve either spontaneously or after antibiotic treatment and developed clinical and laboratory evidences of sepsis, respiratory symptoms, or atypical unilateral neck pain and swelling. The latter symptoms are characteristic of Lemierre's syndrome, being the consequence of unilateral jugular vein thrombosis. Confirmation of the diagnosis requires the detection of the internal jugular thrombophlebitis and septic embolization to lung and other organs by imaging studies (duplex ultrasound, computed tomography, and magnetic resonance) and by blood and wound cultures that demonstrate *F. necrophorum*; anaerobic cultures are required for growth of this organism. Laboratory data may reveal leukocytosis (75%), thrombocytopenia (24%), increased bilirubin (19%), or hematuria (6%); elevated liver function tests and creatinine have also been described [17,18]. Chest radiography may show a cavitating pneumonia, pulmonary infiltrates, an abscess, pleural effusions, pneumothorax, pneumatoceles, or may be normal.

Our patient was a young, immunocompetent children who presented with fever, neck pain, dysphagia, pharyngitis later complicated with pyomyositis and fasciitis of his lower extremity. The origin of his *Fusobacterium* spp. infection remains unclear (as in 8% of cases) [6]. We searched the English literature (MEDLINE, 1950-2006; EMBASE 1980-2006) for cases of pyomyositis due to *Fusobacterium* spp. using the search terms "*Fusobacterium*" or "Lemierre's" and "pyomyositis" or "myositis". Four cases with detailed clinical information have been published in the literature, all of which occurred in association with an adjacent septic joint (most frequently the hip, shoulder, or knee), and all were due to



*F. nucleatum*. Our case is unique in that there was no evidence on arthroscopic examination or synovial fluid cultures of a concurrent septic arthritis and that the organism was the more virulent species of *Fusobacterium*, *F. necrophorum* [19-22].

Pyomyositis, classically an infection of the tropics, is defined as a primary suppurative infection of the skeletal muscle, first described by Scriba in 1885 [23]. Predisposing factors include conditions characterized by immunodeficiency (T cell deficiency, Chronic granulomatous disease, hyper-IgE syndrome, HIV, Malignancy, Diabetes, use of steroids and immune suppressants), trauma, concurrent infection (with Toxocariasis, Varicella or Arbovirus) and malnutrition [24,25]. The common causative organisms are Gram positive bacteria, such as *Staphylococcus aureus* (90% in tropics and 75% in temperate regions) and Group A *Streptococcus* (1-5%) [25]. Seventy-five percent of cases occur in immunocompromised individuals, the thigh being a common site. Nocardial pyomyositis is extremely rare but responds well to treatment if initiated early [26,27]. Three clinical stages of disease process have been described: invasive (bacterial seeding), suppurative (abscess formation) and septicemic stage (dissemination in blood with multiple organ dysfunction). The presentation of localized muscle pain, edema, low grade fever in first stage leads to misdiagnosis of muscle strain or contusion. Pain and swelling in the second stage lead to differentials of deep vein thrombosis, septic arthritis or osteomyelitis. By definition, pyomyositis never occurs secondary to contiguous infection of soft tissue or joints nor due to penetrating trauma. However, in third stage as a part of septicemia when it involves skin, leading to cutaneous gangrene, it can present as necrotizing fasciitis like picture.

Aspiration of pus from the muscle or muscle biopsy (in case of absent macro abscess as in the early invasive stage) with culture and gram staining is the gold standard for diagnosis. But in tropical regions, pus cultures are sterile in 15-30% cases whereas 90-95% of patients in tropics and 70-80% in temperate regions have sterile blood cultures [28,29]. Radiologically, USG is useful during the purulent stage of pyomyositis when it may detect diffuse muscle hyper echogenicity with or without localized hypo echogenicity (suggestive of collection) and diffuse hyperemia [30]. Contrast enhanced CT reveals segments of low attenuation with loss of muscle planes and a surrounding rim of contrast enhancement. Magnetic resonance imaging is considered the gold standard for the diagnosis of pyomyositis at any stage. It can differentiate pyomyositis from necrotizing soft tissue infections [31].

The basic modalities of treatment include supportive therapy, antibiotics, and surgical drainage/debridement. If identified in first stage, antibiotic therapy covering Gram positive organisms is sufficient, while an immunocompromised patient would require additional gram-negative coverage. But in later stages, broad spectrum antibiotics (covering Gram positive including MRSA and gram-negative organisms) are used empirically, which can be de-escalated if indicated after culture reports. Clindamycin is indicated in severe cases as in necrotizing infections or toxic shock

syndrome and empirically in later stages in immunocompromised. The duration should be tailored to clinical and radiographic features. Moreover, there is spontaneous resolution of thrombus even without anticoagulation. Whether anticoagulation is beneficial for antibiotic penetration into the septic emboli and leads to faster resolution of thrombus is debatable [32].

Effective antibiotics against *Fusobacterium spp.* include penicillin's, cephalosporins, metronidazole, clindamycin, chloramphenicol, and tetracyclines. Since  $\beta$ -lactamase production may occur, therapy with penicillin alone should be avoided [23]. Furthermore, these infections may be polymicrobial in nature. Antibiotic options include an intravenous broad-spectrum  $\beta$ -lactamase-resistant agent (e.g., aminopenicillins), penicillin with metronidazole, or clindamycin. Despite appropriate antibiotics, fevers may persist for days given the endovascular nature of the infection and concurrent necrotic abscesses, as demonstrated by our case [7]. Time from antibiotic administration to resolution of fever can last upwards of 8-12 days [2]. The slow response time is thought to result from sequestration of the infection with resulting poor penetration of antibiotics.

The duration of antibiotic treatment is poorly defined. Most reports recommend a three- to six-week course. Initial treatment should utilize intravenous antibiotics until the patient is afebrile and clinically improved [6]. Another point of controversy is whether to administer anticoagulants in treatment of Lemierre's syndrome due to the propensity for thrombus formation. Some reports have supported use of anticoagulants in addition to systemic antibiotics, but no clear guidelines exist [33]. A retrospective study has shown that use of anticoagulants did not affect thrombus outcome in cases of Lemierre's syndrome, with thrombus resolution occurring in all 24 cases regardless of anticoagulant use [34]. However, anticoagulants may be indicated for high-risk patients, such as those with extensive internal jugular thrombosis, or those who have not responded to antimicrobial therapy or unless propagation of the clot towards the cavernous sinus is noted [7,17,33]. Occasionally, thrombectomy and IJV ligation is necessary in cases of ongoing septic embolization, despite antimicrobial therapy. Surgical evacuation of necrotic abscesses is recommended to speed resolution of the infection.

The mortality rate in the pre-antibiotic era was almost universal, with most patients dying within 7-15 days of presentation [1]. The mortality rate remains substantial (6-18%), but most cases have a favorable outcome when appropriate therapy is administered [6,7,35]. Prevention of invasive infection may be accomplished by treating the initial pharyngitis before involvement of the internal jugular vein. Epidemiologically, the number of invasive *Fusobacterium spp.* infections decreased after the introduction of antibiotics in the 1940s and 1950s, but have recently risen, as fewer physicians now treat non-streptococcal pharyngitis cases with empiric antibiotics in an attempt to diminish the spread antimicrobial resistance [10,18]. The rate of occurrence remains overall low, with estimates of 0.9-2.3 cases per million per year in Europe [8,36].

This report serves to remind clinicians to consider a *Fusobacterium spp.* infection among patients with classic presentations of Lemierre's syndrome as well as among infectious processes with septic embolic phenomena. Although necrobacillosis has been referred to as the "forgotten disease," it remains an important diagnosis for all clinicians to recognize and treat.

## Conclusion

Lemierre disease is suppurative thrombophlebitis of internal jugular vein secondary to oropharyngeal infection and can be complicated by septic emboli. Early diagnosis and prompt treatment with long term antibiotics with beta-lactamase anaerobic activity results in complete resolution of the condition.

The present case suggests that

1. The recommended oral antibiotic treatment for acute pharyngeal infections does not always prevent the progression of the disease into the life-threatening Lemierre's syndrome;
2. An anaerobic infection and the Lemierre's syndrome should be suspected in patients affected by pharyngotonsillitis with a severe and unusual course;
3. In these patients an empirical antibiotic therapy, active also against anaerobic microorganism, has to be started early; moreover, an imaging study of the neck, searching for jugular thrombophlebitis and parapharyngeal abscesses, should be obtained as soon as possible.

## References

1. Lemierre, A. (1936). On certain septicaemias due to anaerobic organisms. *The Lancet*, 227(5874), 701-703.
2. Riordan, T., & Wilson, M. (2004). Lemierre's syndrome: more than a historical curiosa. *Postgraduate Medical Journal*, 80(944), 328-334.
3. Leugers, C. M., & Clover, R. (1995). Lemierre syndrome: postanginal sepsis. *The Journal of the American Board of Family Practice*, 8(5), 384-391.
4. Kasper, D. L., Fauci, A. S., Hauser, S. L., Longo, D. L. L., Jameson, J. L., & et al. (2015). *Harrison's principles of internal medicine*. McGraw Hill Education. 19th edition.
5. Moreno, S., Altozano, J. G., Pinilla, B., Lopez, J. C., de Quirós, B., & et al. (1989). Lemierre's disease: postanginal bacteremia and pulmonary involvement caused by *Fusobacterium necrophorum*. *Reviews of infectious diseases*, 11(2), 319-324.
6. Chirinos, J. A., Lichtstein, D. M., Garcia, J., & Tamariz, L. J. (2002). The evolution of Lemierre syndrome: report of 2 cases and review of the literature. *Medicine*, 81(6), 458-465.
7. Kristensen, L. H., & Prag, J. (2000). Human necrobacillosis, with emphasis on Lemierre's syndrome. *Clinical infectious diseases*, 31(2), 524-532.
8. Hagelskjaer, L. H., Prag, J., Malczynski, J., & Kristensen, J. H. (1998). Incidence and clinical epidemiology of necrobacillosis, including Lemierre's syndrome, in Denmark 1990-1995. *European journal of clinical microbiology and infectious diseases*, 17(8), 561-565.
9. Karkos, P. D., Asrani, S., Karkos, C. D., Leong, S. C., Theochari, E. G., & et al. (2009). Lemierre's syndrome: a systematic review. *The Laryngoscope*, 119(8), 1552-1559.
10. Brazier, J. S., Hall, V., Yusuf, E., & Duerden, B. I. (2002). *Fusobacterium necrophorum* infections in England and Wales 1990-2000. *Journal of Medical Microbiology*, 51(3), 269-272.
11. Brook, I. (1993). Infections caused by beta-lactamase-producing *Fusobacterium spp.* in children. *The Pediatric infectious disease journal*, 12(6), 532-533.
12. Curmont, P. (1900). Sur une septico-pyohemie de l'homme simulant la peste et causee par un strepto-bacille anaerobie. *Arch Med Exp Anat Pathol*, 12, 393-418.
13. Centor, R. M., Atkinson, T. P., Ratliff, A. E., Xiao, L., Crabb, D. M., & et al. (2015). The clinical presentation of *Fusobacterium*-positive and streptococcal-positive pharyngitis in a university health clinic: a cross-sectional study. *Annals of internal medicine*, 162(4), 241-247.
14. Hedin, K., Bieber, L., Lindh, M., & Sundqvist, M. (2015). The aetiology of pharyngotonsillitis in adolescents and adults-*Fusobacterium necrophorum* is commonly found. *Clinical Microbiology and Infection*, 21(3), 263-e1.
15. Jensen, A., Hansen, T. M., Bank, S., Kristensen, L. H., & Prag, J. (2015). *Fusobacterium necrophorum* tonsillitis: an important cause of tonsillitis in adolescents and young adults. *Clinical Microbiology and Infection*, 21(3), 266-e1.
16. Alston, J. M. (1955). Necrobacillosis in Great Britain. *British medical journal*, 2(4955), 1524.
17. Golpe, R., Marín, B., & Alonso, M. (1999). Lemierre's syndrome (necrobacillosis). *Postgraduate medical journal*, 75(881), 141-144.
18. Bliss, S. J., Flanders, S. A., & Saint, S. (2004). A pain in the neck. *New England Journal of Medicine*, 350(10), 1037-1042.
19. Chryssagi, A. M., Brusselmans, C. B., & Rombouts, J. J. (2001). Septic arthritis of the hip due to *Fusobacterium nucleatum*. *Clinical rheumatology*, 20(3), 229-231.
20. Gonzalez-Gay, M. A., Sanchez-Andrade, A., Cereijo, M. J., Pulpeiro, J. R., & Armesto, V. (1993). Pyomyositis and septic arthritis from *Fusobacterium nucleatum* in a no immunocompromised adult. *The Journal of rheumatology*, 20(3), 518-520.
21. Wolf, R. F., Konings, J. G., Prins, T. R., & Weits, J. (1991). *Fusobacterium pyomyositis* of the shoulder after tonsillitis: Report of a case of Lemierre's syndrome. *Acta orthopaedica Scandinavica*, 62(6), 595-596.
22. Beavers, B. R. (1992). *Fusobacterium nucleatum pyomyositis*. *Orthopedics*, 15(2), 208-211.
23. Scriba, J. (1885). Beitrag zur aetiologie der myositis acuta. *Dtsch Z Chir*, 22, 497-502.
24. Christin, L., & Sarosi, G. A. (1992). Pyomyositis in North America: case reports and review. *Clinical infectious diseases*, 15(4), 668-677.
25. Shepherd, J. J. (1983). Tropical myositis: is it an entity and what is its cause? *The Lancet*, 322(8361), 1240-1242.
26. Agarwal, V., Chauhan, S., & Gupta, R. K. (2011). Pyomyositis. *Neuroimaging Clinics*, 21(4), 975-983.

27. Sagar, V., Pinto, B., Lal, A., Kumar, M., Rathi, M., & et al. (2017). Nocardia pyomyositis in a patient with granulomatosis with polyangiitis. *International journal of rheumatic diseases*, 20(11), 1848-1849.
28. Gambhir, I. S., Singh, D. S., Gupta, S. S., Gupta, P. R., & Kumar, M. (1992). Tropical pyomyositis in India: a clinico-histopathological study. *The Journal of tropical medicine and hygiene*, 95(1), 42-46.
29. Brown, J. D., & Wheeler, B. (1984). Pyomyositis: report of 18 cases in Hawaii. *Archives of internal medicine*, 144(9), 1749-1751.
30. Schumacher TM, Genant KH, Dorobion M, et al. (1978). Computed Tomography. *J Bone Joint Surg*, 60, 600-7.
31. Jacqueline, C., Navas, D., Batard, E., Miegerville, A. F., Le Mabecque, V., & et al. (2005). In vitro and in vivo synergistic activities of linezolid combined with sub inhibitory concentrations of imipenem against methicillin-resistant *Staphylococcus aureus*. *Antimicrobial agents and chemotherapy*, 49(1), 45-51.
32. Goldstein, E. J., Summanen, P. H., Citron, D. M., Rosove, M. H., & Finegold, S. M. (1995). Fatal sepsis due to a  $\beta$ -lactamase-producing strain of *Fusobacterium nucleatum* subspecies polymorphum. *Clinical infectious diseases*, 20(4), 797-800.
33. Phua, C. K., Chadachan, V. M., & Acharya, R. (2013). Lemierre syndrome—should we anticoagulate? A case report and review of the literature. *International Journal of Angiology*, 22(02), 137-142.
34. Cupit, M. C., Nageswara Rao, A., Warad, D. M., Khan, S., & Rodriguez, V. (2015). Lemierre's syndrome: role of anticoagulation and thrombosis outcomes, a retrospective study. *Blood*, 126(23), 2296.
35. Liu, A. C., & Argent, J. D. (2002). Necrobacillosis—a resurgence? *Clinical radiology*, 57(5), 332-338.
36. Jones, J. W., Riordan, T., & Morgan, M. S. (2001). Investigation of postanginal sepsis and Lemierre's syndrome in the South West Peninsula. *Communicable disease and public health*, 4(4), 278-281.

**Copyright:** ©2022 Richmond Ronald Gomes. This is an open-access article distributed under the terms of the Creative Commons Attribution License, which permits unrestricted use, distribution, and reproduction in any medium, provided the original author and source are credited.