

Intraspinal ependymomas and Their Association with Metastasis/ Disseminations in Patients Over a Period of 22 Years

Elixena López Savón^{1*}, Francisco Goyenechea Gutiérrez² and Zenaida Hernández Díaz³

¹Neurosurgeon at Juan Manuel Marquez Hospital, Havana, Specialist in the first degree in Neurosurgery. First degree specialist in MGI. Master in Medical Emergencies.

²Neurosurgeon at neurosurgery institute Havana, Doctor of Science Associate Professor. Master in ECV.

³Master in ECV. Assistant Professor, radiologist at neurosurgery institute Havana

*Corresponding author

Elixena Lopez Savon, neurosurgeon, address: third street No. 11110 Residencial Almedares, Boyeros La Habana, Cuba, Email: elixena@infomed.sld.cu, Tel: 53104552.

Submitted: 20 July 2018; Accepted: 02 Aug 2018; Published: 25 Aug 2018

Summary

Introduction: Ependymomas are neuroepithelial tumors of variable morphological appearance whose treatment of choice is surgical. They represent 13% of intraspinal tumors and constitute 40% of spinal tumors in adults. In Cuba there are few studies about this pathology, hence the main objective is to evaluate the behavior of intraspinal ependymomas in the Neurology and Neurosurgery Institute.

Patients and Methods: A retrospective descriptive study of 47 patients operated on with a histological diagnosis of intraspinal ependymomas in a period of 22 years was carried out.

Results: In the patients studied, 51% started with a radicular syndrome. In ependymomas, the most frequent histology was myxopapillary (34%) and the terminal filum was the location that prevailed (48.9%). A total resection was achieved in 51.1%, postoperative complications were not frequent, being the cerebrospinal fluid fistula (19.1%) the most frequent. Half of the subjects evolved favorably. 40.4% of the intraspinal ependymomas studied were from intracranial tumors, and of these 73.7% recurred. Primary spinal tumors did not disseminate in 92.9% of cases.

Conclusions: Intraspinal ependymomas may be primary of the spine or disseminations / metastases of other locations of the neuraxis. The disseminations do not depend on the degree or histological type. Spinal ependymomas have a high rate of tumor recurrence. The adequate postoperative functional recovery depends on an early diagnosis of intracranial ependymomas and the degree of surgical resection.

Keywords: Ependymomas, Disseminations, Rachis, Disseminations and metastasis.

Introduction

Within the neuroepithelial tumors are ependymomas, these are tumors of variable morphological appearance, they originate from the ependymal cell layer of the ventricular system and the central canal of the spinal cord⁴. In the spine, they tend to be localized in the regional transition zones, that is, at the cervico-dorsal level and most frequently in the dorso-lumbar area, in the medullary cone and the cauda equina [1]. There is no clear predominance in one sex or the other. The most frequent age of presentation is between 30-50 years.

Some international series report an incidence of these tumors from 2.2 to 2.7 per 100,000 inhabitants / year. In 2014, 200 cases of intraspinal ependymomas were reported in the USA [2]. In Cuba studies from that same year show that the figures were from 1.9 to 2.1 per 100,000 inhabitants. If these values are compared with those obtained in 2009 (1.4 to 1.7 per 100,000 inhabitants) it will

be noted that there has been a progressive increase [3].

Despite the gradual rise of ependymomas, their presentation in the world population is low, constituting less than 5% of all primary tumors of the CNS. However, they are the fourth most common brain tumor in children.

The location of ependymomas in adults tends to be different from that of children. In adults, 60% of these tumors are found in the spinal cord. In children, 90% of ependymomas are located intracranially, mostly in the posterior fossa. Of all intraspinal tumors, ependymomas represent 13%, although the frequency varies between children (10%) and adults (40%) [4,5].

Approximately 10 to 15% of ependymomas are disseminated or metastasized through cerebrospinal fluid (CSF) in the spinal canal and even in other intracranial topographies [6]. Infratentorial tumors are more likely to metastasize to the spine than supratentorial tumors. Ependymomas almost never spread outside the CNS. Although there

are reports of isolated cases with metastases in other organs outside the neuraxis, such as: liver, lung, lymph nodes and soft tissues.

The study of CSF by lumbar puncture is necessary to determine if the tumor has spread to the spinal cord and/or cerebrospinal fluid, as well as the study of scanning the entire body looking for extraneural spreads/disseminations. The definitive diagnosis is made by histopathology of the piece obtained in the surgery.

Being our tertiary health care center, we have been able to realize the need to study this entity, to determine the incidence of cases operated in the country in which intracranial or extracranial dissemination could not be avoided.

Method

A descriptive, retrospective study was conducted in patients operated on intratrachealependymomas in the neurosurgery service of the INN. We reviewed the database of the Department of Pathology of the Neurology and Neurosurgery Institute, in the periods 1990-2007 and 2009-2014 (22 years) with the aim of selecting patients with this histopathological diagnosis.

During this period, 56 adult patients and 3 children had histopathological confirmation. Of the universe of patients diagnosed with intratrachealependymoma, 47 were included in the study since they met the inclusion criteria.

The inclusion criteria were

- Patients operated in the INN or by physicians of the institution in other centers, with diagnosis of intraspinealependymoma confirmed histopathologically.
- Patients with a medical history present in the INN archives.
- Age between 19 and 80 years at the time of spinal surgery.
- Clinical diagnosis with MRI studies before and after surgery.

Procedure of the Data Record

We proceeded to the preparation of the Database in Statistica where all the results available for the investigation were collected. The data were analyzed through statistical tests considering the possible biases in the investigation.

Statistic analysis

The data of the studied population were collected in Microsoft Excel, verifying that for each registered variable there were no extreme, inconsistent or lost values. The statistical analysis was carried out with the statistical package Statistica v.6.0. To describe the behavior of the study variables, the normality of these was analyzed. The mean and standard deviation were calculated for the continuous variables and the percentage for the categorical variables. To define associations between categorical variables, contingency tables and the X² test (Chi-square) were used. To compare means of continuous variables, we used

Description of the General Surgical Technique

In spite of its intramedullary location, the advances of bipolar coagulation, the ultrasonic aspirator and the surgical microscope, now aid in a complete exeresis of these tumors without damaging the adjacent medullar tissue, so that surgery represents the most effective treatment for the patients. Intramedullary ependymomas. However, the possibilities of a total resection are usually assessed during surgery, when assessing whether or not there is a clear boundary

between the tumor and adjacent healthy tissue.

The sitting position is the most comfortable to remove the ependymomas of the cervical spine and cervicodorsales, and the dorsal and dorsolumbarependymomas can be removed comfortably in lateral decubitus. However, many surgeons prefer the prone position for all locations. After performing a laminectomy that must exceed the topographic limits of the tumor, a longitudinal incision is made of the dura, in midline, and the edges of the dural incision are sutured laterally to the muscle or are tightened with suture threads that attach to the muscles. Surgical drapes with Halsted forceps (mosquitoes) dural traction points. After obtaining an adequate exposure of the dorsal surface of the marrow, and with the help of the surgical microscope, a mid-line myelotomy is performed until the tumor is reached. In the case of ependymomas, the tumor is easily identifiable due to its reddish-gray color, totally different from that of the spinal cord.

Once the lesion is visualized and its extension defined, the pia mater points are made to expand the surgical field and adequately expose the lesion. In these maneuvers, gentle lateral dissection maneuvers are carried out, avoiding the use of the aspirator as much as possible.

The pial edges can then also be separated laterally, by suture threads that are tightened with Halsted forceps, in order to maintain adequate exposure of the entire tumor surface.

From this moment the ultrasonic aspirator can be used to excavate the central portion of the tumor, when we have one, but microdissection is performed with magnification. Intratumoral hemorrhage is usually minimal and, if necessary, easily controlled with bipolar coagulation. Once the tumor has been excavated, the dissection of the tumor is continued with respect to the medullary tissue, through dissectors, until the tumor is completely separated, which is gradually extracted by gentle traction, dissection and coagulation of its adhesions to the medullary tissue, both vascular and connective. In this technique it is preferable not to attempt the complete extirpation of the tumor by means of the ultrasonic aspirator, since in the final phases of the tumor removal, the ultrasonic aspirator can injure healthy medullary tissue. In any case, it must be taken into account that, in general, intramedullary ependymomas usually have a small fibrous tract at the caudal end, which connects them to the medullary tissue and that must be coagulated and sectioned in order to complete the tumor block removal, in the last stages of the exeresis.

After checking the perfect hemostasis of the surgical bed, it is possible to proceed to join the edges of the myelotomy with fine points of arachnoid suture, although this maneuver does not seem to influence the surgical result, it is not usually done. The dura should be closed with stitches, and the dural suture can be reinforced with biological sealants, such as fibrin gel, to prevent the possibility of CSF fistulas. After that, the laminectomy is closed, according to the usual technique.

In the case of ependymomas of the cone and horsetail, which are usually presented to us surgically as an intramedullary mass that becomes extrinsic, the extrinsic portion of the tumor and then the intramedullary portion must be removed first. Sometimes, these tumors have a very large size, which makes surgery extremely difficult, especially because of the risk of damaging the roots of the horse's tail and in these cases, block extirpation is practically

impossible. When the ependymoma is born in the filum, and does not have a large size, a portion of the filum is always identified, without tumor involvement, between the tumor and the medullary cone, being relatively easy the surgical extirpation in block.

Results

Our series was constituted by 47 patients with a clinical, neuroimaging and histopathological diagnosis of intraspinal ependymoma, who underwent surgery; of these 28 were primary ependymomas of the

rachis and 19 secondary ependymomas. 68.1% of the patients had white skin color and 31.9% had a mestizo color.

Of these, 27 (57.4%) were male and 20 (42.6%) were female. The mean age for the diagnosis of intraspinal ependymoma and the time of evolution of the disease was 42.2 years and 14.1 months, respectively. In both cases there were no significant differences between men and women ($p > 0.05$) (table 1).

Table 1: Distribution of patients by age at diagnosis of intraspinal ependymoma and time of disease progression according to sex

Sex	Age at diagnosis of intraspinal ependymoma			Time of evolution (months)		
	n	mean ± DE	X ² /p	n	average (min-max)	X ² /p
Female	20	41.9 ± 16.8	33.02/0.27	19	13.8(1-28)	20.19/0.44
Male	27	42.3 ± 15.2		28	14.4(3-369)	

FROM. Standard derivation

The clinical characteristics of the patients studied are described in Table 2. Of the 3 forms of clinical presentation, the radicular syndrome was the most frequent (51.1%).

Table 2. Description of the clinical presentation of the patients studied

Clinical Presentation	n	%
Síndrome Mielopático	13	27.6%
Myelopic syndrome	24	51.1
Axial pain	10	21.3

In the histopathological study, a predominance of grade II intraspinal ependymomas was found in 26 patients (55.4%), and the most common histological type was myxopapillary (34%) (Table 3).

Table 3: Distribution of patients according to histological type and degree of ependymomas according to WHO

Histopathological characteristics			
Histological Type	(Degree)	n	%
Subependymoma	(I)	2	4.2
Mixopapilar	(I)	16	34.0
Papillary	(II)	13	27.7
Cell	(II)	6	12.8
Tanacitic	(II)	7	14.9
Anaplastic	(III)	3	6.4
Total		47	100

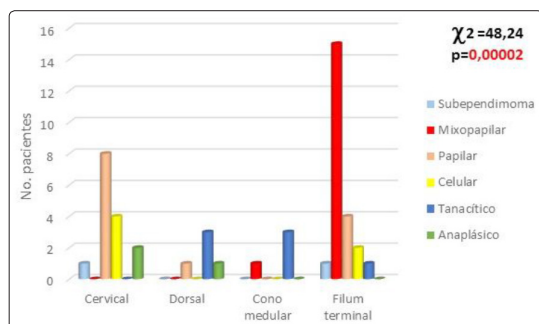


Figure 1: Association of the histological type of intraspinal ependymomas with the location in the spinal segment.

Table 4: shows the characteristics of the type of surgery performed on patients with intratrachealependymomas. It is observed that 51.1% of the operated cases underwent total resection of the tumor.

Table 4: Characteristics of the type of surgery performed on patients with intratrachealependymomas

Microsurgical Resection	n	%
Total Resection	24	51.1
Subtotal Resection	23	48.9

When the presence of intracranial ependymomas was related to intraspinal dissemination/metastasis, it was found that 89.5% of the cases that had a history of having undergone intracranial

ependymomas disseminated/metastasized to the spine. However, 92.9% of the primary ependymomas of the spine did not disseminate within the same spine or in other locations of the neuraxis (Table 5).

Table 5: Association of intracranial ependymomas and other tumors outside the central nervous system with intraspinal dissemination / metastasis

Presence of Ependimomas Dissemination/Metastasis Intracranial/ thertumors* Intraspinal,	n	(%)	Total
SI NO	2 (7.1)	26 (92.9)	28
SI	17 (89.5)	2 (10.5) *	19
Total	19	28	47

$X^2=28.106$, $p=0.00000$, * Breast Tumor

Figure 2 shows the incidence of intraspinal tumor recurrence in the operated patients. In the cases of primary ependymomas of the spine, tumor recurrence was only 25%, however when the ependymomas were secondary to the spine (dissemination / metastasis), the tumor recurrence was evidently greater (73.7%), reflecting a significant association between these variables ($X^2 = 10.9$, $p = 0.0097$).

There was no association between surgical resection and local intralocal tumor recurrence ($X^2 = 3.01$, $p = 0.22$).

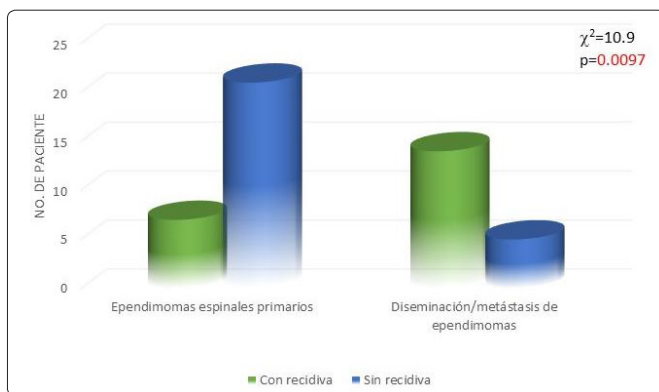


Figure 2: Relationship between intraspinal tumor recurrence in patients with primary spinal ependymoma and secondary ependymomas due to spine dissemination / metastasis.

Although all the patients included in the study were operated on, 44.6% were onco-specific treatments, of them 2 (4.3%) received chemotherapy, 14 (29.8%) radiotherapy and 5 (10.6%) combined radio-chemo therapy. These therapies were indicated for patients with primary ependymomas and those who had recurrences and disseminations.

Table 6. details the characteristics of the 19 patients (40.4%) with metastatic ependymomas of the spine, and their primary ependymomas in other locations of the neuroaxis.

Table 6: Characteristics of patients with primary ependymomas who made intraspinal disseminations

Location of the first ependymoma Intracranial	17	(89.5)
Intraspinal	2	(10.5)
Specific location of intracranial IV Ventricles	14	(82.3)
Ependymoma Lateral Ventricles	1	(5.9)
n (%) III Ventricle	1	(5.9)
Parietooccipital	1	(5.9)
Age at the diagnosis of the first Ependimoma, mean± DE(min- máx)	39.7± 12.7(4-64)	
Grade according to WHO and histological variant Subependimoma		
Of the primary tumor and dissemination/ Grade I Mixopapilar	10	(52.6)
Metastasis,	n	(%)
Papillary	2	(10.5)
Grade II Cell	1	(5.2)
Tanacítico	1	(5.2)
Grade III Anapasic	5	(26.3)
Period of dissemination (months) Mean ± SD(min-máx)	39.9 ± 48.3(2-180)	
Localización de las diseminaciones/ Cervical	10	(52.6)
Metastasis,	n	(%)
Cervical-Dorsal	2	(10.5)
Dorsal	1	(5.2)
Lumbar-back	1	(5.2)
Lumbosacral	5	(26.3)
Location of the spinal canal, Intradural	n	(%)
3(15.8)		
Intramedullary	16	16 (84.2)

Discussion

Intraspinal ependymomas have had a progressive increase in our country during the last years, with the subsequent increase in disability and sequelae in working-age adults [7, 8].

In the present study, the male sex prevailed, with an average age at diagnosis of 42.2 years 18, a result that coincides with the literature reviewed [9]. In our study, the male sex had a frequent incidence with a 1.3: 1 ratio worldwide [10].

In our series, the clinical presentation that predominated was the radicular syndrome with moderate functional impairment, where there is neurological deficit with limited functions, these patients had validation, but required external help grade III according to McCormick) [11-13]. This indicates that the diagnosis was not made early, since they already had some neurological deficit, coinciding with a considerable growth of the tumor. The early clinical findings in the natural course of the disease are often very subtle, due to the insidious onset of symptoms, which are sometimes attributed to other conditions, obviating the diagnosis of intra-tracheal tumor. Together with the limited availability of MRI in our country, they

delayed the diagnosis in these patients.

There are numerous references in the literature regarding various atypical forms of presentation in ependymomas, [11, 14]. One of our patients was diagnosed with a pseudovascular form, which clinically presented an acute myelopathic syndrome due to tumor bleeding, as evidenced by MRI.

From the histopathological point of view, we found that the myxopapillary group at the level of the terminal phylum was the most frequent. On the other hand, the less frequent histological subtype was the anaplastic with dorsal localization [14-18]. The most important and effective treatment of intraspinal ependymomas is surgery. Nowadays, magnification, the ultrasonic aspirator and the laser are tools that allow total resection and less spinal damage. In our patients a total resection 24 was performed in 51.1%, the presence of syringomyelia, encapsulated lesions and cysts in the poles favored the total microsurgical resection when they were present. However, in 48.9% the resection was partial, which obeys different reasons, one of them is the lack of an ultrasonic aspirator and the laser. The other factors that affected are the same as those reported by other authors, such as: ependymomas that extended to three or more vertebral bodies, when a plane of cleavage (anaplastic infiltrating the medullary tissue) could not be adequately defined, those located in the medullary cone and filum that surrounded the roots of the equine cauda, among others [19].

Of the intraspinal ependymomas studied, a significant number of cases (8) were found to be disseminations / metastases of intracranial tumors to the rachis. The intracranial ependymomas were located mainly at the level of the IV ventricle [17]. Very few were disseminated within the same channel (2) and even one of them extended to sacral soft parts. Grade II was the most frequent histological type, coinciding with the literature [20, 21]. Secondary tumors of the spine (disseminations / metastases) after being resected recurred more frequently than primary ependymomas of the spine. This may be due to the fact that the patients in whom the disseminations occurred and after the tumor recurrence, had a greater genetic predisposition which favors the appearance of these tumors.

In our study, although adults were studied, it was found that two of the cases studied were children of 4 and 9 years old when they were diagnosed with primary ependymoma (grade II) of the IV ventricle, in which they underwent total tumor resection without local recurrence. Both patients had disseminations / metastases 16 to the spine at 15 and 10 years respectively [22]. What alerts us in the adequate follow-up of patients operated on intrarachidian and intracranial ependymomas, due to the possibility they have of recurrence and / or dissemination, early or late.

The palliative treatment received by the patients under investigation was chemotherapy, radiotherapy or chemo-radio, which was applied to patients with partial tumor resection, tumor recurrence and disseminations. These onco-specific therapies were applied precisely to avoid relapses and / or disseminations of ependymomas, but in many of them the disease was not controlled.

Our study shows that late clinical diagnosis can worsen the prognosis, since tumor growth increases neurological damage, therefore, microsurgical resection can be partial and post-surgical clinical evolution unfavorable. On the other hand, it is necessary to

consider that tumor recurrences are more frequent in the cases of secondary or metastatic ependymomas than in the primary ones of the rachis and these can be associated with other neoplasms outside the CNS. It is important in the study of intraspinal ependymomas to evaluate the neuroaxis to rule out the presence of disseminations / metastases in other levels [14].

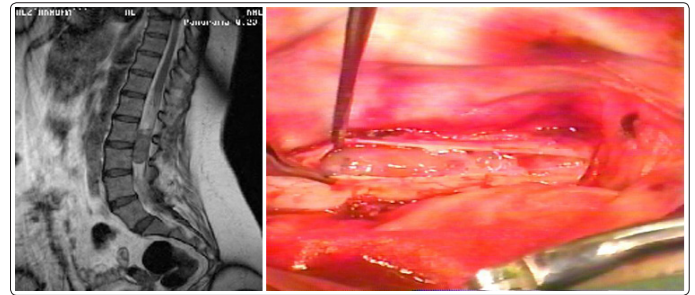


Figure 3: Photos and MRI of the lumbosacral spine, in which it visualizes myxopapillary ependymoma in terminal filum, of regular edges, iso-intense in Balance.

Conclusions

Intraspinal ependymomas may be primary of the spine or disseminations / metastases of other locations of the neuraxis, the most frequent of which is the myxopapillary type located in the terminal filum. The adequate postoperative functional recovery depends on an early diagnosis of intracranial ependymomas and the degree of surgical resection. The majority of primary intracranial ependymomas are from the IV ventricle and their disseminations were located in the cervical region. Knowledge about the origin of the tumor and the proper evolution before and after surgery could prevent the appearance of disseminations, which do not depend on the degree or histological type [23, 24].

Acknowledgements

Thanks to all the people who made possible the realization of this articles, including my relatives and my advisors who worked to achieve a better quality in the result of this important study.

References

1. Tarapore PE1, Modera P, Naujokas A, Oh MC, Amin B, et al. (2013) Pathology of spinal ependymomas: an institutional experience over 25 years in 134 patients. *Neurosurgery* 73: 247-255.
2. Recarte Rico M, Román de Aragón M, Sánchez-Molero Pérez SM, Sancho Saúco J (2009) Descriptive analysis and the survival of ependymoma in the community of Madrid. Complutense University of Madrid. Available at: http://pendientedemigracion.ucm.es/info/dosis/Preventiva/jor_xv/m45.pdf
3. Statistical Yearbook of Health 2012. Ministry of Public Health. National Directorate of Health Records
4. Fuentes Rodríguez N, Rodríguez Loureiro JL, Quintanal Cordero NE, From Above Romanidy MU, Rodríguez de la Paz NJ, from La Paz Rivero M (2013) Presentation and evolution of 26 patients with spinal ependymoma who received microsurgical treatment at the Instituto de Neurology and Neurosurgery (Cuba). *Cuban Rev Neurol Neurocir* 3: 145-151.
5. Gil-Salú JL, Domínguez-Pascual I (2007) Pérez-Requena. Ependymoma. *Crit Rev Oncol Hematol* 63: 81-89.
6. Sandalcioğlu IE, Gasser T, Asgari S, Lazorisak A, Engelhorn T, et al. (2005) Functional outcome after surgical treatment of

- intramedullary spinal cord tumors: experience with 78 patients. *Spinal Cord* 43: 34-41.
7. Jemal A, Bray F, Center M, Ferlay J, Ward E, Forman D (2011) Global Cancer Statistics. *CA: A Cancer Journal for Clinicians* 61: 69-90.
 8. Gutierrez Goyenechea FF, Riverón Pereira R. Lesiones of the central nervous system. *Editorial Ciencias Médicas*. 2014: volume II.p.155.
 9. M. Gelabert-Gonzalez, A. Arcos-Algaba, R. Serramito-Garcia, D. Castro-Bouzas, JM Santín-Amo, et al. (2010) Ependymomas of the terminal filum. *Analysis of 20 consecutive cases. Neurosurgery (Astur).*; 21: 381-389.
 10. Lee J, Parsa AT, Ames CP, McCormick PC (2006) Clinical management of intramedullary spinal ependymomas in adults. *NeurosurgClin N Am* 17: 21-27.
 11. Klekamp J (2015) Spinal ependymomas. Part 2: Ependymomas of the filumterminale. *Neurosurg Focus* 39: E7.
 12. Fotakopoulos G, Vagkopoulos K, Cats C, Kotlia P, Brotis A (2014) Spinal cord ependymomas and the appearance of other novo tumors: a systematic review. *J Med Case Rep* 8: 438.
 13. Pencovich N, Bot G, Lidar Z, Korn A, Wostrack M, Meyer B, et al. (2014) Spinal ependymoma with regional metastasis at presentation. *ActaNeurochir (Wien)* 156: 1215-22.
 14. Ozdemir O, Calisaneller T, Coven I, Altinors N (2007) Posttraumatic intratumoralhaemorrhage: an unusual presentation of spinal ependymoma. *Eur Spine J* 16: S293-S95.
 15. Valles Casanova M, TerréBoliart R, Guevara Espinosa D, PortellSoldevila E, Vidal Samsó J (2002) Descriptive analysis of spinal cord injury and tail horse of tumoral origin in our center. *Rehabilitation (Madr)* 36: 149-54.
 16. Klekamp J (2015) Spinal ependymomas. Part 1: Ependymomas of the filumterminale. *Neurosurg Focus* 39: E6.
 17. Ochiai H, Yamakawa Y, Kawano H, Shimao Y, Hayashi T (2010) Late spinal cord metastasis of fourth ventricle ependymoma appears nineteen years after the initial treatment. *J Neurooncol* 96: 295-99.
 18. McCormick PC (2014) Microsurgical enbloc resection of myxopapillary cauda equina ependymoma. *Neurosurg Focus* 37.
 19. Pencovich N, Bot G, Lidar Z, Korn A, Wostrack M, Meyer B, et al. (2014) Spinal ependymoma with regional metastasis at presentation. *ActaNeurochir (Wien)* 156: 1215-22.
 20. Mavroudis C, Townsend JJ, Wilson CB (1977) A metastasizing ependymoma of the equine cauda. *J Neurosurg* 47: 771-752.
 21. Ernestus RI, Wilcke O (1990) Spinal metastases of intracranial ependymomas. Four case reports and review of the literature. *Neurosurg Rev* 13: 147-154.
 22. Alshaya W, Mehta V, Wilson BA, Chafe S, Aronyk KE, et al. (2015) Low-grade ependymoma with late metastasis: autopsy case study and literature review. *Childs Nerv Syst* 31: 1565-1572.
 23. Gonzalez de Andrade F. Study of the expressions of genetic alterations of ependymomas. *CPM*. 2014. 162: 1145-12.
 24. Safae M, Oh MC, Mummaneni PV, Weinstein PR, Ames CP, Chou D, et al. (2014) Surgical outcomes in spinal cord ependymomas and the importance of extent of resection in children and young adults. *J NeurosurgPediatr* 13: 393-399.

Copyright: ©2018 Elixena Lopez Savon, et al. This is an open-access article distributed under the terms of the Creative Commons Attribution License, which permits unrestricted use, distribution, and reproduction in any medium, provided the original author and source are credited.