

## Instrumental diagnosis and laparoscopic treatment of the giant sigmoid diverticulum: technical notes. Internal hernia and abdominal abscess after one month

Raffaele Porfidia<sup>\*1</sup>, Maria Giovanna Ciolli<sup>1</sup>, Pietro Picarella<sup>1</sup>, Angela Romano<sup>1</sup>, Simona Grimaldi<sup>2</sup>, Mauro Carfora<sup>3</sup>, Giuseppe Russo<sup>4</sup>, Daniela Berritto<sup>5</sup>, Giuseppina Dell'Aversano Orabona<sup>4</sup>, Antonio Romeo<sup>4</sup>, Raffaele Nappi<sup>4</sup>, Giuseppina Napolitano<sup>4</sup>, Piero Brusa<sup>3</sup> and Sergio Grimaldi<sup>1</sup>

<sup>1</sup>Surgeon in General and Oncologic Surgery Department, Ospedale Convenzionato "Villa dei Fiori", Corso Italia 157, 80011 in Acerra (NA), Italy

<sup>2</sup>MD Resident in General Surgery at "Università degli Studi di Milano Statale", Via Festa del Perdono 7, 20122 Milan, Italy

<sup>3</sup>Endoscopist in Digestive Endoscopy Department, Ospedale Convenzionato "Villa dei Fiori", Corso Italia 157, 80011 in Acerra (NA), Italy

<sup>4</sup>Radiologist in Diagnostic Imaging Department, Ospedale Convenzionato "Villa dei Fiori", Corso Italia 157, 80011 in Acerra (NA), Italy

<sup>5</sup>Radiologist in Diagnostic Imaging Department, Casa di Cura "Villa Fiorita", Strada Statale Appia Km 199, 81043 in Capua (CE), Italy

### \*Corresponding author

Raffaele Porfidia, Department of General and Oncologic Surgery Ospedale Convenzionato "Villa dei Fiori", Corso Italia 157, 80011 Acerra (NA), Italy

Submitted: 06 Aug 2020; Accepted: 11 Aug 2020; Published: 23 Aug 2020

### Abstract

*The giant colon diverticulum is a rare disease. Symptomatology is non-specific but can cause acute abdomen in 30% of cases. Diagnosis is often accidental and is mainly based on CT. The treatment is surgical but there are still few cases treated laparoscopically. We present the case of a patient treated laparoscopically who returns to the ward after a month with intra-abdominal abscess and internal hernia without intestinal occlusion.*

**Keywords:** Colic diverticulosis, Giant colonic diverticulum, Laparoscopic treatment, Internal hernia.

### Introduction

Giant colonic diverticulum (GCD) is a rare manifestation of diverticular disease of the colon it affects the sigmoid colon in 90% of cases [1, 2]. GCD is an entity first described by Bonvin and Bonte in 1946 [3]. GCD is a diverticulum of the colon greater than 4 cm in diameter. Fewer than 200 studies, predominantly case reports or small patient series, have been published [4]. Most are pseudodiverticula and are usually single. The presentation is variable from asymptomatic abdominal mass to acute abdomen [4]. The diagnosis and treatment of the GCD can be challenging due to its rarity and relatively nonspecific symptoms. In our case report we illustrate the clinical picture, the pre-operative instrumental examinations carried out, the key points of laparoscopic surgery and the results with reintervention after one month for internal hernia and abdominal abscess.

### Clinical Case

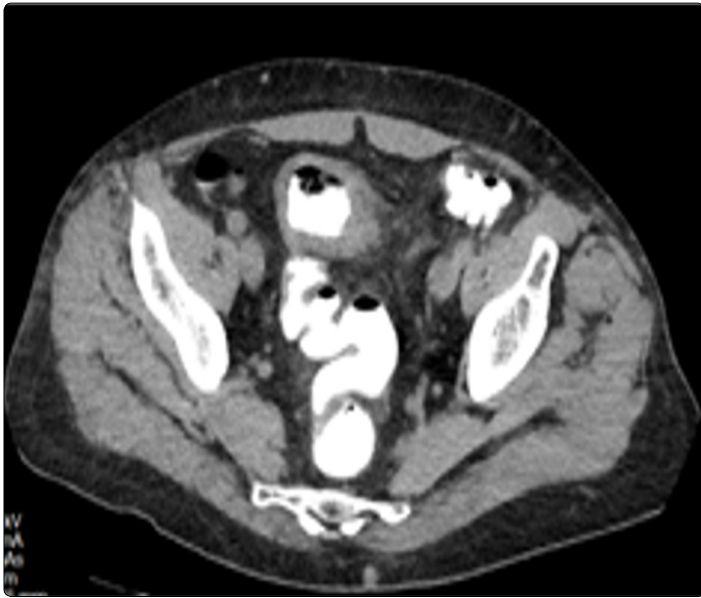
A 53-year-old male patient comes to our observation complaining of constipation, rectal tenesmus, feeling of incomplete rectal emptying, abdominal pain in the lower quadrants of the abdomen and feeling of suprapubic weight. In remote pathological anamnesis: diverticulosis of the left colon diagnosed by pancolonscopy 5 years before and trauma in the sacral region about 20 years before. Deny other comorbidities. BMI 23 kg / m<sup>2</sup>.

### Pre-operative work-up

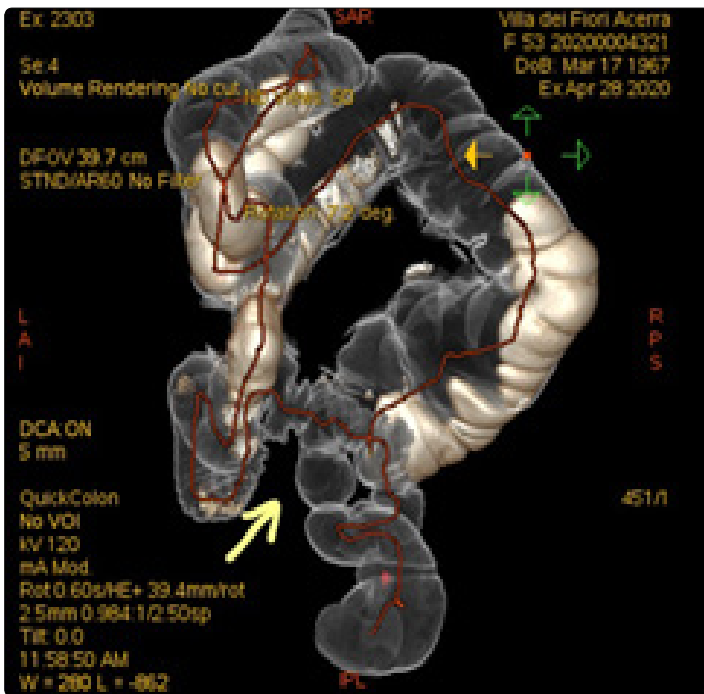
-CT Abdomen: concentric parietal thickening of a sigmoid tract of about 5 cm with a framework of acute diverticulitis (Hinchey I) and distal to the aforementioned segment a voluminous capsulated mass, with fecaloid content, of about 6 x 5.5 cm in communication with the lumen of the sigmoid and adhered to the bladder dome.

-CT Abdomen with gastrografin (water-soluble contrast medium) injected transanal: at 55 cm from the anal rhyme there is a

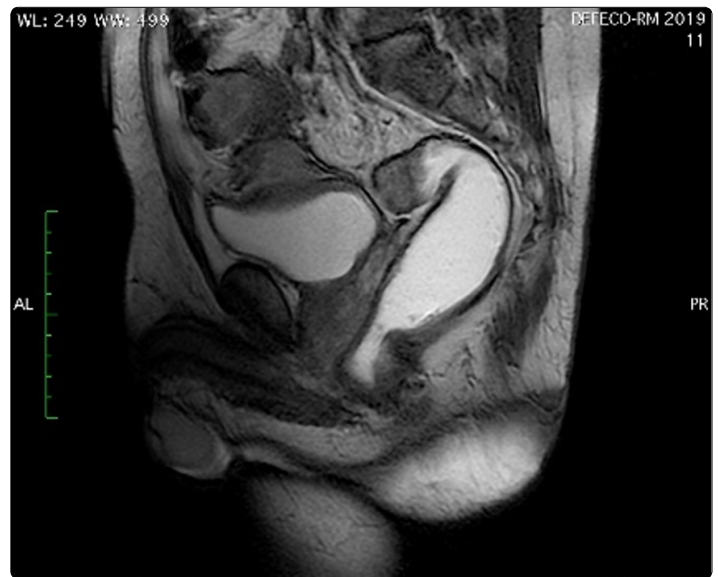voluminous cavitated expansive formation and thick walls with a lumen that is fecaloid with a large collar of 20 x 20mm (photo 1).



-Colon Virtual CT: pseudo-diverticular formation confirmed by gas, with thickened walls, of about 5.5 x 4.8 cm; some small sigmoid diverticula with a large collar and an intact sac (photo 2).



-Defeco MRI: M (<20mm) and H (> 50mm) lines higher than the reference values, both at rest and during the Valsava maneuver, as shown by signs of relaxation of the pelvic floor. Acute anorectal angle (<90 °) both at rest and during an attempt to evacuate, compatible with signs of hypertonicity of the pubo-rectal muscle. Conclusions: failure to evacuate despite repeated attempts. Paradoxical contraction of the pubo-rectal. Dysynergic defecation (photo 3).



-Anorectal manometry not performed due to patient intolerance

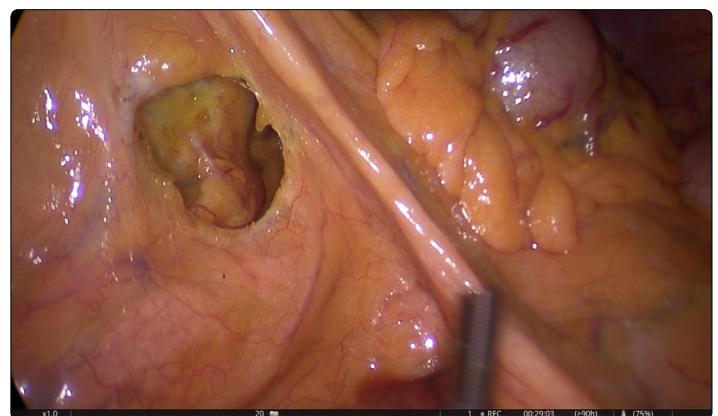
-Cleveland Clinic Constipation Scoring System administered fifteen days before surgery with a score of 12

### Laparoscopic Technique Notes

Patient supine and with legs spread. First and second operators to the patient's right. Third operator between the patient's legs. Instrumentalist to the right of the patient. Left patient monitor and patient head service monitor.

Pneumoperitoneum induction by Verres needle at the Palmer point and access with the right para-umbilical optical trocar. 5 mm trocars in the right hypochondrium and 10 mm in the right iliac fossa. 5 mm trocar in left iliac fossa.

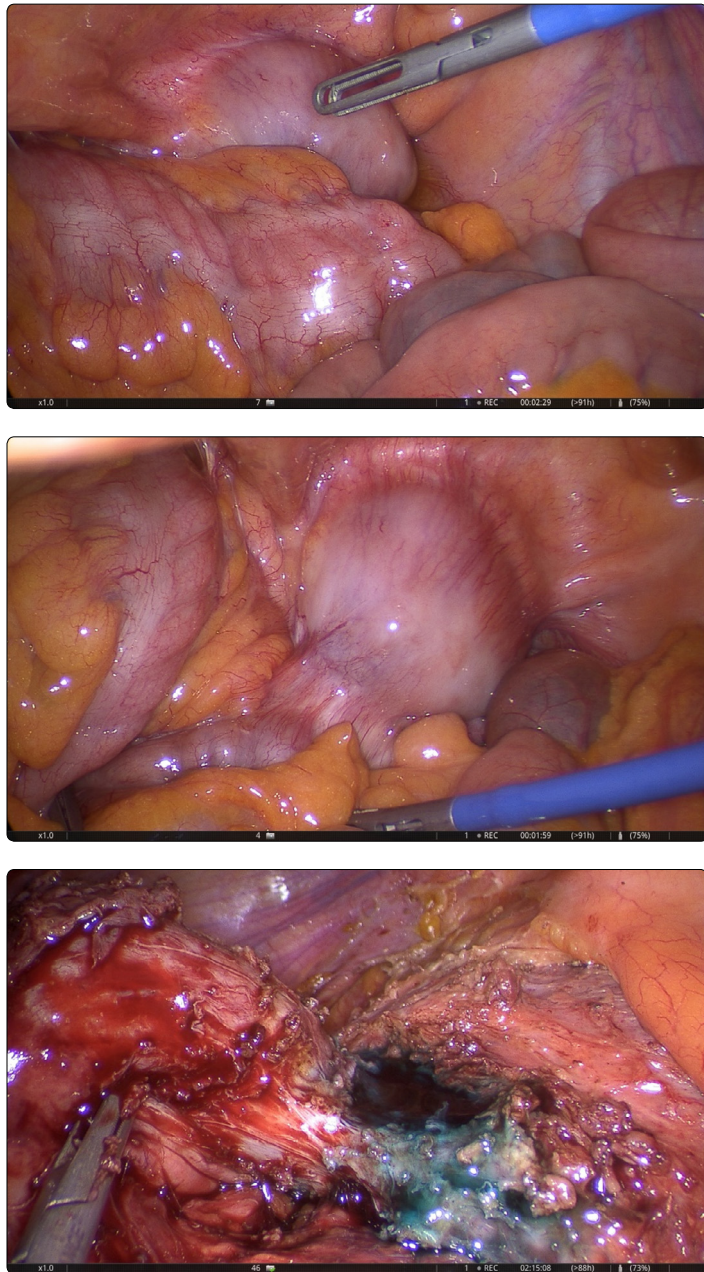
Colo-epiploic detachment and extensive mobilization of the splenic flexure of the colon by opening the Melani window (photo 4).



The release of the voluminous diverticulum from the bladder dome was intriguing because the bottom of the diverticulum infiltrated the muscular wall of the bladder (photo 5, 6). During



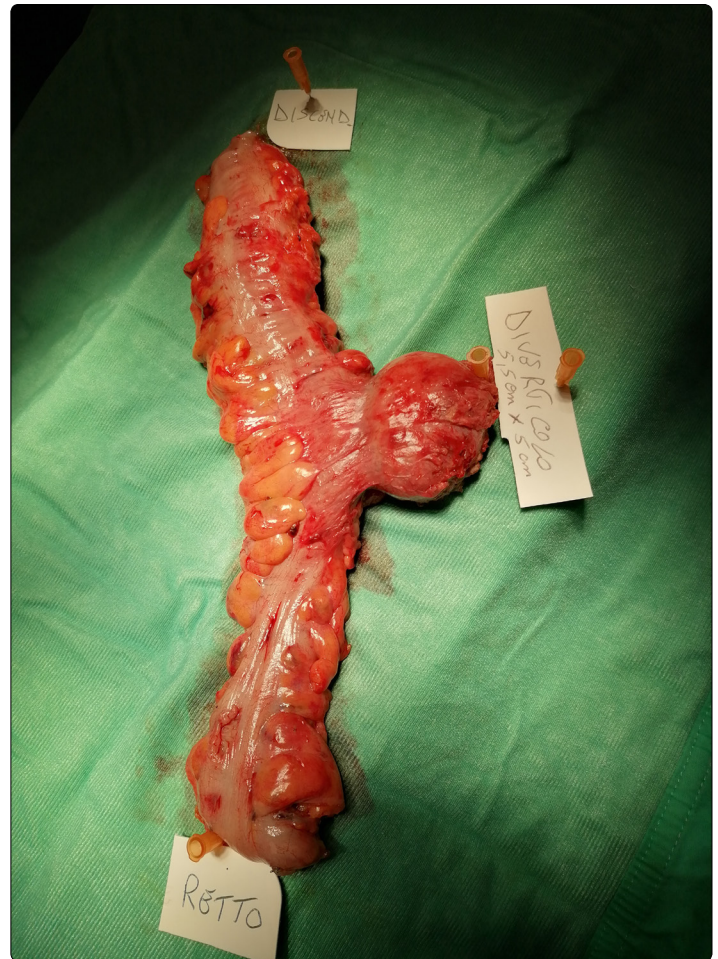traction maneuvers, a small lesion of the bladder dome is determined which is repaired and tested with methylene blue trans Foley catheter (photo 7).



Section of the descending colon by Idrive 60 mm violet charge. Section, at this level, of Drummond's marginal artery. The meso is not fan-removed together with the sigmoid but the section between meso and sigma is carried out close to the sigmoid so as to leave the meso-sigma intact up to the intraperitoneal rectum. The section of the intraperitoneal rectum is performed under endoscopic guide to be sure that the third Houston valve (O'Beirne sphincter) is removed (together) with the sigmoid. T-T colorectal anastomosis is made (packaging) by EEA 31 according to Knight and Griffen. Hydropneumatic test control of the anastomosis. Drain in Douglas. (Photo 8 surgical piece).

### Postoperative

Clinical course characterized by a slight delay in canalization and widespread edema in the lower limbs. Pharmacological treatment. Bladder catheter removal on 10th postoperative day. Discharged on 12th postoperative day.



### Hospitalization After 27 Days From Surgery

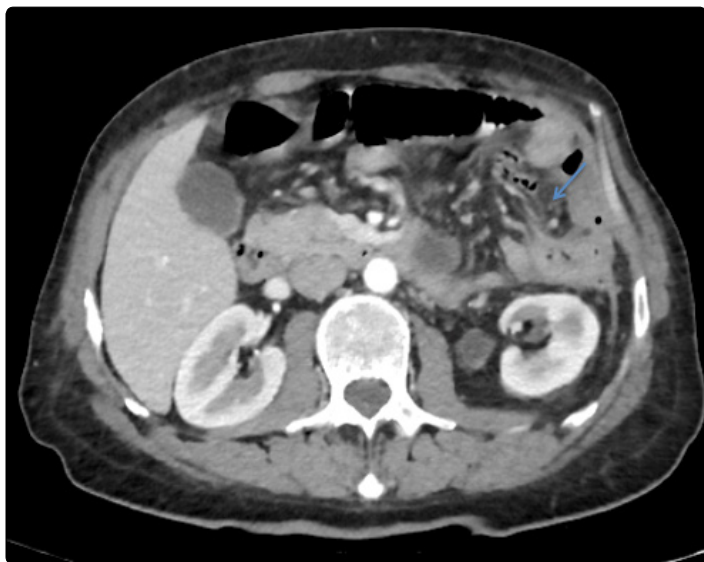The patient returns complaining of hyperpyrexia associated with pain in the hypochondrium region and left flank. No constipation.

Performs Abdomen Ultrasound, Abdomen CT with injected contrast medium (photo 9 internal hernia), Chest X-ray and Urine culture. The instrumental examinations show a pseudocapsulated collection with hydroaero content extended from the left subfrenal site, along the parietocolic shower, up to the ipsilateral iliac fossa of 170mm x 33mm. ESR, PCR and PCT altered.

Broad-spectrum antibiotic therapy for 72 hours but the clinical and laboratory conditions did not improve therefore it was decided to carry out exploratory laparoscopy considering that guided CT drainage was difficult investigative.

The laparoscopic exploration of the abdominal cavity revealed the abscess along the left laterocolic shower that was being drained. Some jejunal loops appear modestly extended in subphrenic and

perisplenic space, below the transverse colon meso mobilized in the first intervention for the mobilization of the splenic flexure, there is a further abscess collection with twisting of the jejunal loop herniated under the meso described. The release of the jejunal loop was difficult therefore laparotomy is performed for the section of the herniated jejunal loop and reconstruction by means of mechanical jejunal-jejunal L-L anastomosis. Regular course and discharge after six days.



## Discussions

Colonic diverticular disease is common but rarely presents as a singular giant diverticulum. Overall there is an equal sex distribution, with most cases involving patients who present in the seventh decade of life (reported range, 32-90 years) [3, 5, 6]. Choong defined a GCD as one with a diameter of more than 4 cm [7]. Most diverticulae present on the antimesenteric border of the sigmoid colon and have a diameter ranging from 4 to 9 cm, with a minority exceeding 25 cm [4].

Patients with GCD may have an asymptomatic course with a palpable abdominal mass or present with nonspecific symptoms, like fever, anemia, tenesmus, early satiety, vomiting, diarrhea, constipation, abdominal pain, weight loss, abdominal distension or with complications like lower gastrointestinal bleeding, intestinal obstruction, volvulus and acute abdomen (acute presentation in 30-35% of the patients). There have been colojejunal and colovesical fistulas reported as well [8].

The origin and pathogenesis of GCD is uncertain. Boijssen described two theories. The first assumption was that a GCD is created through a tiny ostium with a unidirectional ball valve mechanism, causing gas entrapment with progressive enlargement of the diverticulum. The second theory suggested that enlargement of the diverticulum was secondary to gas-forming organisms [9]. Both theories, however, are unable to explain the formation of 70% of GCD for which a communicating ostium can easily be demonstrated [7].

Another suggested theory is local perforation of a diverticulum with development of a large abscess that subsequently drains intraluminally [10]. McNutt et al. proposed three histological types of GCD [11]. The type I is called a pseudodiverticulum, is pulsion diverticulum, which gradually increases in size (22% of the cases, according to Steenvoorde et al) [4]. Remnants of muscularis mucosa and muscularis propria may be found in the wall of the diverticulum. Most of the times, the mucosa is not completely intact. If no mucosal remnants are found at all, the GCD is considered a type II (inflammatory GCD, 66% of the cases) [4]. Is the results of a local perforation of the mucosa with an abscess cavity that remains in contact with the lumen of the colon. The wall of the diverticulum only contains reactive scar tissue. Type III is a true giant diverticulum (12% of cases), in which the wall contains all layers of normal bowel wall. Type III diverticula most likely have a congenital origin.

There is no gold standard diagnostic test for this entity, although multiple image studies may suggest its presence [10]. The plain abdominal X-ray may show a round radiolucen gas-filled cyst with an air-fluid level and regular and smooth walls [12]. Barium or Gastrografin enema demonstrates the communication with the colon in 64% of the patients and may show coexistent colonic diverticulosis [4]. Computed tomography is also capable of identifying an existing communication between the cyst and the gastrointestinal tract. In addition, it can give information about possible complications and is useful in the differential diagnosis [8]. Colonoscopy is not considered to be helpful in the diagnosis of GCD and might even be harmful [4]. Surgical treatment of an asymptomatic GCD seems advisable, as GCD can lead to complications such as the development of an acute abdomen, or the development of an adenocarcinoma inside the diverticulum [13].

Nigri et al. in their systematic review define a colic resection, with an en-bloc resection of the diverticulum, the most frequent treatment performed in 57,2% of the cases [12]. Hartmann's procedure was used in 11,4% of the cases and a diverticulectomy was performed in 10,2% of the cases. In emergency settings Hartmann's resection might be performed. In the previous five years only one patient was treated with a simple diverticulum resection. A laparoscopic colectomy has been reported to be safe, however, it was performed only in 4 patients and only in the previous 5 years.

Non surgical treatments have been rarely used and are considered in patients refusing surgery and in high-risk patients to resolve acute inflammation and are typically followed by a delayed elective segmental colectomy.

## Conclusions

To exclude the presence of polyps and / or adenocarcinoma we had performed a virtual Colon-CT that does not present the same perforation risk of colonoscopy.

The patient also reported symptoms such as: tenesmus and feeling



of incomplete rectal emptying. For these reason we therefore deemed appropriate to carry out the Defeco-MRI and recommend an anorectal manometry. Defeco-MRI, highlighting a paradoxical contraction of the pubo-rectal with associated dysynergic defecation, justified these symptoms and led us to think that the sigmoid diverticulum could be type I (pulsion diverticula). We therefore recommend expanding the panel of pre-operative instrumental examinations also with Defeco-MRI and anorectal manometry in cases with similar symptoms and without clinical picture of acute abdomen. The patient was subsequently sent to a pelvic floor rehabilitation center in the postoperative period.

The laparoscopic sigmoidectomy procedure is based on two key points: the first is the preservation of the sigmoid meso in order to preserve the innervation contained in it and the second is the removal, under endoscopic guide, of the portion of the intraperitoneal rectum containing the Houston's third valve (O'Beirne sphincter) whose hypertonicity is one of the causes of diverticulosis. Preservation of the sigmoid meso, not involving the ligation of the large colic vessels, has made without the ligation of the large colic vessels, i is linked to increased blood loss than the left laparoscopic hemicolectomy for cancer.

The discharge in 12 days and the return after about a month after the surgery allowed us to highlight an abscess along the entire left laterocolic shower and an internal hernia without signs of occlusion. What determined the formation of the abscess is not certain. The crop examination revealed contamination from *Escherichia Coli* and *Enterococcus faecalis*. The most plausible hypothesis is that a hematoma, not well drained from the drainage tube, has become infected. The internal hernia position confirmed that the laparoscopic colectomy must include the closing of the meso, also by glues, due this complication, although rare, has been described.

The histological examination reported: megadiverticular structure in whose wall muscle architecture is not longer recognizable and it is replaced by thick and dense fibrous tissue with active granulation tissue. It was therefore considered a Type II diverticulum.

## References

1. Praveen BV, Suraparaju L, Jaunoo SS, Tang T, Walsh SR, et al. (2007) *Giant colonic diverticulum: an unusual abdominal lump*. J Surg Educ 64: 97-100.
2. Naber A, Sliutz AM, Freitas H (1995) *Giant diverticulum of the sigmoid colon*. Int J Colorectal Dis 10: 169-172.
3. Bonvin M, Bonte G (1946) *Diverticules giant due sigmoide*. ArchMal Appar Dig Mal Nutr 35: 353-355.
4. Steenvoorde P, Vogelaar FJ, Oskam J, Tollenaar RA (2004) *Giant colonic diverticula. Review of diagnostic and therapeutic options*. Dig Surg 21: 1-6.
5. Grover H, Nair S, Hertan H (1998) *Giant True Diverticulum of Sigmoid Colon*. The Am Jour of Gastr 93: 11.
6. Chaiyasate K, Yavuzer R, Mittal V (2006) *Giant sigmoid diverticulum*. Surgery 139: 276-277.
7. Choong CK, Frizelle FA (1998) *Giant colonic diverticulum. Report of four cases and review of the literature*. Dis Colon Rectum 41: 1178-1185.
8. Toiber-Levy M, Golffier-Rosete C, Martinez-Munive A (2008) *Giant sigmoid diverticulum: case report and review of the literature*. Gastreterologie Clinique Biologique 32: 581-584.
9. Boijssen E (1956) *Riesendivertikel im sigmoid*. Rortschr Roentgenstrahl 84: 760-761
10. Vanderstappen JHH, Hoofwijk AGM, Sikkink CJJM (2014) *A rare complication of colonic diverticulosis: giant diverticulum. Case report and overview of pathophysiology, diagnosis and therapeutic options*. Acta Chirurgica Belgica 114: 206-208.
11. McNutt R, Schmitt D, Schulte W (1998) *Giant colonic diverticula – three distinct entities. Report of a case*. Dis Colon Rectum 31: 624-628.
12. Nigri G, Petrucciani N, Giannini G (2015) *Giant colonic diverticulum: clinical presentation, diagnosis and treatment: systematic review of 166 cases*. World J Gastroenterology 21: 360-368.
13. Custer TJ, Blevins DV, Vara TM (1999) *Giant colonic diverticulum: a rare manifestation of a common disease*. J Gastrointest Surg 3: 581-584.

**Copyright:** ©2020 Raffaele Porfidia, et al. This is an open-access article distributed under the terms of the Creative Commons Attribution License, which permits unrestricted use, distribution, and reproduction in any medium, provided the original author and source are credited.