

Hybrid Coronary Revascularization Vs Traditional Coronary Artery Bypass Graft: A Better Revascularization Modality

Sumera Nasim^{1*}, Khalid Galal², Waleed Shaker³

¹Specialist interventional cardiology Life Care Hospital Abu Dhabi, Assistant professor Hamdard University, Pakistan

²Consultant interventional cardiologist Life Care Hospital Abu Dhabi

³Consultant cardiac surgeon Burjeel Hospital Abu Dhabi

*Corresponding author

Sumera Nasim, Specialist interventional cardiology Life Care Hospital Abu Dhabi, Assistant professor Hamdard University, Pakistan.

Submitted: 29 May 2022; Accepted: 30 May 2022; Published: 01 Jun 2022

Citation: Sumera Nasim, Khalid Galal, Waleed Shaker (2022) Hybrid Coronary Revascularization Vs Traditional Coronary Artery Bypass Graft: A Better Revascularization Modality. *Cardio Open*, 7(2): 248-253.

Abstract

Background: Hybrid coronary revascularization (HCR) represents a minimally invasive revascularization strategy in which the durability of the internal mammary artery to left anterior descending combined with percutaneous coronary intervention with drug eluting stents (DES) to treat remaining lesions in different coronary arteries.

Objective: To compare the complication like bleeding, nephropathy and hospital stay MACCE defined as death, stroke, myocardial infarction (MI), stroke, and repeat revascularization in hospital and one year follow up.

Methods: It was correctional study done UAE in 2018- 2019 patient with multi vessel disease who consented with insurance approval were included and decision for which patient went HCR or CABG arm by heart team, patient underwent HCR we used stage manner first LIMA – LAD followed by multi vessel PCI after 24 hrs. And patient were discharged on day 5 of admission

Results: 15 patients underwent hybrid revascularization bleeding rate was high with OR OF 1.0 with 95% C.I of 0.8-1.3 with p value of 0.03, risk of Nephropathy was higher in HCR group with odd ration 1.2 (0.6-1.5) with p value of 0.04 the mean length was 5 vs 7 Days One stroke in CABG group and MACE was HCR with ODD ratio of 1.2 (95% CI 0.8-1.5 with p value of 0.04 observed till one year no in hospital death one year follow up. Three patients died of MACE in CABG and one patient in HCR group.

Keywords: Coronary Arteries Bypass Surgery, Hybrid Revascularization, Percutaneous Coronary Intervention Coronary Artery Disease, Left Internal Mammary Artery, Drug Eluting Stents

Introduction

Hybrid coronary revascularization is a treatment strategy for coronary artery disease (CAD), which offers an alternative to either traditional coronary artery bypass grafting (CABG) or percutaneous coronary intervention (PCI) alone. With the goal being to reduce the risk of the procedure and maximize the benefit, hybrid therapy capitalizes on the strengths of each approach. Since first being described by Angelina and colleagues in 1996, Hybrid coronary revascularization (HCR) procedures introduced in 2011 by the American Heart Association/American College of Cardiology Foundation updated guidelines for coronary artery bypass grafting (CABG) surgery [1,2]. The LIMA-LAD graft may be responsible for the majority of the benefit of CABG surgery. Whether non-LAD vessels are treated with SVGs or PCI may be less important. This is the premise on which the modern era of hybrid coronary revascularization is based. Advances in both surgical and catheter-based techniques have made hybrid

therapy a more attractive option for the treatment of multi-vessel CAD. Using one of several minimally invasive techniques, the left anterior descending coronary artery is grafted with the left internal mammary (LIMA), and percutaneous intervention is applied to single or two vessel coronary arteries. In this approach, the well-established survival benefit of the LIMA graft is capitalized upon and, being done with minimally invasive techniques, the increased morbidity of a full sternotomy is avoided. Additionally, the use of the LIMA graft confers benefit related to the relief of angina and long-term patency [3]. Newer generation drug eluting stents have continued to improve long-term patency following PCI, to rates similar to or even surpassing that of saphenous vein grafts [4,5]. Smaller series continue to be published some study [6-8]. The advantage elderly patient specially women high-risk patients (recent myocardial infarction, prior stroke, frailty, end-stage renal disease on dialysis) in whom a less invasive approach may reduce the operative time and ischemic time [9-11].

Methodology

Total 15 patients were enrolled in a study their baseline characteristic collected by electronic medical records showed in Table 1 patients who underwent HCR with surgical LIMA grafting to the LAD combined with PCI to non-LAD vessels (hybrid

group). The selection of HCR or CABG for revascularization was at the discretion of the clinical site cardiologist and surgeon. Comparative effectiveness trial of HCR and CABG were used in this observational study to compare clinical outcomes with Hybrid vs CABG.

Table 1: Baseline Clinical Features of Patients

comorbid	HRS group n 7	CABG n 8	P value
Age	70 years	56 years	0.04
Race	Bangladeshi 7	Bangladeshi 5	NS
	Pakistan 5	Pakistan 5	NS
	Indian 2	Indian 5	ns
	UAE residents 1	UAE 0	
female	9	6	0.05
HTN (greater than 150/100)	20%	30%	0.2
Diabetes	Mean HBAIC 6.7%	7.7%	0,05
Mean BMI kg/m2	29kg/m ²	26kg/m ²	0,03
dyslipidemia	Mean LDL 140 mg/dl%	130mg/dl	0.6
Renal failure GFR,	1	3 patients	0.
Mean EF	38%	45%	0,04
Prior stroke	5	2	0,05
Prior MI	9	4	0.055
Prior PCI	7	3	0,05
Peripheral arterial disease	1	8	0,05

Inclusion Criteria

- Elderly patient specially women
- High-risk patients (recent myocardial infarction, prior stroke, frailty, end-stage renal disease on dialysis)
- Nephropathy A GFR of 50 ml/min.
- Patients who have left vein disease wit multiverse will excluded for HRS
- Patient with low heart function EF as measured by echo <35%

Exclusion criteria

- Patient with concomitant left main disease with other coronary artery disease
- Patient with three vessel disease with long diffuse disease
- Patient have valvular heart disease with multi vessel CAD
- GFR below 30ml/min.

Statistical Analysis

Data was entered in SPSS version 24 base line characteristics

Table 2: In Hospital Outcomes Measurement in Two Groups

Outcome	HRS	CABG	ODD ratio	P value
Bleeding	5	3	1.2 (95% C.I 0.9-1.5)	0.4
stroke	no	I	2 (95% CI 1-3)	0.6
Mean hospital stay	5 days	12 days	OR 1.1(95% C.I.0.9-1.4)	0.01
Nephropathy	3	1	1,0(95% C.I 0.9-1.5)	0.03
RE MI	3	1	1.0(95%C. I of 0.7-1,6)	0.05
Repeat revascularization	3	i	1,2(95% C.I 0,8-1.5)	0.04
Death	o	o	NA	NA

were compared by using independent T test and chis-square test with p value less then<0.5 was considered significant and for outcome variable multiple variate logistic regression analysis by calculating ODD ration with 95% confidence interval with p value less the 0.05 was consider significant

Intervention

HCR was defined as a planned surgical revascularization of the LAD combined with percutaneous revascularization of at least one non-LAD target and stenting of other lesions by PCI with DES was done after 24 hrs. Conventional CABG was performed by all the surgical venous and arterial conduit

Outcome Measures

The primary outcome was the incidence of MACC bleeding, nephropathy hospital stay defined as death, stroke, myocardial infarction (MI), or repeat revascularization at 12 months following the initial procedure described in Table 2.

Results

In HCR more elderly more patient which have high risk features like prior stroke MI in CABG group more patient with diffuse CAD more obese and more patient having peripheral vascular disease no gender difference in both groups and interesting 14 patients were Asian Expect Racial difference in CAD needs to be further trials is the contribution of genetics play a role in high CAD in UAE.

Selection of Patient in Both Groups

Heart team interventional cardiologist 2 and 2 cardiac surgeon and Cath lab nurse did selection.

HCR Group

- NSTEMI n 3 patients AWTMI 2 patients
- Coronary anatomy coronary total LAD obstruction (CTO)

discrete lesion LCX and RCA and EF 35% first underwent lita to LAD mini key hole surgery remain if remained stable after 24 hrs., PCI of LCX and RCA was done with DES

- Mean EF 38%
- No procedure complication
- Contrast used was 70 cc patient
- Total hospital stay was 4 days
- Use of GP 11b/111a inhibitors in 3 patients
- Bleeding complication at side of PCI 3 patients

one case of HCR was described this patient presented with acute AWTMI coronary anatomy showed ostial LAD with short left main underwent LIMA to LAD and long lesion with 99% RCA EF 40% procedure was uncomplicated hospital stay was 8 days Pic of HRS (123).

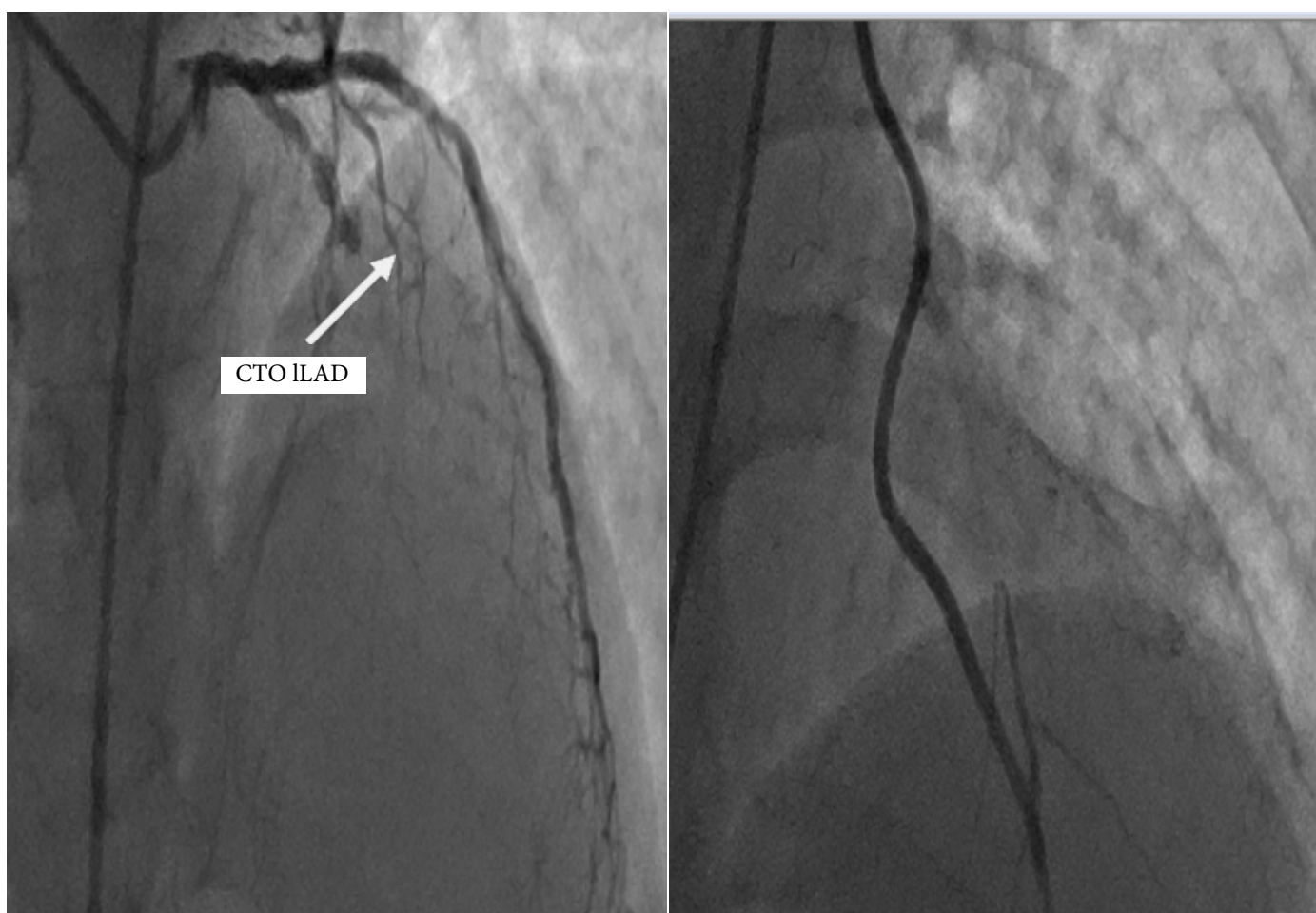

Figure 1: Pre and post procedure with LIMA CTO LAD

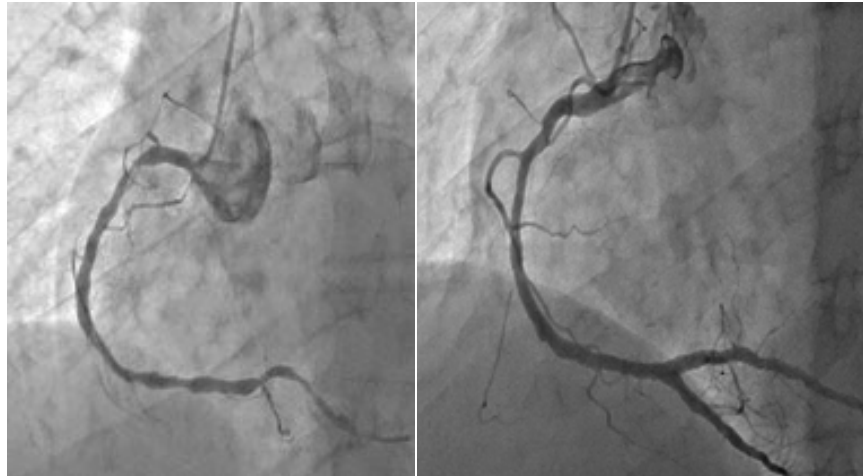


Figure 2: Pre and Post PCI OF RCA

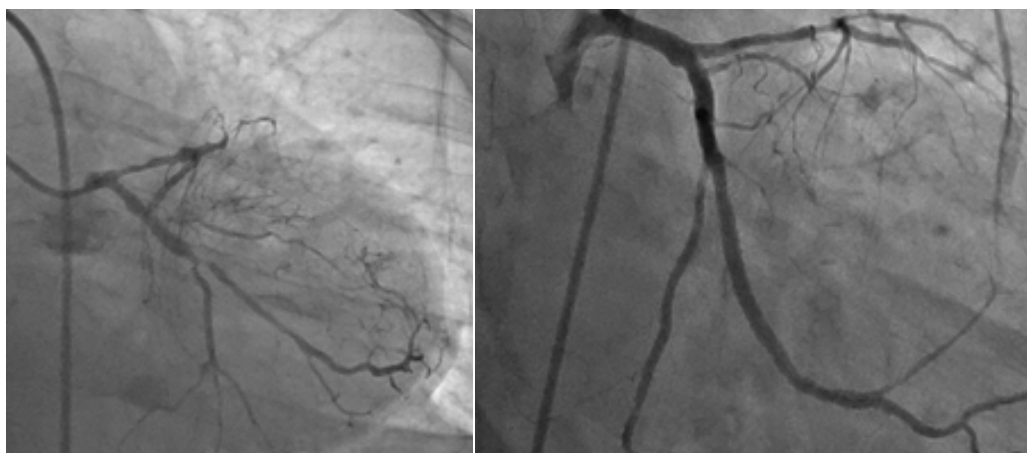

Figure 3: Pre and Post Staged PCI OF LCX

CABG Group

- 3 patients with NSTEMI 5 with unstable angina
- Coronary anatomy 3 patients had LM disease 3 had diffuse three vessel disease
- Mean EF >40
- Bleeding complications in three patients because of reopening
- Use of GP11B/111a and dual ant plates in 4
- No procedure complication
- Mean Hospital stay was 12 days

In Hospital HCR group has more bleeding lesser mean hospital stay but more Repeat revascularization because of high-risk profile of patient acute AWTMI low EF use of GPII/IIIa inhibitors. Better patient satisfaction and low cost In CABG one patient required reopening because of bleeding that lengthen mean stay one stroke no inpatient mortality one patient need repeat revascularization. One-year follow up 3 patients in CABG died of MACE in HCR patient 2 developed nephropathy but not requiring dialysis MACE in two patient required repeat revascularization one patient died of MI.

Discussion

Types of Hybrid Revascularization -stage hybrid: CABG/PCI performed in a hybrid room and in one setting, staged by minutes or days the appeal of the latter is multifold: improved lo-

gistics, lower cost, and better patient satisfaction [12,13]. As in our study, PCI before CABG allows aggressive stenting because if a complication arises or PCI is unsuccessful, CABG can be performed later. Main disadvantage: Performing PCI in an unprotected environment without the benefit of a LIMA-LAD graft and later performing CABG under aggressive antiplatelet agents. PCI after CABG Avoids ant platelet-related bleeding complications CABG has advantage-protected environment with a LIMA-LAD graft LIMA graft patency can be verified at the time of PCI. Disadvantage: In the event of PCI complication/failure, however, a second, higher-risk operation needs to be performed. The latter should be rare, however, as emergent CABG after PCI has a low incidence (<1%) Halkos, et al recently published Study what may be the largest series to date, in which 147 patients who underwent hybrid revascularization between 2003 and 2010 were compared in a 4:1 ratio to patients undergoing multi-vessel off-pump CABG [14]. According to ClinicalTrials.gov, the Hybrid Revascularization Observational Study, funded by the National Heart Lung and Blood Institute, has recently been completed [15]. The largest observational study to date, 14 with planned enrollment of over 6000 patients, this study was intended to inform the design of a pivotal comparative effectiveness trial and more optimally identify the population for whom hybrid therapy may be the better option. Primary outcomes are a composite of death, stroke, MI, or repeat revascularization with follow up over 18 to 21 months. To date, no data was published

from this study. As noted previously, the numerous studies that have been published to date vary in the surgical and interventional followed by PCI techniques, as well as patient selection, anti-platelet strategies and one-stop vs staged approaches as in our study use of gp11/111b inhibitors and antiplatelet were not started as we do LIMA to LAD with PCI, the location of the lesion in the proximal LAD has been identified as an independent risk factor for in-stent restenosis with rates between 19% and 44% [16-18]. As occurred in our study with ostial LCX requiring Repeat PCI the LIMA-LAD graft has excellent patency rates, which correlates with increased event-free survival. 5-year patency rate ranges between 92% and 99% and at 10 years between 95% and 98%.

With PCI, the location of the lesion in the proximal LAD has been identified as an independent risk factor for in-stent restenosis with rates between 19% and 44%. The LIMA-LAD graft has excellent patency rates, which correlates with increased event-free survival. 5-year patency rate ranges between 92% and 99% and at 10 years between 95% and 98%. In control trial 104 patients with average 18 months follow-up Hybrid significantly reduced in-hospital time and transfusion rate Lower MACCE rate 99% vs. 90.4% than Off-pump after 18 months follow-up as described by PR Moreno 2020 JACC Review showed less MACE as our finding. HRS technique has advantages in elderly similar finding described in journal of Geriatric [19-23].

Limitation of our study

This was observational study with only six patients because its novel technique and lot of cost we need large randomized trial for efficacy hybrid revascularization.

Strength of the study

It introduced the patient's alternative option for patients, which are high risk for surgery, are benefited from HRS and more patient satisfaction less MACE and shorter stay.

List of Abbreviations

CAD: Coronary Artery Disease
PCI: Percutaneous Coronary Intervention
HRS: Hybrid Revascularization
LIMA: Left Internal Memory Artery
LCX: Left Circumflex Artery
RCA: Right Coronary Artery
LAD: Left Anterior Descending Artery
CTO: Chronic Total Occlusion
DES: Drug Eluting Stents
GFR: Glomerular Filtration rate ml/min

Conclusion

In this study, we found hybrid revascularization has more benefits less MACE, patient satisfaction and decrease stay in hospital and one-year follow up compared to CABG patients. We need larger scale studies, training of heart team for hybrid revascularization and more centers should be open for hybrid revascularization, population should be benefited with because CABG refusal is high so death from coronary disease is also is no one cause of death in patients with multivessel disease with low heart function will be reduced the one factor which need atten-

tion as this study was done in UAE where insurance covered the procedure but in Pakistan this issue needs to be discussed health policy maker.

References

1. Angelini, G. (1996). Integrated left small thoracotomy and angioplasty for multivessel coronary artery revascularization. *Lancet*, 347, 757-758.
2. Hillis, L. D., Smith, P. K., Anderson, J. L., Bittl, J. A., Bridges, C. R., & et al. (2011). Association Task Force on Practice Guidelines 2011 ACCF/AHA Guideline for Coronary Artery Bypass Graft Surgery: Executive Summary: A Report of the American College of Cardiology Foundation/American Heart. *Circulation*, 124, 2610-2642.
3. Loop, F. D., Lytle, B. W., Cosgrove, D. M., Stewart, R. W., Goormastic, M., & et al. (1986). Influence of the internal-mammary-artery graft on 10-year survival and other cardiac events. *New England Journal of Medicine*, 314(1), 1-6.
4. Modrau, I. S., Nielsen, P. H., Nielsen, D. V., Christiansen, E. H., Hoffmann, T., & et al. (2020). Outcome of hybrid compared to conventional revascularization in multivessel coronary artery disease: A matched-group comparison of 3-year outcome following hybrid myocardial revascularization, conventional coronary artery bypass grafting, and percutaneous coronary intervention. *Scandinavian Cardiovascular Journal*, 54(6), 376-382.
5. Yan, T. D., Padang, R., Poh, C., Cao, C., Wilson, M. K., & et al. (2011). Drug-eluting stents versus coronary artery bypass grafting for the treatment of coronary artery disease: a meta-analysis of randomized and nonrandomized studies. *The Journal of Thoracic and Cardiovascular Surgery*, 141(5), 1134-1144.
6. Puskas, J. D., Williams, W. H., Mahoney, E. M., Huber, P. R., Block, P. C., & et al. (2004). Off-pump vs conventional coronary artery bypass grafting: early and 1-year graft patency, cost, and quality-of-life outcomes: a randomized trial. *JAMA*, 291(15), 1841-1849.
7. Narasimhan, S., Srinivas, V. S., & DeRose, J. J. (2011). Hybrid coronary revascularization: a review. *Cardiology in review*, 19(3), 101-107.
8. De Cannière, D., Jansens, J. L., Goldschmidt-Clermont, P., Barvais, L., Decroly, P., & et al. (2001). Combination of minimally invasive coronary bypass and percutaneous transluminal coronary angioplasty in the treatment of double-vessel coronary disease: two-year follow-up of a new hybrid procedure compared with "on-pump" double bypass grafting. *American Heart Journal*, 142(4), 563-570.
9. Harskamp, R. E., Bagai, A., Halkos, M. E., Rao, S. V., Bachinsky, W. B., & et al. (2014). Clinical outcomes after hybrid coronary revascularization versus coronary artery bypass surgery: a meta-analysis of 1,190 patients. *American heart journal*, 167(4), 585-592.
10. Modrau, I. S., Nielsen, P. H., Bøtker, H. E., Christiansen, E. H., Krusell, L. R., & et al. (2015). Feasibility and early safety of hybrid coronary revascularisation combining off-pump coronary surgery through J-hemisternotomy with percutaneous coronary intervention. *Eurointervention: Journal of Europcr in Collaboration with the Working Group on*

Interventional Cardiology of the European Society of Cardiology, 10(10), e1-6.

11. Hu, S., Li, Q., Gao, P., Xiong, H., Zheng, Z., & et al. (2011). Simultaneous hybrid revascularization versus off-pump coronary artery bypass for multivessel coronary artery disease. *The Annals of thoracic surgery*, 91(2), 432-438.
12. Kon, Z. N., Brown, E. N., Tran, R., Joshi, A., Reicher, B., & et al. (2008). Simultaneous hybrid coronary revascularization reduces postoperative morbidity compared with results from conventional off-pump coronary artery bypass. *The Journal of thoracic and cardiovascular surgery*, 135(2), 367-375.
13. Halkos, M. E., Vassiliades, T. A., Douglas, J. S., Morris, D. C., Rab, S. T., & et al. (2011). Hybrid coronary revascularization versus off-pump coronary artery bypass grafting for the treatment of multivessel coronary artery disease. *The Annals of Thoracic Surgery*, 92(5), 1695-1702.
14. Katz, M. R., Van Praet, F., de Canniere, D., Murphy, D., Siwek, L., & et al. (2006). Integrated coronary revascularization: percutaneous coronary intervention plus robotic totally endoscopic coronary artery bypass. *Circulation*, 114(1_supplement), I-473-I-476.
15. Bonatti, J., Schachner, T., Bonaros, N., Jonetzko, P., Öhlinger, A., & et al. (2008). Simultaneous hybrid coronary revascularization using totally endoscopic left internal mammary artery bypass grafting and placement of rapamycin eluting stents in the same interventional session. *Cardiology*, 110(2), 92-95.
16. Dixon, L. K., Akberali, U., Di Tommaso, E., George, S., Johnson, T., & et al. (2022). Hybrid coronary revascularization versus coronary artery bypass grafting for multivessel coronary artery disease: A systematic review and meta-analysis. *International Journal of Cardiology*, 359: 20-27.
17. Wang, C., Li, P., Zhang, F., Li, J., & Kong, Q. (2021). Is hybrid coronary revascularization really beneficial in the long term. *European Journal of Cardio-Thoracic Surgery*, 60(5), 1158-1166.
18. Van den Eynde, J., Bennett, J., McCutcheon, K., Adriaenssens, T., Desmet, W., & et al. (2021). Heart team 2.0: A decision tree for minimally invasive and hybrid myocardial revascularization. *Trends in Cardiovascular Medicine*, 31(6), 382-391.
19. Tajstra, M., Hrapkiewicz, T., Hawranek, M., Filipiak, K., Gierlotka, M., & et al. (2018). Hybrid coronary revascularization in selected patients with multivessel disease: 5-year clinical outcomes of the prospective randomized pilot study. *JACC: Cardiovascular Interventions*, 11(9), 847-852.
20. Basman, C., Hemli, J. M., Kim, M. C., Seetharam, K., Brinster, D. R., Pirelli, L., ... & Patel, N. C. (2020). Long-term survival in triple-vessel disease: Hybrid coronary revascularization compared to contemporary revascularization methods. *Journal of Cardiac Surgery*, 35(10), 2710-2718.
21. Hannan, E. L., Yi-Feng, W. U., Cozzens, K., Tamis-Holland, J., Ling, F. S., & et al. (2021). Hybrid coronary revascularization vs percutaneous coronary interventions for multivessel coronary artery disease. *Journal of Geriatric Cardiology: JGC*, 18(3), 159-167.
22. Moreno, P. R., Stone, G. W., Gonzalez-Lengua, C. A., & Puskas, J. D. (2020). The hybrid coronary approach for optimal revascularization: JACC review topic of the week. *Journal of the American College of Cardiology*, 76(3), 321-333.
23. Esteves, V., Oliveira, M. A., Feitosa, F. S., Mariani Jr, J., Campos, C. M., & et al. (2021). Late clinical outcomes of myocardial hybrid revascularization versus coronary artery bypass grafting for complex triple-vessel disease: Long-term follow-up of the randomized MERGING clinical trial. *Catheterization and Cardiovascular Interventions*, 97(2), 259-264.

Copyright: ©2022 Sumera Nasim, et al. This is an open-access article distributed under the terms of the Creative Commons Attribution License, which permits unrestricted use, distribution, and reproduction in any medium, provided the original author and source are credited.