

Human-monkey pox disease: An educational CME article

Dr. Aamir Jalal Al-Mosawi

Advisor in Pediatrics and Pediatric Psychiatry and expert trainer, The National Training and Development Center and Baghdad Medical City

*Corresponding author

Aamir Jalal Al-Mosawi, Advisor in Pediatrics and Pediatric Psychiatry and expert trainer, The National Training and Development Center and Baghdad Medical City

Submitted: 07 Jun 2022; Accepted: 13 Jun 2022; Published: 25 Jun 2022

Citation: Dr. Aamir Jalal Al-Mosawi. (2022). Human-monkey pox disease: An educational CME article, *Int J Clin Expl Dermatol*, 7(1), 33-43.

Abstract

The zoonotic disease human-monkey pox was first reported in 1970, twelve years after the isolation of monkey pox virus in a laboratory in Denmark in 1958. For decades the disease remained confined to West Africa and the Congo basin. However, during the early 2000s, the disease appeared in the USA and Sudan. On the 31st of May, 2002, the European Centre for Disease Prevention and Control reported the occurrence of 557 confirmed cases worldwide including 321 confirmed from 17 European Union/European Economic Area countries, and 236 confirmed cases occurred in ten non-endemic countries outside the EU/EEA. Most of the cases outside the UK, Canada and United States were linked to travel. However, cases with no travel history nor contact with a patient, animals were also reported. The World health organization could not provide an explanation for this multi-country outbreak because for many cases there was no travel links to an endemic region. The aim of this Continuing Medical Education (CME) paper is to provide a practical overview of human-monkey pox disease.

Pox viruses are double-stranded DNA viruses including human-specific viruses, the small pox virus “Variola virus” and molluscum contagiosum virus. Pox viruses (family Poxviridae) also include viruses that infect vertebrates, and arthropods. Four genera of pox viruses include viruses that can infect humans including **orthopox** viruses (Small pox virus, vaccinia virus, cow pox virus, monkey pox virus, and rabbit pox virus); **para pox** (Orf virus, pseudo cow pox, bovine papular stomatitis virus); **yatapox** (Tana pox virus, yaba monkey tumor virus); **molluscipox** (molluscum contagiosum virus). The most common pox viruses are vaccinia and molluscum contagiosum. It is worth mentioning that chicken pox (Varicella) is caused by the herpes virus varicella zoster which is not a pox virus. Small pox virus used to be the most important of the pox viruses before its eradication as it killed and disfigured millions of individuals throughout the world before its eradication [1-4].

In 1796, Dr. Edward Jenner (Figure-1A) used cowpox virus instead of smallpox virus in Britain and contributed to the decline of smallpox infections in Europe and North America only. In January 1967, the World Health Organization launched the global eradication program of smallpox which was achieved during October 1977, and the last patient in the world affected by small pox recovered from this disease in Somalia (Figure-1B) [5, 6].



Figure-1A: Edward Jenner (May, 17, 1749-January, 26, 1823), a British physician



Figure 1B: Ali Maow Maalin (1954-July 2013), a Somali hospital cook and health worker Monkey pox, an orthopoxvirus that cause a zoonotic vesicular-pustular disease similar small pox disease. Its occurrence in humans was first reported in 1970 in the Democratic Republic of the Congo (Zaire). Thereafter, the disease spread primarily to West and Central Africa.

Georges, Matton, and Courbot-Georges (2004) warned that the appearance of monkey pox in the United States of America indicates the spread of the virus outside the endemic area which is associated with possible global threats of variable seriousness. They considered the appearance of monkey pox in the United States of America a genuine emergency because monkey pox had been limited to Africa for decades. They emphasized that monkey pox as "miniature smallpox" in Africa with an endemic (zoonotic) mode associated with reservoirs including wild rodents (mainly squirrels) and species of monkeys. Georges, Matton, and Courbot-Georges reported that the virus was introduced in 2003 in the United States of America, via Gambia rats and wild squirrels (all African species), and transmitted to prairie dogs, and thereafter, infected humans [6].

Late during the year 2019, Ellen M Beer and V Bhargavi Rao from London reviewed the literature and found that the mortality rates of human-monkey pox disease ranged from 1 to 11%. They also emphasized that patients infected with monkey pox virus outside Africa have been increasingly reported during the previous years. They stressed that the outbreaks of monkey pox in humans in Nigeria (2017-18) and Cameroon (2018) were reported from areas where monkey pox in humans has not been reported for more than two decades, suggesting the occurrence of changes in the epidemiology of the virus. They also emphasized the evidence suggesting an increase in yearly cases of human-monkey pox in the Democratic Republic of the Congo, and also a significant increase in human-monkey pox outbreak cases outside the Democratic Republic of the Congo during the period from 2010 to 2018, especially in the Central African Republic. Beer and Rao thought that the geographical pattern in the Nigeria outbreak (2017-2018) suggested the possibility of a new zoonotic reservoir [6].

Early during the year 2022, Eveline M Bunge from the Netherlands, Bernard Hoet from Switzerland, Liddy Chen from USA, Florian Lienert from Germany, and their research team emphasized that patients infected with monkey pox virus outside Africa have been increasingly reported during the previous years, and thus suggesting and increasing global relevance of the disease. Bunge et al reviewed the literature and found that the mean age at the onset of human-monkey pox disease has increased from 4 during the 1970s to 21 years during the period from 2010 to 2019. According to Bunge et al, the overall mortality rate was 8.7%, with a considerable difference between clades-Central African (10.6%) and West African (3.6%). Bunge et al also emphasized that since the year 2003, travel-associated cases outside Africa have sometimes associated with outbreaks. Bunge et al suggested that the increase in the cases of human-monkey pox in humans is related to the end of smallpox vaccination because smallpox vaccines had cross-protective effect against human-monkey pox [6].

Preben von Magnus (Figure-2A) and his research team reported the occurrence of 2 non-fatal outbreaks of small pox-like disease in *Cynomolgus* monkeys in Copenhagen during the summer and fall of the year 1958. They called the causative virus which they isolated from the diseased monkeys "Monkey pox virus" [6, 7].



Figure 2A: Preben Christian Alexander von Magnus (February, 25, 1912-August, 9, 1973), a Danish virologist

Thereafter, monkey pox virus has been isolated from animals in other countries including USA, the Netherlands, and France [6, 8, 9].

Svetlana S. Marennikova (Figure-2B) and her research team were the first to publish a paper reporting monkey pox virus. a virus causing a pox-like disease in humans in 1971 [6, 10].



Figure 2B: Svetlana S. Marennikova, a virologist, and honored scientist of the Russian Federation.

However, Ladnyj and colleagues (1972) described clinical and epidemiological observations on the first patient with small pox-like disease infection caused by monkey pox virus in the Territory of Basankusu in the Democratic Republic of Congo.

A 9-month-old child was suspected of having small pox, and was admitted to Basankusu Hospital, Equatorial Province, Democratic Republic of the Congo on the 1st of September, 1970. Monkey pox virus was isolated from the patient's specimens at the WHO Smallpox Reference Centre in Moscow [6, 11].

Bernard Lourie and his research team reported the occurrence of six cases of small pox-like disease caused by monkey pox virus infection in humans, in three West African countries (Liberia, Sierra Leone, and Nigeria) during the period from September 1970 to May 1971 [6, 12].

Stanley O. Foster (Figure-2C) and his research team reported the occurrence of six cases of human infection with monkey pox virus during the period from October 1970 to May 1971. The cases occurred in Liberia, Nigeria, and Sierra Leone [6, 9].




Figure 2C: Stanley O. Foster, a medical Epidemiologist from the USA

The infection in 4 patients was confirmed by virus isolation, whereas in two patients, the infection was diagnosed depending on epidemiological investigations and serological tests. The six patients had not received small pox vaccine and post-infection serological tests revealed high hemagglutination-inhibition and neutralizing titres to pox viruses in 4 of the patients [6, 9].

In 1972, Svetlana S. Marennikova and her research team reported the occurrence of small pox-like disease caused by monkey pox virus in the Democratic Republic of the Congo. The strain isolated by Marennikova et al (Congo-8) was identical to viruses isolated in Liberia (Liberia-1 and Liberia-2 strains) and Sierra Leone (V-70 1 266 strain) [6, 13].

Eke (1972) reported the occurrence of Monkey pox disease in a four-year female patient [6, 14].

In 1976, Arita and Henderson reviewed the literature and found twenty cases of human-monkey pox occurred during the years 1970-1975, in West and Central Africa including the first case which occurred in 1970 and was reported by Ladnyj and colleagues (1972).

Five cases occurred also in 1970 in Liberia and Sierra Leone and were reported by Stanley O. Foster and his research team in 1972, in addition to the cases reported by Svetlana S. Marennikova and her research teams in 1971 and 1972.

The diagnosis in thirteen patients was based on the isolation of monkey pox Virus, whereas in seven the diagnosis depended on detection of poxvirus by electron microscopy and/or by the presence of poxvirus antibody in the sera.

Arita and Henderson found that 13 of the 20 patients with monkey pox virus infection were under the age of 5 years, two were between 6 and 15 years of age, and five patients were adults.

Only two patients aged 24 and 30 years had received small pox vaccine before exposure, and 4 of the 20 reported patients died. Three of the 8 patients from Sierra Leone, Liberia, Ivory Coast, and Nigeria, were left with facial pockmarks that didn't disappear after five years.

Arita and Henderson emphasized that the disease was not easily transmitted even to susceptible close contacts. Therefore, they suggested that monkey pox in humans was not transmissible to the extent that allows continuing spread to other humans.

Arita and Henderson considered the disease as had not established as a human disease during that time [6, 15].

Gispén and colleagues (1976) reported three patients (2 from Nigeria and one from Ivory Coast) with monkey pox who had small

pox-like disease. The diagnosis in one patient was confirmed by virus isolation, whereas in the other two patients, the diagnosis was based on epidemiological data [6, 16].

Breman et al (1977) reported the occurrence of monkey pox disease presented with small pox-like disease in a 5-year male patient from Ivory Coast. The case occurred 4 years after the eradication of smallpox from the Ivory Coast, and 18 months after the last case of small pox observed in West and Central Africa [6, 17].

Breman et al (1980) reviewed 47 reported cases of human-monkey pox disease during the years 1970-1979. The cases occurred in five Central and West African countries and were associated with small pox-like disease.

38 of the 47 patients were from Zaire (known as the Democratic Republic of the Congo before the 27th of October, 1971).

The mortality of human-monkey pox disease was about 17%.

Children under 10 years of age accounted for 83% of the cases.

The spread from patient to patient was expected in 4 cases, and 3 of 40 very close family members, contacts (7.5%) became infected,

4 of 123 (3.3%) susceptible contacts became infected at a rate that is much lower than the 25-40% associated with small pox.

Many animals near human-monkey pox patients had orthopoxvirus antibodies, but the natural reservoir(s) and the vector(s) of monkey pox virus couldn't be determined during that time.

During that time Breman et al considered the transmission rate to be low and they thought that the frequency of disease made it unlikely to constitute a public health problem [6, 18].

Jezeq and colleagues (1983) reviewed 57 reported patients from six west and central African countries who acquired human-monkey pox disease. Forty-five patients were from Zaire.

Patients under ten years accounted for 84% of the cases.

The review of Jezeq and colleagues suggested that small pox vaccine can prevent human-monkey pox.

Patients-to-patients transmission was expected in seven cases.

10% of the susceptible close household contacts became infected, and 5% of all susceptible contacts became infected, and therefore the transmission rate was much lower than the transmission rate of small pox which was estimated at 25-40%.

The review of Jezeq and colleagues suggested that monkey pox in humans is a zoonotic disease despite animal reservoir(s) couldn't be determined [6, 19].

Just like Breman et al (1980), Jezeq and colleagues also considered the transmission rate to be low and they also thought that the frequency of disease made it unlikely to constitute a public health problem [6, 18,19, 21].

Merouze and Lesoin (1983) described the second patient with human monkey pox in Ivory Coast who was the fifty-fourth patient. The patient was a three-year female who developed small pox-like eruption, and recovered from the disease [6. 20].

Mutombo and colleagues (1983) reported a six-month girl who developed monkey pox after had been bitten by a wild chimpanzee in Zaire. In 1984, Janseghers et al reported the death of a child from Zaire after developing monkey pox disease. In 1984, Stagles et al described the histopathological and electron microscopy changes observed on a solitary cutaneous monkey pox lesion obtained after the death of a child who died after five days. The lesion showed papulo-necrosis with early vesiculation and minimal pustulation. Necrosis involved the stratum basale, the basement membrane and nearby areas of the dermal papillae at the centre of the lesion. Cell necrosis involved the next two or three layers of stratum spinosum over the damaged stratum basale and was associated with significant hyperplasia and intracellular edema of the stratum spinosum causing the papule and spindle-cell features. Cell necrosis was also associated with minute vesicles and occasional multinuclear giant cells. Guarnieri-like bodies were observed in the cytoplasm of sweat duct-lining cells in the epidermis and upper corium. There were similar changes in the dermis occurring in association with minimal edema, very little peri-vascular infiltration which included round cells and an infrequent eosinophil. Electron microscopy revealed plentiful of immature and mature orthopoxvirus particles in the cytoplasm of infected epidermal cells [6].

Stagles et al considered the findings to be rather indistinguishable from the papulo-necrotic stage of smallpox (variola) and from human tanapox. Khodakevich et al (1985) reported 6 patients from 2 families with monkey pox observed during January, 1984 in a camp in the extreme south-west areas of the Central African Republic. Of the 11 members of the 2 affected families, only children who had not received small pox vaccine, and a 22 year unvaccinated female patient acquired the disease. The illness was moderate in two patients and very mild in 4 patients. The diagnosis was made by isolation of the virus from skin lesions of four patients and by sero-immunological studies all patients [6].

Arita et al (1985) reviewed 155 patients with monkey pox reported from 1970 to 1983 who had small pox-like disease, but was associated with lymphadenopathy. 80% of the patients were infected possibly through unidentified animal reservoir, and 15% of unvaccinated close contacts became infected [6].

Marennikova et al (1985) reported eight patients (Most of them aged between 7 months to 7 years) with monkey pox; they were from the zone of Bumba, Equatorial Province, Zaire. Only a 29-year female patient had received small pox vaccine before the ill-

ness. Patient to patient transmission of the disease was suspected in some cases [6].

Jezeq et al (1986) reported 5 children who developed monkey pox from two families from of Zaire during May-July 1983. One patient was thought to have acquired the infection from a monkey, and four patients were possibly acquired the infection from an infected human.

Jezeq et al emphasized that human-monkey pox, a zoonosis that had become the most important orthopoxvirus after eradication of small pox. They also emphasized the possibility of human to human transmission in this zoonotic disease [6].

Jezeq, Marennikova, et al (1986) studied the contacts of 214 patients with monkey pox observed in Zaire during the period from 1980 to 1984. Most patients with clinically apparent monkey pox disease and subclinical cases were observed in children less than 10 years of age. Sixteen contacts acquired the infection despite being previously vaccinated with small pox vaccine. 7.2% of the contacts without a vaccination scar, and 0.9% previously vaccinated contacts acquired the infection. Household contacts were four times more likely to acquire the infection than unvaccinated contacts, and seven times more likely to acquire the infection than vaccinated contacts [6].

Khodakevich et al (1987) reported an environmental study of human-monkey pox conducted in northern Zaire during July, 1985. Isolation of monkey pox virus from the squirrels *Funisciurus anerythrus* (Figure-4) suggested that the virus can circulate even in the absence of larger animals including primates, and thus can contribute to the transmission of the virus to humans [6].



Figure 4: Thomas's rope squirrel or redless tree squirrel (*Funisciurus anerythrus*), a species of rodent (Sciuridae family)

Jezeq et al (1987) reported a serological study for monkey pox infections in humans which included about 3460 individuals from

Kole zone of East Kasai, in Zaire. Initial hemagglutination-inhibition tests showed that 667 individuals (19%) were positive.

Radioimmunoassay adsorption tests showed that specific monkey pox antibodies were present in sera of 27 individuals, and the prevalence rate of monkey pox virus-specific antibodies was generally estimated at 0.8%. The highest prevalence rate of (2.4%) was observed in individuals aged 15 to 19 years. Twelve of nineteen children who tested positive for specific monkey pox antibodies had facial and body skin abnormalities suggesting a previous vesiculo-pustular disease. Four of these children had already been registered as monkey pox patients. Seven children didn't have a history of clinical disease [6].

Khodakevich et al reported another environmental study of human-monkey pox disease which conducted in Bumba zone of Zaire during January-February 1986, and was also punished in 1987. The study tested 320 squirrels of *Funisciurus anerythrus* species for monkey pox-specific antibodies and found that 24.7% of them tested positive,

The study also reported a high prevalence of antibody positivity among squirrels *Heliosciurus rufobrachium* suggesting their possible contribution to transmission of the disease to humans [6].

During the years 1980-1985, 282 patients (Aged 1 month to 60 years) with human-monkey pox presented with small pox-like disease were reported in Zaire. 90% of the patients were under 15 years. Early lymphadenopathy is the most important clinical difference between human-monkey pox from smallpox and chickenpox. Patients vaccinated against small pox differed clinically from unvaccinated patients. Pleomorphism and chickenpox-like "cropping" were observed in 31% of the vaccinated patients and in 18% of unvaccinated patients. No deaths occurred in vaccinated patients, whereas 11% of unvaccinated patients died, and a mortality of 15% occurred in the youngest children [6].

Jezeq et al (1988) reviewed 338 patients with monkey pox disease from Zaire observed during the years 1981 to 1986. 245 (72%) were likely to have acquired the disease from an animal and 93 patients were possibly acquired the infection from a human. An animal source of the disease was more likely in children aged 3-4 years (27%) and 5-6 years (20%), whereas animal source was less likely (4%) in patients older than 15 years. The disease was commoner in males (58%) than in females (42%), particularly in patients aged 5-14 years. Patients who are more likely to have acquired the disease from an infected human were more likely to be adults, and also were more likely to females (57%) than males (43%). During that time, Jezeq et al thought that the disease has not become more severe and nor the virus has become more virulent or more easily transmissible from human to human [6].

In 1989, Marennikova emphasized that human-monkey pox disease was present in seven countries of Equatorial Africa, but about

70% of cases occurred in Zaire. She also emphasized that human monkey pox may be associated with an asymptomatic course [6].

In 1991, Meyer et al reported the occurrence of human-monkey pox for the first time in Gabon. Four children from one family were affected, the virus was isolated from the blood of one child, and two of them died because of hemorrhagic complications, and skin manifestations did not dominate the illness. The source of infection couldn't be determined [6].

Tchokoteu et al (1991) reported the third patient with human-monkey pox from Cameroon. The patient was a seven-year old child [6].

During April 1997, Centers for Disease Control and Prevention reported 71 patients observed during February through August 1996, from 13 villages in Zaire with monkey pox disease, and six of them died. The virus was isolated from 11 patients, and DNA phylogenetic studies showed minor genetic variation suggesting the emergence of a new strain that is different from the strains of human-monkey pox virus from Zaire observed during the years 1970-1979. Centers for Disease Control and Prevention emphasized that human-to-human transmission was responsible for most cases of human-monkey pox observed during the years 1996 and 1997[6].

During December 1997, The World Health Organization (WHO) and Centers for Disease Control and Prevention reported the largest human-monkey pox outbreak ever observed in Zaire (Democratic Republic of Congo) during February 1996 to February 1997. The outbreak included 92 suspected cases. In 1999, Georges and Georges-Courbot thought that stopping small pox vaccination is expected to be associated with increased risk of orthopox viruses including monkey pox virus [6].

In 2002, Hermann Meyer reported the occurrence of 23 case of human-monkey pox in the Democratic Republic of Congo (Zaire) during February and August, 2001. In seven cases patients were infected with both monkey pox and varicella-zoster virus. Five patients died including one who had the two viruses.

In 2002, Erik De Clercq reviewed the literature and found experimental evidence suggesting that cidofovir (Acyclic nucleoside phosphonate analog) can be useful in the treatment and prophylaxis (Pre- and post-exposure) of pox viruses including monkeypox, small pox, vaccinia, and cow pox [6].

During June, 2003, Centers for Disease Control and Prevention reported 53 patients who developed monkey pox disease from three states (Illinois, Indiana, and Wisconsin). Fourteen patients including a child aged below 10 years developed encephalitis and required admission to hospital. The patients had a history of contact with animals and at least two of the patients had a contact with another affected patient. 51 patients had a direct or a close

contact with prairie dogs (*Cynomys* sp.). Prairie dogs belong to the squirrel family "Sciuridae" Black-tailed prairie dogs, *Cynomys ludovicianus* species (Figure-5A) are commonly used as pets. One patient had contact with a Gambian giant rat (*Cricetomys* sp.) (Figure-5B).



Figure 5A: Black-tailed prairie dogs, *Cynomys ludovicianus* species are commonly used as pets



Figure 5B: The Gambian rat (*Cricetomys gambianus*) [African giant pouched rat]

One patient reported a contact with an ill rabbit (Family Leporidae) that had a contact with ill prairie dog at a veterinary clinic. In Illinois, the prairie dogs were housed with Gambian giant rats.

Monkey pox was confirmed by examining 10 patients in Illinois, Indiana, and Wisconsin. Nine of the patients had skin lesions and had monkey pox virus DNA sequence. One patient had no skin lesion and polymerase chain reaction for monkey pox virus was negative. Skin biopsies from five patients were examined by immuno-histochemical testing and revealed orthopox viral antigens in four patients. Monkey pox DNA was also isolated from lymphoid tissue of an affected individual's ill prairie dog. With aim of preventing further outbreaks of monkey pox in humans and also in the United States, the Secretary of Health and Human Services Tommy George Thompson stopped importing rodents from Africa. Thompson also banned distributing, transporting and the sale of prairie dogs and six African rodent species including tree rope and squirrels, squirrels, dormice, Gambian giant rats [6].

Georges, Matton, and Courbot-Georges (2004) warned that the appearance of monkey pox in the United States of America indicates the spread of the virus outside the endemic area which is associated with possible global threats of variable seriousness. They considered the appearance of monkey pox in the United States of America a genuine emergency because monkey pox had been limited to Africa for decades. They considered monkey pox a "miniature smallpox" in Africa with an endemic (zoonotic) mode associated with reservoirs including wild rodents (mainly squirrels) and species of monkeys. Georges, Matton, and Courbot-Georges reported that the virus was introduced in 2003 in the United States of America, via Gambia rats and wild African squirrels, and transmitted to prairie dogs, thereafter, infected humans [6].

Betty Lee Ligon from Baylor College of Medicine reviewed the clinical features of human-monkey pox. Human-monkey pox disease presents with small pox-like clinical picture but the illness is generally milder. Clinical manifestations include fever, headache, muscle pains, back pain, lymphadenopathy.

Patients may have the feeling of discomfort, and feel exhausted, and within one to three days, an early papular rash appears (Figure-6A) which changes to a small pox-like vesicular and pustular rash (Figure-6B) [6].

Thereafter, the rash progress to the crusting stage (Figure-6C). The rash generally begins on the faces, but sometimes seen first on other parts of the body,

Various stages of the rash can be seen at the same time on the face, head, trunk, and limbs.

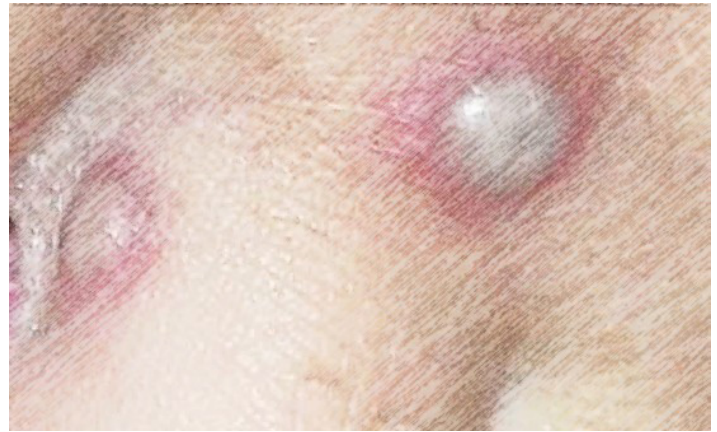

Figure 6A: Within one to three days of the beginning of human monkey pox disease, an early papular rash appears

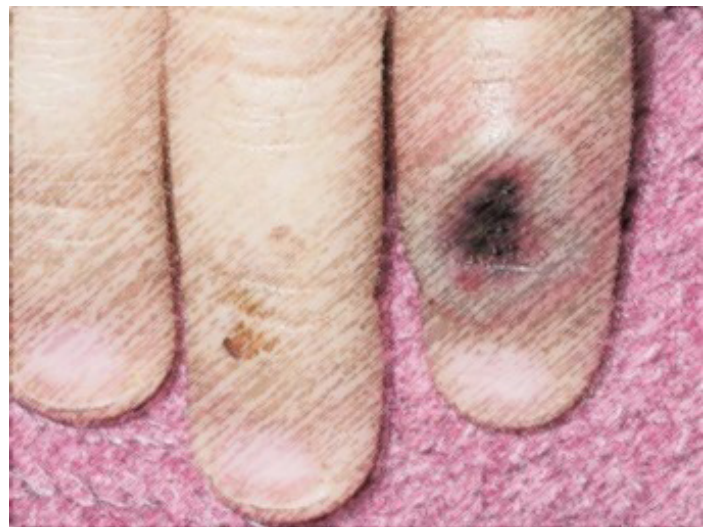

Figure 6B: The initial papular rash changes to a small pox-like vesicular and pustular rash

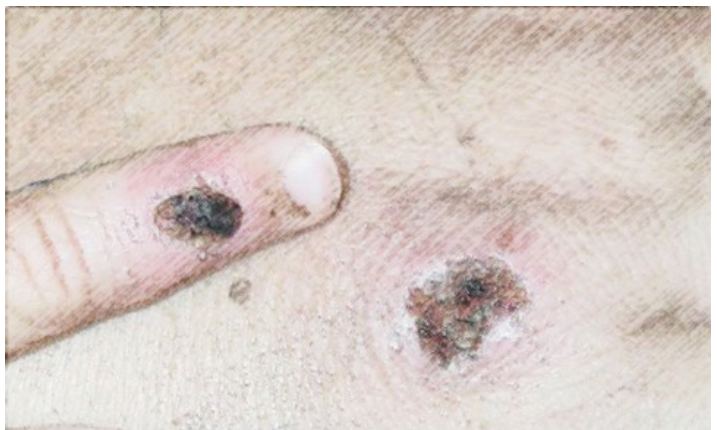

Figure 6C: Thereafter, the rash progress to the crusting stage

The incubation period of human monkey pox is 12 days (7 to 17) days and the symptoms typically continue for 2 to 4 weeks. Human-monkey pox can be transmitted to humans by an animal

(Prairie dogs and Gambia giant rats) bite or direct contact with ill animal's body fluids or lesions. Human-monkey pox can also be transmitted from patient to patient, most probably by respiratory droplets, generally through direct and prolonged face-to-face contact. The disease can also be transmitted from patient to patient by direct contact with body fluids of a patient [6].

Betty Lee Ligon also reviewed the first patient in the United States who developed monkey pox disease during the 2003 outbreak in three states.

A 3-year female patient was hospitalized on the 13th of May, 2003, in central Wisconsin because of the development of fever and cellulites following a bite by a prairie dog. The causative infectious agent of the girl's illness could not be determined.

Thereafter, the mother patient became ill on the second of June 2, 2003, and on the 26th of May 26, electron-microscopic examination revealed the presence of a pox virus in a skin lesion. During the same day, a distributor of exotic animals from southeastern Wisconsin developed a strange illness, and on the 30th of July, 2003, there were 72 confirmed or suspected cases of monkey pox reported from Wisconsin, Illinois, and Indiana [6].

Learned et al (2005) reported an outbreak of human-monkey pox in 2003 which occurred in the Republic of Congo (Zaire) and included 11 patients (under 18 years) with confirmed and suspected monkey pox. Most of the patients were living on the grounds of the Government Hospital in Impfondo, and one patient died. Up to six sequential patient to patient transmissions of the disease were expected [6].

Erika Hammarlund and her research team emphasized that about half of the population of the United States received small pox vaccine before stopping its routine use for civilian individuals in 1972, and military personnel in 1990. After the 2003 monkey pox outbreak, Erika Hammarlund and her research team found three unreported cases of asymptomatic monkey pox disease at 13, 29 and 48 years after receiving smallpox vaccine. The three cases didn't know that they were infected suggesting that the 2003 outbreak in the United States was larger than it was estimated. These three cases suggested that small pox vaccine had a cross protective immunity against monkey pox disease that may remain for many years after receiving the vaccine [6].

Chen et al (2005) emphasized that West African monkey pox virus (COP-58) and Congo basin monkey pox (ZAI-V79) virus are actually different genetically. D10L, D14L, B10R, B14R, and B19R are possibly the genes attributing to virulence, and D14L (ortholog of vaccinia complement protein) is the most likely gene contributing to virulence. In addition, the Congo basin virus is more virulent for cynomolgus monkeys than the West African virus. They suggested that the United States outbreak in 2003 was caused by a West African virus, and that is why it was associated with no mortality [6].

In 2006, Inger K Damon and her colleagues reported the occurrence of monkey pox disease in a child from southern Sudan. The child became ill and developed a generalized pustular rash on the fourth of November, 2005. The child illness occurred in association with occurrence of small clusters of similar disease that was self-limited and not didn't spread widely within the community and was not associated with mortality. The mother of the child was also ill, and on the 6th of November, 2005, real-time polymerase-chain-reaction showed that she was positive for monkey pox virus. Anti-orthopoxvirus IgM was also present in the serum. Monkey pox virus (Congo Basin) was isolated [6].

Anne Walsh Rimoin and her research team considered monkey pox disease to be the most important orthopox virus in the Democratic Republic of Congo (Zaire). The World Health Organization recorded 338 cases during the years from 1981 to 1986. Therefore, only 13 cases recorded from 1986 to 1995. During 1995-1996, more than 500 cases were suspected, a small number of these cases were confirmed by laboratory tests.

Anne Walsh Rimoin and her research team reported the observation of 2734 suspected cases of human monkey pox during the period from January, 2001 to December 2004. It was possible to perform laboratory test on 136 patients (4.9%) only.

51 patients (37.5%) had monkey pox virus infection.
61 patients (44.8%) had varicella-zoster virus infection.
One patient (0.7%) had both infections.

They emphasized that the appearance of human-monkey pox disease in the United States during the year 2003 and in Sudan in 2005 is a warning that the virus can emerge where it has never been reported.

Anne Walsh Rimoin and her research team also emphasized that monkey pox disease can sometime confused clinically with chickenpox [6].

In 2010, Anne Walsh Rimoin and her research team reported the occurrence of 760 laboratory-confirmed cases of human-monkey pox disease in the Democratic Republic of the Congo (Zaire) during the period November 2005 to November 2007. Therefore, the annual cumulative incidence was estimated at 5.53 per 10000 (2.18-14.42).

They reported that the factors associated with increased risk of human-monkey pox disease included:

- Living in forest regions.
- Male gender and age under 15 years.
- Not receiving small pox vaccine.

In 2010, Anne Walsh Rimoin and her research team suggested that individuals who had received small pox vaccine before exposure had a 5.2 fold less risk of acquiring monkey pox disease than individuals who had not received small pox vaccine. They empha-

sized that the incidence during the 1980s was estimated at 0.72 per 10000), and during 2006-2007 was estimated at 14.42 per 10,000 suggesting a 20-fold increase in the disease incidence [6].

In 2010, Pierre Formenty and his research team studied 10 laboratory-confirmed cases and nine suspected cases of human-monkey pox disease which occurred in Unity State, Sudan during September-December 2005, and was associated with no mortality, but was associated with patient to patient transmission.

Pierre Formenty and his team isolated a novel virus belongs to the Congo Basin clade from the studied patient [6].

Graciela Andrei and Robert Snoeck emphasized that cidofovir which is broad-spectrum anti-DNA viruses agent including poxviruses can be beneficial in the treatment of human-monkey pox disease. Cidofovir has in vitro activity against orthopox viruses including monkey pox virus, vaccinia, molluscum contagiosum virus, small pox virus, and cow pox virus, and orf viruses. Cidofovir was first introduced in 1988 by Robert Snoeck and his research team as an effective and selective inhibitor of replication of cytomegalovirus in human [6].

In 2011, Scott K Smith and his research team emphasized that the emergence of monkey pox disease as a zoonotic orthopoxvirus disease with the possibility of transmission from human to human, and suggested that the disease should create the necessary concerns for public health. They controlled a controlled therapeutic animal study.

They treated prairie dogs infected intra-nasally with 65 times the 50% lethal dose (LD50) of monkey pox virus with tecovirimat (ST-246) for 2 weeks, starting on days 0, 3, or after rash onset. 57% of infected prairie dogs that receive tecovirimat died, while 100% of the treated prairie dogs survived the infection, Viable virus and viral DNA couldn't be found or were found at markedly lower levels in prairie dogs treated on 0 or 3 days after infection than the levels in untreated prairie dogs or prairie dogs treated after the onset of rash.

Prairie dogs treated after the onset of rash developed the disease, but all recovered [6].

In 2013, Christina L Hutson and her research team studied respiratory transmissibility of the monkey pox disease in prairie dogs. They found that the respiratory transmissibility of the Congo Basin clade of monkey pox 16.7% which was somewhat higher than West African clade of monkey pox (0%) .

In 2014, Jeffrey R Kugelman and his research team studied 60 samples from patients with human-monkey pox disease in Democratic Republic of the Congo (Zaire) during the period from 2005 through 2007. They reported the presence of four different lineages and a deletion that caused a gene loss in 10 sample (16.7%)

of patient that were likely to have experienced patient to patient transmission ($P=0.0544$). Therefore, they suggested that genomic destabilization and loss of genes can increase disease transmission and severity [6].

Nolen et al (2016) reported more than 600% increase in cases of human-monkey pox in the Bokungu Health Zone of the Democratic Republic of the Congo (Zaire) during the second six months of the year 2013, with 104 suspected cases.

Nolen et al tested 60 patients, and found that 50 (48.1%) of them were positive, while only 10 patients (9.6%) tested negative for monkey pox virus. 50% of individuals who were living with a patient acquired the disease. Nine affected families showed more than one transmission incident.

Nolen et al estimated the average incubation period at 8 days (4-14 days) [6].

Kalthan et al (2016) reported twelve patients (Aged 15 months and 41 years; mean age 25 years) with human-monkey pox disease observed during the period from the 10th of December 2015, to 10th of February, 2016 in the district of Bangassou (Central African Republic). The attack rate of disease was estimated at 2/10000 inhabitants, the mortality was 25%. However, the mortality was 67% among children under 10 years. Fever and rash were the most important manifestations of the disease, and lymphadenopathy was observed in 54.5% of the patients. Ten patients (83%) required admission to hospital for 6 to 28 days, and the mean length of hospitalization was 13 days [6].

Placide K Mbala and his research team reported 222 patients including four pregnant females with human-monkey pox disease observed and followed at the General Hospital of Kole (Sankuru Province, Democratic Republic of Congo) during the period from 2007 and 2011. One of the four pregnant females gave birth to a healthy baby; two pregnant females had miscarriages in the first trimester, and one pregnant female experienced fetal death. The macerated stillborn had diffuse cutaneous maculo-papillary skin lesions involving the head, trunk and limbs, including palms and soles [6].

In 2017, Emmanuel Nakoune and his research team reported 10 patients (3 children and 7 adults) from one family with human-monkey pox disease in the Central African Republic in 2015 and 2016. Most patients developed fever and skin lesions. Two of the three affected children died. This outbreak was caused by Zaire genotype strain [6].

In 2018, Kara N Durski and her research team emphasized that endemic human-monkey pox disease has been reported from more states during the previous decade than during the previous four decades. They also emphasized that human-monkey pox disease have been reported in Central African Republic, Democratic Republic of the Congo, Liberia, Nigeria, Republic of the Congo, and

Sierra Leone since 2016, and monkey pox also occurred in captive chimpanzees in Cameroon [6].

Kalthan et al (2018) emphasized that the yearly cases of human-monkey pox disease increased in the Central African Republic, and there was also an increase in severity and mortality particularly in children. They reported 26 cases which occurred during the period from August to October 2016. The disease affected more children under ten years, and also individuals aged 21-30 years age. The attack rate was estimated at 5/1000 inhabitants and the mortality was 7.7%. The lack of small pox vaccination and a younger age were associated with severe disease [6].

Yinka-Ogunleye et al (2018) emphasized the re-emergence of human-monkey disease in Nigeria as the last case recorded before 2017 occurred in 1978. They reported the occurrence of 146 suspected cases and 42 laboratory-confirmed cases during the first half of the year 2017, and the cases were caused by West African clade [6].

In 2018, Aisling Vaughan and her research team reported two patients with human-monkey disease from the United Kingdom. One patient was identified on 7th September, in Cornwall (South West England), and the second patient was identified on the 11th of September in Blackpool (North West England). The two patients were not epidemiologically related and both patients came to the United Kingdom from Nigeria. They emphasized that the two patients were the first cases occurring outside Africa since 2003 [6].

Eteng et al (2018) re-emphasized the re-emergence of human-monkey disease in Nigeria as the last case recorded before 2017 occurred in 1978. They also confirmed the continuation of the 2017 outbreak into 2018. On the 25th February, 2018, there were 139 and 89 confirmed cases, and six of 89 confirmed cases (6.7%) died [6].

Russo et al (2018) conducted a therapeutic study on *Cynomolgus* Macaques infected with a fatal dose of monkey pox virus. They treated the animals with oral tecovirimat (10 mg/kg) once daily beginning up to eight days after the infection. All animals treated with treatment beginning up to 5 days post-infection survived. Animals treated with treatment beginning 6, 7, or 8 days post-infection had a survival of 67%, 100%, and 50%, respectively. Treatment started up to 4 days post-infection decreased the severity of the disease [6].

Petersen et al (2019) reported the third patient with human-monkey pox disease in the United Kingdom. The patient was a healthcare worker who cared for one of the two patients reported by Aisling Vaughan and her research [6].

Sadeuh-Mba et al (2019) reported a patient with human-monkey pox disease in 2018 in Cameroon, a state where no patients were reported since 1989. The virus in this case was genetically similar

to the virus isolated in the outbreak in Nigeria during the 2017-2018 [6].

Reynolds et al (2019) emphasized the re-emergence of human-monkey pox disease in Sierra Leone after a 44-year after the disappearance of disease. The patients were an 11-month-old boy and, few years later, a 35-year male patient [6].

Erez et al (2019) reported a male patient with human-monkey pox disease who returned from Nigeria to Israel in 2018 [6].

Yinka-Ogunleye et al (2019) reviewed the status of human-monkey pox disease in Nigeria after its re-emergence in 2017, and reported the biggest outbreak of the west African clade of the monkey pox virus. There were 122 [84 (69%) were males] confirmed or probable cases recorded during the period from September 22, 2017, and September 16, 2018. Patients age ranged from 2 days to 50 years (mean: 29 years), and the death rate was 6%. All patients developed generalized vesiculo-pustular rash, with the face being the most affected part. Fever, headache, pruritus, and lymphadenopathy were common. Patients acquired the disease from an animal or from another patient, Yinka-Ogunleye emphasized the endemic nature of the disease in Nigeria, and the role of patient to patient transmission in its spread [6].

Ng et al (2019) reported the diagnosis of human-monkey pox disease in a 38-year Nigerian male on 8th of May, 2019. The patient was hospitalized on 7th of May 7, 2019 because of the development of fever, muscle aches, chills, and nodular skin lesions. Ng et al reported the use of vaccinia vaccine to protect the 22 close contacts [6].

Vaughan et al (2020) emphasized that the third patient who developed human-monkey pox in the United Kingdom was a healthcare worker who acquired the disease from a patient, and of the 134 contacts, four acquired the disease, and all of them survived [6].

Hobson et al (2021) reported three cases from one family of human-monkey pox disease in the United Kingdom. The cases were imported from Nigeria. They emphasized that the index case transmitted the disease to an adult and to a toddler [6].

Rao et al (2022) reported the occurrence of human-monkey pox disease in a male traveler returning to Dallas, Texas from Lagos, Nigeria during July, 2021. Management included:

- Monitoring of the 194 contacts including 144 (74%) flight contacts.
- Anti-viral therapy with tecovirimat.
- Patient's home large-scale decontamination [6].

Costello et al (2022) reported the occurrence of human-monkey pox disease in traveler returning to Maryland from Nigeria [6].

Adler et al (2022) emphasized that brincidofovir and tecoviri-

mat are anti-viral agents that have been approved for small pox treatment, and the available experimental evidence from animal studies suggested their efficacy against monkey pox in animals. Adler et al reviewed the seven patients (4 males and 3 females) in the United Kingdom, who developed human-monkey disease during the period from the 15th of August, 2018, and the tenth of September, 2021. Three of the patients became infected in the United Kingdom including one a health-care worker. Five patients required isolation for more than 21 days (range 22-39 days) because of their lengthy PCR positivity. Three patients received oral brincidofovir 200 mg /week, all of them experienced increased liver enzymes and treatment was stopped. One patient was treated with oral tecovirimat 200mg two times a day for 2 weeks without the occurrence of adverse effects. Treatment shortened the duration of viral shedding and also shortened the illness period, and the patient was hospitalized for ten days. The disease relapsed in one patient six weeks following hospital discharge, and the relapse was mild [6].

Vivancos et al (2022) reported the occurrence of 86 (79 males) confirmed cases of human-monkey pox disease in the United Kingdom during the period from the seventh and 25th May, 2022. Only one patient acquired the disease following travel to an endemic country. Of the seventy-nine male patients, 66 were gay or bisexual [6].

Acknowledgement

The figures in this paper was included in the author's previous publications, but he has their copyright

References

- Buddingh, G. J. (1953). The nomenclature and classification of the pox group of viruses. *Annals of the New York Academy of Sciences*, 56(3), 561-566.
- Mouillot, L., & Netter, R. (1977, October). Identification of Orthopox virus by isoelectrofocusing in a granulated gel. In *Annales de microbiologie* (Vol. 128, No. 3, pp. 417-419).
- Downie, A. W., Taylor-Robinson, C. H., Caunt, A. E., Nelson, G. S., & Manson-Bahr, P. E. (1971). 490 & Matthews. TC, 363-8.
- Hope-Simpson, R. E. (1965). The nature of herpes zoster: a long-term study and a new hypothesis.
- Al-Mosawi AJ. May, 2022 The era of pandemics: Human-monkey pox disease. LAP LAMBERT Academic Publishing: (ISBN-13:978-620-4-97846-8, ISBN-10: 6204978462).
- Behbehani, A. M. (1983). The smallpox story: life and death of an old disease. *Microbiological reviews*, 47(4), 455-509.
- Magnus, P. V., Andersen, E. K., Petersen, K. B., & Birch-Andersen, A. (1959). A pox-like disease in cynomolgus monkeys. *Acta Pathologica Microbiologica Scandinavica*, 46(2), 156-176.
- Prier, J. E., Sauer, R. M., Malsberger, R. G., & Sillaman, J. M. (1960). Studies on a pox disease of monkeys. II. Isolation of the etio-logic agent. *American Journal of Veterinary Research*, 21, 381-384.
- Marennikova, S. S., Shelukhina, E. M., Mal'tseva, N. N., & Ladnyĭ, I. D. (1971). Monkey pox virus--the agent of a pox-like disease in man. *Voprosy virusologii*, 16(4), 468-469.
- Ladnyj, I. D., Ziegler, P., & Kima, E. (1972). A human infection caused by monkeypox virus in Basankusu Territory, Democratic Republic of the Congo. *Bulletin of the World Health Organization*, 46(5), 593.
- Lourie, B., Bingham, P. G., Evans, H. H., Foster, S. O., Nakano, J. H., & Herrmann, K. L. (1972). Human infection with monkeypox virus: laboratory investigation of six cases in West Africa. *Bulletin of the World Health Organization*, 46(5), 633.
- Marennikova, S. S., Šeluhina, E. M., Mal'Čeva, N. N., Čimiškjan, K. L., & Macevič, G. R. (1972). Isolation and properties of the causal agent of a new variola-like disease (monkeypox) in man. *Bulletin of the World Health Organization*, 46(5), 599.
- Eke, R. A. (1972). Monkey-pox in a four-year old girl: case report. *West African Medical Journal*, 21(1), 21-2.
- Arita, I., & Henderson, D. A. (1976). Monkeypox and whitepox viruses in West and Central Africa. *Bulletin of the World Health Organization*, 53(4), 347.
- Gispen, R., Brand-Saathof, B., & Hekker, A. C. (1976). Monkeypox-specific antibodies in human and simian sera from the Ivory Coast and Nigeria. *Bulletin of the World Health Organization*, 53(4), 355.
- Breman, J. G., Nakano, J. H., Coffi, E., Godfrey, H., & Gautun, J. C. (1977). Human poxvirus disease after smallpox eradication. *The American Journal of Tropical Medicine and Hygiene*, 26(2), 273-281.
- Breman, J. G., Steniowski, M. V., Zannotto, E., Gromyko, A. I., & Arita, I. (1980). Human monkeypox, 1970-79. *Bulletin of the World Health Organization*, 58(2), 165.
- Jezeq, Z., Gromyko, A. I., & Szczeniowski, M. V. (1983). Human monkeypox. *Journal of Hygiene, Epidemiology, Microbiology, and Immunology*, 27(1), 13-28.
- Merouze, F., & JJ, L. (1983). Monkeypox: second cas humain observé en Côte d'Ivoire (secteur de santé rurale de Daloa).

Copyright: ©2022: Aamir Jalal Al-Mosawi. This is an open-access article distributed under the terms of the Creative Commons Attribution License, which permits unrestricted use, distribution, and reproduction in any medium, provided the original author and source are credited.