

Eyes can't See What the Mind doesn't know - A case of Pneumothorax Complicating Clavicle Fracture

Ahmed I^{1,3*}, Niaz Z², Kassem W³ and Nabeel M³

¹University of the Southampton, UK

²Mayo Hospital, Lahore Pakistan

³Aldara Hospital and Medical Centre, Riyadh, KSA

*Corresponding author

Iftikhar Ahmed, Consultant, Aldara Hospital and Medical Centre, Riyadh KSA, University of Southampton, UK Yardville Compound, P.O. Box 1105 - Riyadh 11431 Tel: +966 (11) 420-7845, E-mail: iahmed@aldaramed.com

Submitted: 27 Dec 2017; Accepted: 03 Jan 2018; Published: 22 Jan 2018

Abstract

Pneumothorax is an infrequent but serious complication of clavicular fractures. The importance of its prompt recognition and management cannot be overstated. There have been few cases reported in medical literature (English+ Non-English) but all those patients had respiratory signs or symptoms at presentation. We hereby report a case of isolated clavicular fracture associated with pneumothorax where patient had no respiratory symptoms at the time of presentation and diagnosis was missed. This case highlights that clinical signs may be subtle initially, when attention is focused on obvious bony disruption. We advocate obtaining a routine chest x-ray in all patients with displaced clavicular fracture regardless of respiratory status.

Keywords: Pneumothorax, Clavicular Fracture, Thoracocentesis

Introduction

A pneumothorax refers to a collection of gas in the pleural space resulting in collapse of the lung on the affected side. Traumatic pneumothorax results from blunt or penetrating injury that disrupts the parietal or visceral pleura. Trauma may also result in tension pneumothorax which is essentially fatal unless recognised and treated urgently.

Pneumothorax secondary to isolated clavicle fracture is a rare but potentially serious complication. There has been no study to identify risks of pneumothorax in isolated clavicle fractures; however it has been reported to be around 3% in patients with clavicle fractures occurring with first rib or scapular fractures. Most of these patients with traumatic pneumothorax present with symptoms of breathlessness or chest pain along with signs and symptoms of injury. However, younger patients with no previous respiratory history may have no symptoms at the time of initial presentation which may result in missing this serious condition.

This case report describes a rare complication of a pneumothorax secondary to a clavicular fracture, which was missed initially but subsequently recognised and treated with a tube thoracocentesis.

Case report

A 51 year old gentleman with no significant past medical history was brought to the emergency department following a fall from his motor bike whilst driving at a speed of 35 miles per hour. He sustained an injury to his left shoulder but denied any other symptoms. Initial examination revealed an area of tenderness over

the left clavicular region with painful shoulder movement. He was in no respiratory distress and his pulse, blood pressure, respirator rate and oxygen saturations were all within the normal range. His systemic examination was documented as unremarkable.

An x-ray of left shoulder was obtained and reviewed by a junior doctor in emergency department. A diagnosis of left clavicle fracture with a normal shoulder joint and scapula was made. He was managed conservatively with analgesia and a broad arm sling and was discharged home on the same day with a plan to review him in orthopedic clinic after 6 weeks.

As a routine policy, this patient's x-ray was reviewed by a radiologist on the same day and reported a fracture clavicle along with a left pneumothorax (Fig. 1: Loss of lung markings on left side along with clavicular fracture).

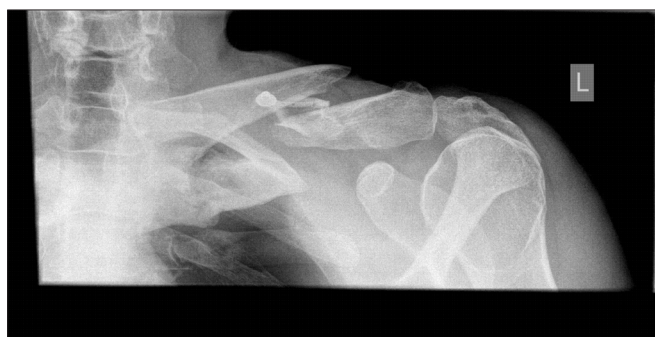

Figure 1: Loss of lung markings on left side along with clavicular fracture

Patient was contacted immediately and brought back to the medical assessment unit. A repeat chest x-ray revealed a moderate left sided pneumothorax with partial lung collapse (Fig. 2: Chest x-ray with obvious moderate size pneumothorax).

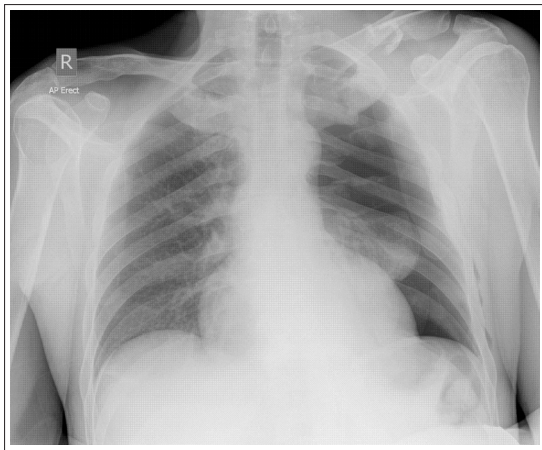


Figure 2: Chest x-ray with obvious moderate size pneumothorax

A chest drain was inserted and he was admitted to the hospital (Fig.3: post intubation lung expansion). Following re-expansion of his lung after two days, chest drain was removed and he was discharged home. He remained well afterwards with no recurrence of pneumothorax and his fracture healed well.

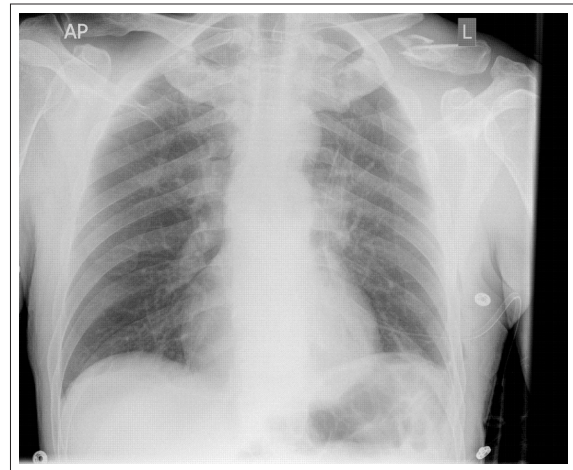


Figure 3: post intubation lung expansion

Literature Review

We found only a small number of case reports of pneumothorax secondary to isolated clavicle fracture on Medline search (Table 1). Two of these cases were reported in language other than English and one of them reported by Longo and Ruggiero is a case of newborn who had clavicular fracture as an obstetric complication resulting in pneumothorax with subcutaneous emphysema and paralysis of the arm [1].

Age, sex	Injury mechanism	Clavicular Fracture	Diagnosis	Management	Reference
28, M	RTA	Displaced	Clinical + Radiological	Chest drain + arm immobilization	Hani et al [2]
19, M	Assault	Displaced	Clinical + Radiological	Chest drain + arm immobilization	Gandham et al [3]
28, M	RTA	Displaced	Clinical + Radiological	Chest drain + arm immobilization	Geraci et al [4]
14, M	RTA	Displaced	Clinical + Radiological	Chest drain + arm immobilization	Yates et al [5]
17, M	Assault, Direct trauma	Displaced	Clinical + Radiological	Chest drain + arm immobilization	Dath et al [6]
19, M	Athletic injury	Minimally displaced	Clinical + Radiological	Chest drain + clavicle splint	Dugdale & Fulkerson [7]
29, M	Athletic injury	Simple	Clinical + Radiological	Chest drain + arm immobilization	Malcolm et al [8]
63, M	Fall	Displaced	Radiological	Arm sling	Steenvoorde et al [9]
35, M	RTA	Displaced	Clinical + Radiological	Chest drain + figure-of-8 clavicular strap	Meeks and Riebel [10]
30, F	Fall	Displaced	Clinical + Radiological	Chest drain + arm immobilization	William et al [11]

It is interesting to note that all of these patients were male and in younger age group (15-35), which might be due to the fact that clavicular fractures are more common in young males. Almost all cases of pneumothorax occur in the setting of displaced clavicular fractures except the case reported by Malcolm et al, and respiratory signs and symptoms, though mostly present, may be absent at presentation (our case and Steenvoorde et al). The treatment usually requires a chest drain but can be conservative in selected cases [7].

Discussion

Isolated fractures of the clavicle are common injuries constituting 4-10% of adult traumatic fractures and 44 % of all shoulder girdle injuries [10]. Most clavicular fractures result from a fall on an ipsilateral shoulder. Other mechanisms of injury include direct blows and falls on an ipsilateral outstretched hand. Anatomically, the apex of the lung lies behind and above the medial one third of the clavicle,

with the anterior scalene muscle, brachial plexus, and subclavian vessel interferences. Hence the complications of clavicle fractures include vascular and brachial plexus injuries and pneumothorax. The overall incidence of these complications is about 1-3%, which includes cases with first rib and scapular fractures in addition to the clavicular fracture. Clavicle fractures occurring with upper rib or scapular fractures are associated with a higher incidence of pneumothorax [11]. This low incidence may lead to complacency in the management of this common fracture. Our case illustrates how this benign-appearing fracture can become life threatening.

The possibility of pneumothorax must be considered in all patients with a clavicle fracture and a thorough clinical assessment, with particular attention to the neurovascular and chest examinations and radiographs of the clavicle are necessary to prevent overlooking these potentially serious complications.

Current treatment guidelines suggest that chest x-ray is only indicated in cases of suspected pneumothorax. However, in the light of this case where patient was asymptomatic at presentation and clinical signs were subtle, we advocate that all patients with displaced fracture of clavicle should have a formal chest x-ray to exclude pneumothorax. Careful inspection of the radiographs for the potential complications is mandatory and cannot be overstated.

Conclusion

Isolated clavicle fractures are relatively innocuous injuries and typically heal with routine immobilization. However they can be associated with life threatening complications and should not always be regarded trivial. Knowledge of possible complications should guide the work-up with this common injury. Thorough history and meticulous physical examination of the chest and neurovascular status with careful scrutiny of pertinent x-rays must be performed to detect serious associated injuries and to avoid delay in definitive treatment. Upright chest x-ray should be obtained in all patients with displaced fracture of the clavicle or un-displaced fracture with or without chest signs or symptoms.

Learning Points

1. The clinician must be mindful that injuries to underlying vital structures, although rare, are potentially serious complications of clavicular fracture.
2. All patients especially young and with no previous respiratory problem may have subtle or no sign and symptoms at presentation.
3. A chest x-ray should be obtained in all patients with suspected pneumothorax or where nature and force of injury is sufficient to cause pneumothorax, for example patients with displaced fractures.
4. Some of these patients may develop delayed pneumothorax and physician must warn and alert patients about this possible complication.

References

1. Longo R, Ruggiero L (1982) Left pneumothorax with subcutaneous emphysema secondary to left clavicular fracture and homolateral obstetrical paralysis of the arm. *Minerva Pediatr* 34: 273-276.
2. Hani R, Ennaciri B, Jeddi I, El Bardouni A, Mahfoud M, et al. (2015) Pneumothorax complicating isolated clavicle fracture. *The Pan African Medical Journal* 21: 202.
3. Gandham S, Nagar A (2013) Delayed pneumothorax following an isolated clavicle injury. *BMJ Case Reports* 2013: bcr1120115168.
4. Geraci G, Pisello F, Sciume C, Sunseri A, Romeo M, et al. (2007) Clavicle fracture complicated by pneumothorax. Case report and literature review. *G Chir* 28: 330-333.
5. Yates DW (1976) Complications of fractures of the clavicle. *Injury* 7: 189-193.
6. Dath R, Nashi M, Sharma Y, Muddu BN (2004) Pneumothorax complicating isolated clavicle fracture. *Emerg Med J* 21: 395-396.
7. Dugdale TW, Fulkerson JP (1987) Pneumothorax complicating a closed fracture of the clavicle. A case report. *Clin Orthop Relat Res* 221: 212-214.
8. Malcolm BW, Ameli FM, Simmons EH (1979) Pneumothorax complicating a fracture of the clavicle. *Can J Surg* 22: 84.
9. Steenvoorde P, van Lieshout AP, Oskam J (2005) Conservative treatment of a closed fracture of the clavicle complicated by pneumothorax: a case report. *Acta Orthop Belg* 71: 481-483.
10. Meeks RJ, Riebel GD (1991) Isolated clavicle fracture with associated pneumothorax: A case report. *The American Journal of Emergency Medicine* 9: 555-556.
11. Williams RJ (1995) Significant pneumothorax complicating a fractured clavicle. *J Accid Emerg Med* 12: 218-219.
12. Taitsman LA, Nork SE, Coles CP, Barei DP, Agel J (2006) Open clavicle fractures and associated injuries. *J Orthop Trauma* 20: 396-399.
13. Imatani RJ (1975) Fractures of the scapula: a review of 53 fractures 1. *J Trauma* 15: 473-478.

Copyright: ©2018 Iftikhar Ahmed, et al. This is an open-access article distributed under the terms of the Creative Commons Attribution License, which permits unrestricted use, distribution, and reproduction in any medium, provided the original author and source are credited.