

Extra-osseous Ewing sarcoma of the thyroid gland mimicking a hemorrhagic cyst of Hashimoto thyroiditis

Georges El Hachem^{1*}, Christiane Jungels², Nicolas De Saint Aubain³, Ahmad Awada² and Thierry Gil²

¹Medical oncology fellow, Institut Jules Bordet, Université Libre de Bruxelles (ULB).

²Department of Medical Oncology, Institut Jules Bordet, Université Libre de Bruxelles (ULB).

³Department of Pathology, Institut Jules Bordet, Université Libre de Bruxelles (ULB).

*Corresponding author

Georges El Hachem, Medical oncology fellow, Institut Jules Bordet, Université Libre de Bruxelles (ULB). Belgium E-mail: Georges.ElHachem@bordet.be

Submitted: 25 May 2017; Accepted: 04 June 2017; Published: 27 June 2017

Abstract

Ewing's family of tumors, including Ewing sarcoma, Askin tumor, and peripheral primitive neuroectodermal tumors, were first identified by James Ewing in 1921. Ewing sarcoma is more common in bones. However, extra-osseous Ewing sarcoma (EoES) is a very rare separate entity and was first described by Tefft and al. in 1969. It is a highly malignant round-cell tumor and contains a reciprocal translocation between chromosomes 11 and 22, $t(11;22)$.

In this report, we present the case of a 34 years old female patient who was unfortunately diagnosed with Ewing sarcoma of the thyroid after being operated for a hemorrhagic cyst in a context of Hashimoto thyroiditis. The patient was followed at the endocrinology department for an auto-immune thyroiditis for two years. She complained of neck pain and a suspicious hemorrhagic cyst was discovered on thyroid ultrasound. She underwent total thyroidectomy; three weeks later, she suffered from right sided firm swelling in her neck. The pathology was in favor of EoES of the thyroid.

To date and to the best of our knowledge, this is the first case of Ewing sarcoma of the thyroid in auto-immune thyroiditis. EoES of the thyroid is a very rare entity and should be considered in the differential diagnosis of a solid tumor in the thyroid. Diagnosis is based on ultrastructural examination, immunostaining and evidence of abnormal translocation $t(11;22)$. It is usually an aggressive disease. Early diagnosis with adequate surgical management and chemotherapy are the mainstay of the treatment and may change the outcome.

Clinical practice points

Extra-osseous Ewing sarcoma of the thyroid is a very rare entity that should be considered in the differential diagnosis of a solid tumor in the thyroid.

Diagnosis is based on immunostaining, ultrastructural examination and evidence of abnormal translocation $t(11;22)$.

It is usually an aggressive disease, thus early diagnosis with adequate surgical management and chemotherapy are the hallmarks of the treatment.

Introduction

Ewing's family of tumors, including Ewing sarcoma, Askin tumor, and peripheral primitive neuro-ectodermal tumors (pPNET), were first identified by James Ewing in 1921. Ewing sarcoma is more common in bones. However, extra-osseous Ewing sarcoma (EoES) is a rare separate entity and was first described by Tefft et al. in 1969. It is a highly malignant round-cell tumor and contains a reciprocal

translocation between chromosomes 11 and 22: $t(11;22)$ [1-3].

Case report

Our patient is a 33 years old woman, diagnosed with Hashimoto thyroiditis in April 2014. She had a normal thyroid ultrasound upon initial evaluation and was started on L-Thyroxine. She was followed in the endocrinology department for her auto-immune thyroiditis with serial laboratory and clinical evaluations every three months.

In December 2015, she noticed a neck swelling; a thyroid ultrasound confirmed a homogeneous increase in size of the thyroid, with no evidence of nodular lesion nor associated lymphadenopathies. She was euthyroid and continued her regular three months follow up. In June 2016, she suffered from neck pain, and the thyroid ultrasound revealed a 4.2 x 2.9 x 2.7 cm hypo-echogenic, hypo-vascularized macro-nodule in the right thyroid lobe with a suspicious hemorrhagic component without evidence of lymph-nodes. No significant abnormalities in the left lobe. Thyroid scintigraphy showed a cold macro-nodule of the right

thyroid lobe. The patient declined the fine needle aspirate and decided to postpone the surgical treatment. However, she came back by the end of August 2016, with severe right sided neck pain. The repeated thyroid ultrasound showed the known right thyroid macro-nodule that had become heterogeneous, hyper-echoic, with few hypo-echoic and hyper-vascularized areas. However, its size remained stable, and there were no cervical nor supraclavicular lymph-nodes. After reviewing the different ultrasounds, and the fact that the nodule was mainly hypo-vascularized, the diagnosis was in favor of intra-nodular hemorrhagic cystic lesion.

She underwent a total thyroidectomy in September 2016: the per-operative pathology of the right thyroid nodule was in favor of follicular thyroiditis with numerous areas of necrosis suspicious of neoplastic process (carcinoma versus lymphoma). Three weeks later, she suffered from a right sided firm swelling in her neck. The final pathology report revealed a 5.5 cm, malignant round cell tumor with morphology and immunohistochemistry in favor of Ewing sarcoma on a background of Hashimoto thyroiditis (CD99 diffusely positive, desmine and CLA negative). The margins were negative. The EWSR1 gene rearrangement was positive. An FDG PET-CT scan was performed and showed hypermetabolic uptake at the surgical site and right cervical area with absence of metastatic or systemic lesions.

Thus, she was diagnosed with locally advanced, non metastatic EoES of thyroid, and was put on chemotherapy (Vincristine, Ifosfamide, Doxorubicin, Etoposide) for six cycles that will be followed by surgical exploration and definitive radical treatment.

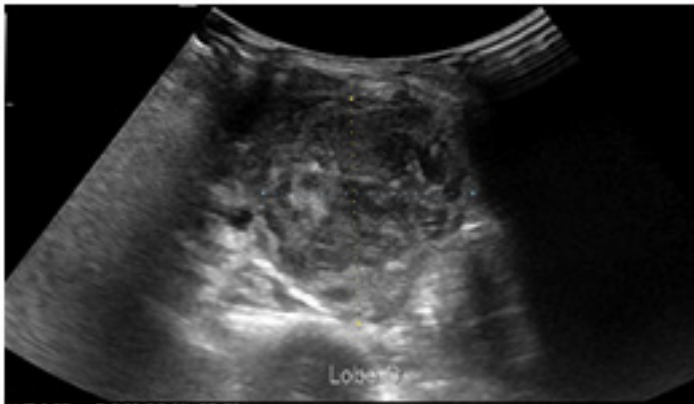


Figure 1: Heterogeneous, hyper-echoic macro-nodule of 4.2x 2.7 x 2.9 cm in the right thyroid lobe.

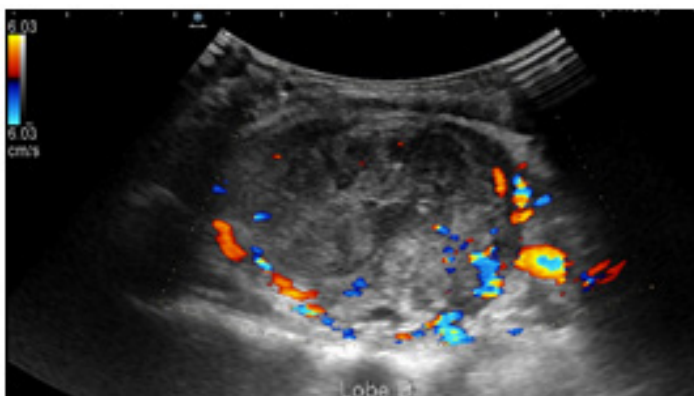


Figure 2: Macro-nodule in right thyroid lobe with areas of hyper-vascularization and hypo-echogenicity.

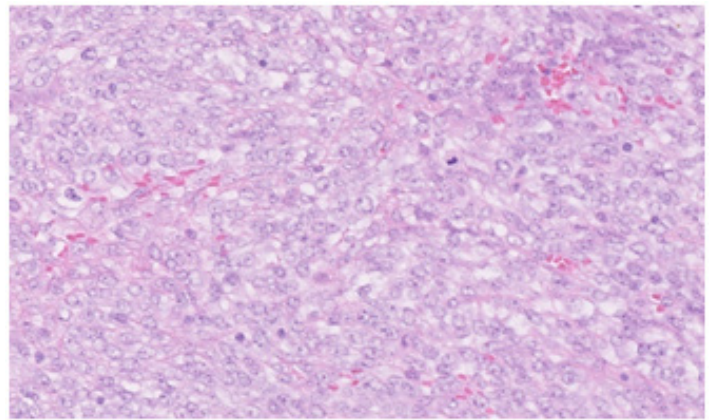


Figure 3: Hematoxylin and eosin staining (40x): clusters of round cells, with little abundant, clear cytoplasm, regular ovoid nuclei and frequent mitoses.

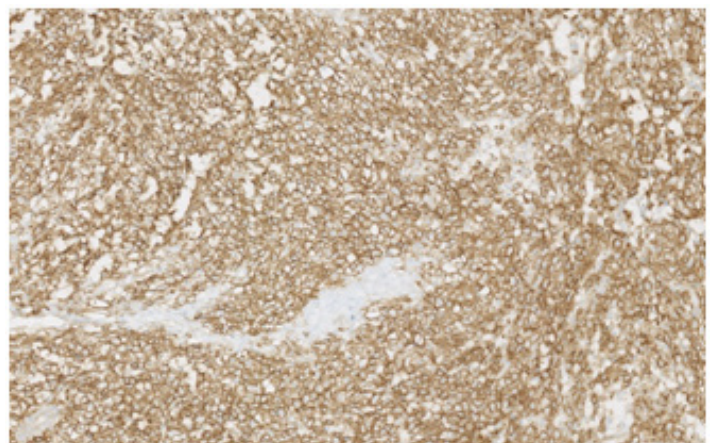


Figure 4: CD99 immunohistochemistry, showing intense and diffuse membranous immunostaining

Discussion

Extra-osseous Ewing sarcoma along with Ewing sarcoma of bone, peripheral primitive neuroectodermal tumor (pPNET), peripheral neuroepithelioma and Askin tumor, belong to the Ewing family of tumors [1]. All these tumors have common genetic translocations involving chromosome 22. Ewing sarcoma is more common in bone, while pPNET is more common in soft tissues. Immunohistochemical and cytogenetic studies suggest that these tumors all have a common origin [1].

Extra-osseous Ewing sarcoma (EoES) is rare. The paravertebral region and the lower extremity are the most frequent sites of involvement [2,3]. Other common Extra-osseous locations include the chest wall and the retroperitoneal area. EoES/pPNET is rare in the head and neck region.

EoES/pPNET poses a diagnostic challenge. Neuroendocrine tumors (NET) of the thyroid encompass a wide differential diagnosis: medullary thyroid carcinoma (being the most common NET of thyroid and 4% of all thyroid malignancies), calcitonine negative medullary thyroid carcinoma, thyroid paragangliomas, and metastasis from neuroendocrine lesion elsewhere in the body (most frequently from carcinoid tumors of the lung or gastrointestinal tract) [4-6].

On thyroid ultrasound, EoES of the thyroid appears as a nonspecific, well circumscribed, hypo-echoic soft tissue mass without tissue calcifications. CT scan is helpful in tumor staging, in identifying hemorrhage, necrosis, cyst formation or calcifications within the tumor, and evaluating response to chemotherapy [7]. MRI helps in delineating the extent of the soft tissue lesion and defining its relationship to the adjacent trachea, esophagus and neurovascular structures [8].

Anatomo-pathological findings remain the cornerstone of the diagnosis, and immunohistochemistry is paramount. EoES is histologically indistinguishable from primary Ewing tumor of bone. Some of these tumors are composed of small, uniform cells with minimal morphologic evidence of differentiation, while others feature larger, less uniform cells with various degrees of neuroectodermal differentiation [9]. In view of the lack of characteristic morphologic features, EoES/pPNET is difficult to distinguish from histologically similar small round-cell tumors, which include rhabdomyosarcoma, desmoplastic small round-cell tumor, poorly differentiated synovial sarcoma, mesenchymal chondrosarcoma, neuroblastoma, and lymphoma [10].

CD99 is a glycoprotein expressed in nearly all the Ewing sarcoma family of tumors, and thus it is a useful positive marker when it is included in an immunostaining panel to make the differential diagnosis. It is not specific for Ewing sarcoma, as it can be expressed by other small round-cell tumors, such as non-Hodgkin lymphoma, rhabdomyosarcoma, and synovial sarcoma [10]. CD99 positivity in the absence of calcitonin and CEA (medullary thyroid carcinoma markers) is highly suspicious for Ewing sarcoma/PNET.

Detection of a translocation between the EWS gene on chromosome 22 and a transcription factor is considered a diagnostic confirmation for Ewing sarcoma/PNET. The t(11;22) is the most common translocation detected via reverse transcriptase-polymerase chain reaction testing and fluorescence in situ hybridization in formalin-fixed, paraffin-embedded tissues [11].

Before treatment of this rare malignancy, it is mandatory to confirm the diagnosis of Ewing sarcoma/PNET, which is different from other type of thyroid NET, making sure that the thyroid is the site of the primary lesion and not a metastatic focus. This is an essential requirement as the standard treatment for extraskelatal Ewing sarcoma is addressing the primary site (preferably with surgical resection) and multiagent chemotherapy [12]. In a comprehensive review of chemotherapeutic regimens in the treatment of the Ewing family of tumors and pPNET, Carvajal and Meyers recommended a regimen that includes Vincristine, Doxorubicin, and Cyclophosphamide plus Ifosfamide and Etoposide [13].

EoES usually follows an aggressive course with a high rate of both local recurrence and distant metastases. Although the prognosis for this tumor is poor, an early and adequate surgical resection followed by adjunctive chemotherapy and radiotherapy for microscopically positive surgical margins improve the survival rate [3,14]. Careful preoperative planning in patients without metastatic disease for tumor free wide surgical margins has a favorable prognosis [3]. Age and surgical treatment were found to be important prognostic variables in the treatment of EoES [8].

Conclusion

To date and to the best of our knowledge, this is the first case of Ewing sarcoma of the thyroid in auto-immune thyroiditis. Although EoES/pPNET is extremely rare, it should be kept in mind in the differential diagnosis of thyroid tissue malignancies besides primary thyroid carcinoma, lymphoma, primary and metastatic neuroendocrine tumors. The biggest challenge in diagnosis is based on ultrastructural examination, immunohistochemical stains and cytogenetic studies to detect the abnormal translocation t(11;22). It is usually an aggressive disease, thus a combination of an early correct diagnosis and aggressive management with adequate surgical and cytotoxic treatment can change the outcome.

References

1. Batsakis JG, Mackay B, el-Naggar AK (1996) Ewing's sarcoma and peripheral primitive neuroectodermal tumor: an interim report. *Ann OtolRhinolLaryngol* 105: 838-843.
2. Angervall L, Enzinger FM (1975) Extraskelatal neoplasm resembling Ewing's sarcoma. *Cancer* 36: 240-251.
3. Rud NP, Reiman HM, Pritchard DJ, et al (1989) Extraosseous Ewing's sarcoma: a study of 42 cases. *Cancer* 64: 1548-1553.
4. American Thyroid Association Guidelines Task Force, Kloos RT, Eng C, et al. (2009) Medullary thyroid cancer: management guidelines of the American Thyroid Association. *Thyroid* 19: 565-612.
5. Bockhorn M, Sheu SY, Frilling A, Molmenti E, Schmid KW, et al. (2005) Paraganglioma-like medullary thyroid carcinoma: a rare entity. *Thyroid* 15: 1363-1367.
6. Ryska A, Cap J, Vaclavikova E, et al. (2009) Paraganglioma-like medullary thyroid carcinoma: fine needle aspiration cytology features with histological correlation. *Cytopathology* 20: 188-194.
7. Ulsan S, Koc Z, Canpolat E, et al (2007) Radiological findings of primary retroperitoneal Ewing sarcoma. *ActaRadiol* 48: 814-818.
8. Ahmad R, Mayol BR, Davis M, et al. (1999) Extraskelatal Ewing's sarcoma. *Cancer* 85:725-731.
9. Khoury JD (2005) Ewing sarcoma f 5. amily of tumors. *Adv Anat Pathol* 12: 212-220.
10. Llombart-Bosch A, Navarro S (2001) Immuno histo chemical detection of EWS and FLI-1 proteins in Ewing sarcoma and primitive neuroectodermal tumors: comparative analysis with CD99 (MIC-2) expression. *Appl Immuno histo chem. Mol Morphol* 9: 255-260.
11. Delattre O, Zucman J, Melot T, et al. (1994) The Ewing family of tumors - a subgroup of small-round-cell tumors defined by specific chimeric transcripts. *N Engl J Med* 331: 294-299.
12. Ahmad R, Mayol BR, Davis M, Rougraff BT (1999) Extraskelatal Ewing's sarcoma. *Cancer* 85: 725-731.
13. Carvajal R, Meyers P (2005) Ewing's sarcoma and primitive neuroectodermal family of tumors. *Hematol Oncol Clin North Am* 19: 501-525.
14. Raney RB, Asmar L, Newton WA Jr, et al. (1997) Ewing's sarcoma of soft tissues in childhood: a report from the intergroup Rhabdomyosarcoma Study, 1972 to 1991. *J Clin Oncol* 15: 574-582.

Copyright: ©2017 Georges El Hachem, et al. This is an open-access article distributed under the terms of the Creative Commons Attribution License, which permits unwnrestricted use, distribution, and reproduction in any medium, provided the original author and source are credited.