

Experimental Pulpitis Treated By Double-Pinhole Drainage

Xiao-Quan Mao

Department of Implantology, Stomatology Center, Central South University Xiangya School of Medicine Affiliated Haikou Hospital, China

*Corresponding author

Xiao-Quan Mao, Department of Implantology, Stomatology Center, Central South University Xiangya School of Medicine Affiliated Haikou Hospital, 43 Renmin avenue, Haikou 570208, China, E-mail: horse.m@163.com

Submitted: 19 July 2019; Accepted: 25 July 2019; Published: 31 July 2019

Abstract

Objective: To search for a dental pulp preservative method in experimental pulpitis.

Methods: 20 rabbits with experimental pulpitis were selected for this study; Teeth were randomly assigned to 2 groups (experimental and control groups) based on the final irrigation methods. In experimental group (double-pinhole drainage), the two pinholes were drilled in middle 1/3 dental cervix of buccal labial surface of tooth; the pinholes were inserted into infant transfusion needles then the two syringes were contacted with them, one for suck, another for irrigation. In control group, pinhole was sealed. Rabbits were executed in 1, 3, 5, 7 day. The inflammation in pulp chamber was assessed after 1, 3, 5, and 7 days.

Results: At the 1, 5 day time intervals, control group reported more inflammation than experimental group ($P < .05$). There was no significant difference between two groups at the other time intervals ($P > .05$), and in all groups the inflammation decreased over time.

Conclusion: Dental pulp can be preserved by double-pinhole drainage efficiently.

Keywords: Pulpitis, Dental pulp, Preservation, Animal experiment

Introduction

The pulp is mainly connected to the outside of the tooth through the narrow apical foramen and the lack of effective collateral circulation and the absence of concessional environment [1]. It is not easy to establish suitable drainage when the pulp is inflamed. The exudation accumulated. As a result of poor drainage, the pressure of pulp chamber increases, intense pain was produced. Once the pulp chamber was penetrated, exudates can be drained, the pressure of pulp chamber rapidly decreased, pain relieved immediately. This is anatomical basis in the treatment of acute pulpitis [2]. If we can effectively establish drainage channel in pulp chamber: the pressure will reduce, the pain alleviates; the inflammation secretion drained out of the tooth.

Materials and Methods

- Establish animal models of pulpitis.
- 20 rabbits, male or female, 1.7-2.2 kg (provided by Dongchuang Laboratory Animal Science and Technology Service Department, Kaifu District, Changsha City). Mandibular anterior teeth were drilled and penetrated the pulp chamber.
- Streptococcus mutants fluid with a concentration of 9×10^8 cfu/ml was introduced into the pulp chamber. A pulpitis model can be established at 3 D in general.
- Experimental grouping.

- Teeth of 20 rabbits with successful pulpitis models were divided into experimental and control groups. They were drilled in the neck of the teeth, experimental group was for irrigation and drainage, the control group was covered with iodoform paste, glass ion filling.
- The rabbits were fixed on the rabbit platform, the labial and lingual surfaces of the teeth were disinfected by 75% alcohol. The infant transfusion needles were connected to the hole of tooth, the 2 syringes were connected to infant transfusion needles, one for suction, the other for irrigation; repeated it once a day in the experimental groups for three days.
- The rabbits were fixed on the rabbit platform, the labial and lingual surfaces of the mandibular teeth were disinfected by 75% alcohol, the holes were cleared, and glass ionomer was filled in the control group.

Specimen Collection

5 rabbits were sacrificed at 1, 3, 5, and 7 days after treatment respectively, and teeth were immediately fixed with 10% formalin. Pulp tissue was stained with HE and the inflammation was observed with microscope (See Figure 1-9).

Statistical Processing

The chi test (exact probability method) was performed with SPSS for Windows 13.0 statistical software package, and there was statistically significant ($P < 0.05$).

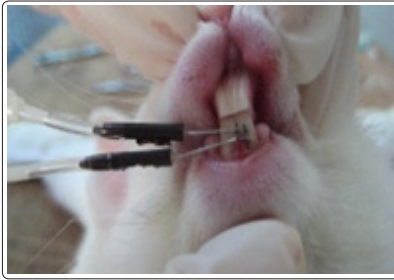

Figure 1: Double-pinhole drainage

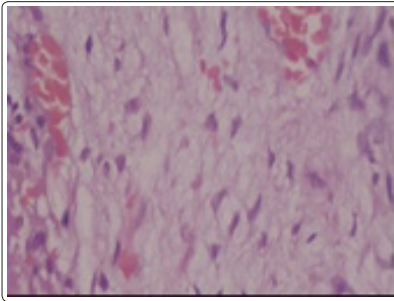


Figure 2: First day control

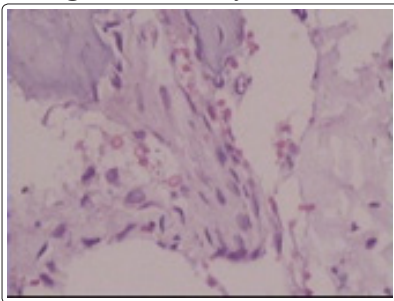


Figure 3: First day experiment

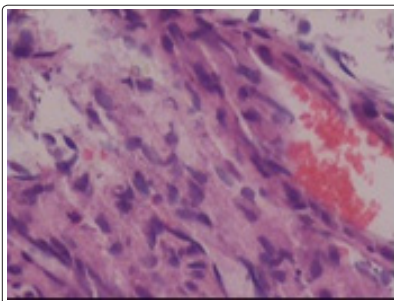


Figure 4: Third day control

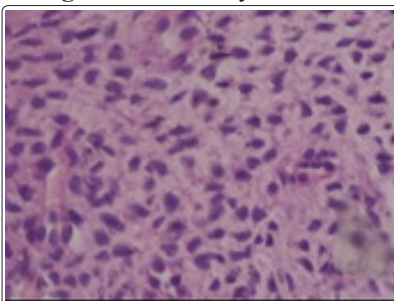


Figure 5: Third day experiment

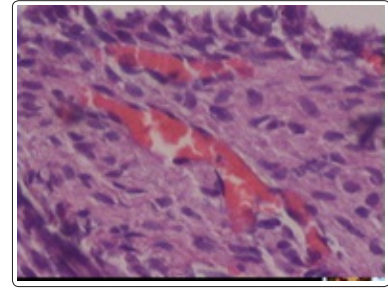


Figure 6: Fifth day control

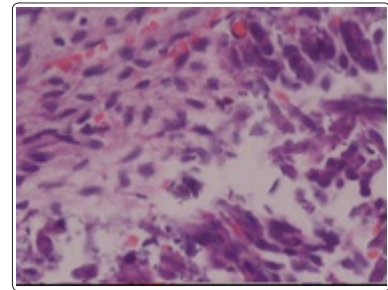


Figure 7: Fifth day experiment

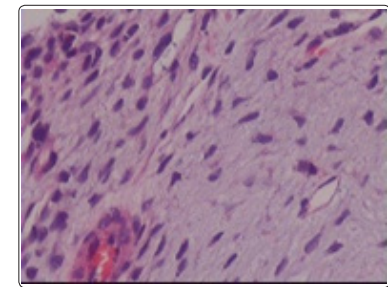


Figure 8: Seventh day control

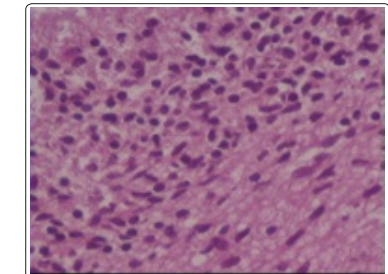


Figure 9: Seventh day experiment

Results

4 inflammations, 1 healing out of 5 cases in experimental group, 5 inflammations, 0 healing out of 5 cases in control group in first postoperative day (Figure 2 and 3); 0 inflammation, 5 healings out of 5 cases in experimental group, 3 inflammations, 2 healings out of 5 cases in control group in third postoperative day (Figure 4 and 5); 0 inflammation, 5 healings out of 5 cases in experimental group, 1 inflammation, 4 healings out of 5 cases in control group in fifth postoperative day (Figure 6 and 7); 0 inflammation, 5 healings out of 5 cases in experimental group, 0 inflammation, 5 healings out of 5 cases in control group in seventh postoperative day (Figure 8 and 9).

Table 1

	Experimental group				Control group			
	1	3	5	7	1	3	5	7
Inflammation	4	0	0	0	5	3	1	0
Healing	1	5	5	5	0	2	4	5
P<0.05 at 1,5-day								

Discussions

Acute pulpitis is prone to necrosis because the pulp is in a closed pulp chamber, lack of effective collateral circulation [1]. In clinic, pulp drying therapy, plasticization therapy and root canal therapy are effective methods to treat pulpitis, but both root canal therapy and other pulp therapy are at the cost of sacrificing part or whole of the pulps [2,3].

Previous studies have shown that pulp tissue has strong self-defense ability and self-repair potential [4]. From the results of this experiment, we can know that one of the 5 cases in the experimental group was mild congestion, accounting for 20%; the 5 cases were still severe congestion in the control group on the first day after operation. 5 cases of experimental pulpitis in the experimental group were all controlled on the third day after operation, accounting for 100%. The reason may be that cervical drilling and pulp chamber drainage are beneficial to injecting antibiotics into the pulp chamber, and timely drainage of inflammatory secretions [5,6]. Necrotized pulp tissue is cleared promptly due to irrigation and drainage, the pulp chamber environment is improved, the pulp tissue self-defense ability is enhanced [7]. Inflammatory secretions produced by bacteria are continuously discharged due to drainage, eliminating the stimulation of secretions to dental pulp; the irrigation and drainage was helpful to relieve the pressure, reduce the vasodilation and remove the necrotic tissue mechanically in the pulp chamber; a variety of cytokines were secrete from wounds, stimulating fibroblasts and endothelial cells proliferation, differentiation and growth, promoting granulation tissue formation, providing a material basis for the success of pulp preservation [8].

Acknowledgements

I would like to thank Professor Dr. Tim who modified the manuscript, Zhi-Ping Zheng who edited its grammar.

Competing Interests

The author declares that he has no competing interests.

Funding

It supported by Hainan Natural Science Foundation 807091.

Availability of Data and Materials

Data sharing is applicable to this article, datasets were generated or analyzed during the current study.

References

1. Cushley S, Duncan HF, Lappin M, Tomson PL, Lundy FT, et al. (2019) Pulpotomy for mature carious teeth with symptoms of irreversible pulpitis: A systematic review. *J Dent S0300-5712*: 30129-0.
2. Wolters WJ, Duncan HF, Tomson PL, Karim IE, McKenna G, et al. (2017) Minimally invasive endodontics: a new diagnostic system for assessing pulpitis and subsequent treatment needs. *Int Endod J 50*: 825-829.

3. AlRahabi MK (2017) Evaluation of complications of root canal treatment performed by undergraduate dental students. *Libyan J Med 12*: 1345582.
4. Zheng J, Wu Z, Niu K, Xie Y, Hu X, et al. (2019) Microbiome of Deep Dentinal Caries from Reversible Pulpitis to Irreversible Pulpitis. *J Endod 45*: 302-309.
5. Dagher J, El Feghali R, Parker S, Benedicenti S, Zogheib C (2019) Postoperative Quality of Life Following Conventional Endodontic Intracanal Irrigation Compared with Laser-Activated Irrigation: A Randomized Clinical Study. *Photobiomodul Photomed Laser Surg 37*: 248-253.
6. Shi X, Li Z, He Y, Jiang Q, Yang X (2017) Effect of different dental burs for experimental induction of pulpitis in mice. *Arch Oral Biol 83*: 252-257.
7. Liu J, Shi CS (2017) Comparative study of pain releasing effect of two approaches to acute pulpitis in the night emergency. *Shanghai Kou Qiang Yi Xue 26*: 669-671.
8. Kim S, Lee S, Jung HS, Kim SY, Kim E (2019) Development of a mouse model for pulp-dentin complex regeneration research: a preliminary study. *Restor Dent Endod 44*: e20.

Copyright: ©2019 Xiao-Quan Mao. This is an open-access article distributed under the terms of the Creative Commons Attribution License, which permits unrestricted use, distribution, and reproduction in any medium, provided the original author and source are credited.