

Epidemiological Study on Ocular Trauma and Associated Co-Morbidity at Tertiary Health Care Hospital

SK Prabhakar^{1*}, S Maheshwari², Soumya HV³, Anita T Girish⁴ and keerthi kumar⁵

¹Professor and Head of Ophthalmology Department, India

²Vitreo Retina Fellow, Aravind Eye hospital, Coimbatore, Tamil Nadu, India

^{3,4,5}JSS Medical College Hospital, Academy of Higher Education & Research (AHER), Mysore, Karnataka, India

*Corresponding author

SK Prabhakar, Professor and Head of Ophthalmology Department, JSS Hospital, Mysore - 570 004, Karnataka, India

Submitted: 01 Jun 2022; Accepted: 09 Jun 2022; Published: 21 Jun 2022

Citation: SK Prabhakar, S Maheshwari, Soumya HV, Anita T Girish and keerthi kumar (2022) Epidemiological Study on Ocular Trauma and Associated Co-Morbidity at Tertiary Health Care Hospital. *J Ophthalmol Clin Res* 6(2): 128-132.

Abstract

Aims: To classify and find out the incidence of ocular injury effects and extraocular associates.

Methods and Materials: This eight-month observational study was conducted between 2017 and 2018 recruiting 111 eyes of 101 patients reporting to ophthalmology outpatient and emergency medicine departments.

Results: The demographic profile is composed of 82 (81.18%) males and 19 (18.81%) females with a mean presenting age of 33.45 and 33.57 years in males and females respectively ranging from 3 to 82 years. Sixty four (57.65%) right and 47 (42.34%) left eyes studied. Closed globe injuries accounted for 95 (85.56%) and open globe injuries were found in 16 (14.41%) eyes. Mode of injuries classified as RTA 37 (33.33%), RTA Self fall 26 (23.42%), metal-induced trauma in 9 (8.10%) and exposure to vegetative matter in 9 (8.10%), self fall at home/work in 6 (5.40%), assault in 4 (2.6%), sports-related injuries in 3 (2.7%), bull gore injuries in 3 (2.7%) and explosion injuries in 3 (2.7%) eyes. RTA and RTA self fall showed the highest relative risk and odds ratio among males compared to females. The relative risk ratio and odds ratio for RTA in males showed 0.63 and 0.31 respectively.

Anterior segment injury effects were observed in all eyes and 21 (18.91%) eyes with posterior segment involvement. The associated facio-maxillary injury was seen in 58 (52.25%) eyes, orbital wall fractures in 52 (46.85%), and head injury in 26 (23.42%) eyes. Thirty (35.14%) eyes required imaging for further evaluation, of which 32 (31.68%) underwent computed tomography and 2 (1.99%) eyes subjected to magnetic resonance imaging. Fifty-three (52.47%) eyes were managed surgically, 25 (24.75%) conservatively and 23 (22.77%) medically.

Conclusion: This study analysis concludes that closed globe injury is the most common ocular trauma. In middle-aged male patients, RTA-induced injuries were commonly prevalent. The most frequently associated co-morbidities were facio-maxillary trauma, lateral orbital wall fractures, and subconjunctival hemorrhage. Maximum eyes required surgical management while computed tomography provided a conventional mode of imaging. The multi-departmental management approach is essential for achieving a good medical and surgical outcome.

Keywords: Closed globe injury, Head injury, Open globe injury, Orbital wall fractures, RTA (road traffic accident)

Introduction

Ocular trauma constitutes a major cause of visual morbidity worldwide producing a significant impact on socioeconomic status and financial constraints. Globally each year there are 55 million ocular injuries reported that restricted the activities for more than a day, 19 million people have at least unilateral permanent visual loss, and 1.6 million people are left with bilateral blindness [1]. Although extensive efforts and strategies have been put forward by

the health services to prevent ocular trauma in various countries, ocular injuries do occur leading to loss of human resources. In India a newly industrializing country, ocular trauma is one of the leading causes of blindness and the most common admissions in ophthalmology and emergency medicine departments. The visual outcome after ocular trauma depends on various factors including etiology, severity, and most importantly the duration from the onset of injury until management [2].

Aside from visual impairment, ocular trauma is associated with pain, psychosocial stress, and economic burden the society and patients' families in particular. From the point of preserving the community health, epidemiological information is very essential to plan effectively and educate the public on the mode and mechanism of ocular injury, the extent of ocular damage, and their post-traumatic complications. Hence this study was conducted to analyze the epidemiological aspects of ocular injuries presenting at a tertiary multispecialty hospital over eight months.

Methods and Materials

This is an observational study conducted for 8 months to investigate the epidemiological aspects of ocular injuries in patients reporting to the outpatient ophthalmology and emergency medicine department, at a tertiary health care teaching institution. A total of 111 eyes of 101 consecutive patients presenting with ocular trauma were investigated. All patients underwent according to the protocol accordingly, composing of comprehensive history-taking, mode of injury, and circumstance at the time of injury, relation to work. Based on the mode of injury, the patients were categorized into RTA, RTA self-fall, sports-related injury, injuries due to metal object, vegetative matter and explosion, bull gore injuries, self-fall at home, and assault-related injuries.

All patients were subjected to an initial visual acuity assessment; detailed anterior in addition to posterior segment evaluation. Furthermore, on the recommended basis, all the patients were investigated with a B scan, X-ray, CT scan, MRI, and optical coherence tomography. The method of intervention was based on the nature of the injury. Statistical analysis was performed on Microsoft excel and an odds ratio calculator.

Results

This observational investigation studied 111 eyes of 101 patients attending ophthalmic and emergency medicine departments. Out of 111 eyes with ocular trauma, posterior segment association was observed in 18.91%. And surprisingly the anterior segment was involved in all the cases. An illustration of the demographic profile of ocular trauma patients showed in Figure 1. The incidence of the modes of ocular injuries in males and females is depicted in Figure 2. Figure 3 shows a bar graph representing the complete analysis of ocular-related trauma illustrating the incidence.

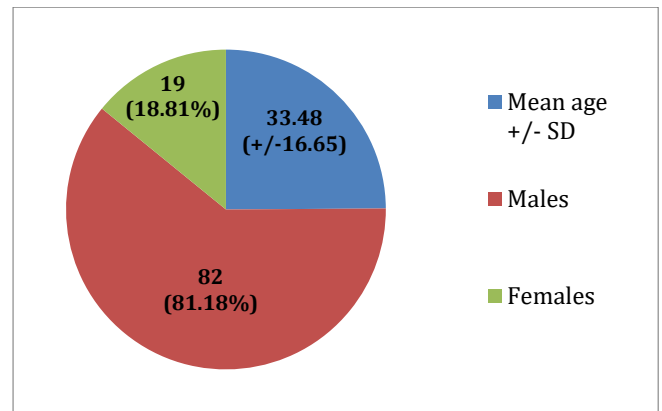


Figure 1: Showing demography profile of patients with ocular trauma

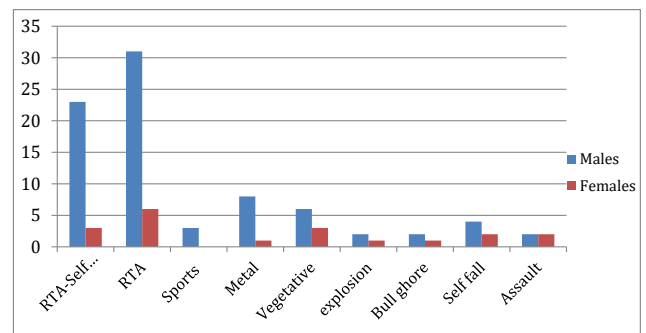


Figure 2: Showing gender classifications by mode of ocular injury

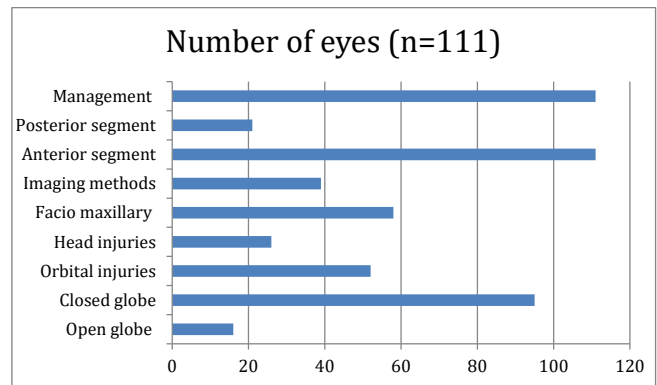


Figure 3: Showing epidemiological evaluations of ocular injuries

In 52 (46.85%) cases, orbital fractures were observed in addition to head injury in 26 (23.42%) cases, and facio-maxillary trauma in 58 (52.25%) cases. Maxillary sinus fractures contributed to the bulk of facio-maxillary trauma (19.80%) with lateral orbital wall fractures as the most common (7.82 %) comorbidity. Moreover, imaging modalities for further evaluation were required in 35.14 % of eyes. Figure 4 represents the associated co-morbid extra ocular injuries, out of 23.42% of cases with head injuries; subarachnoid hemorrhage was diagnosed in 9.90%. Comparative gender analysis of relative risk and odds ratio based on various modes of injuries are depicted in Table 1. RTA and RTA self fall-related injuries revealed the highest relative risk and odds ratio among males compared to females.

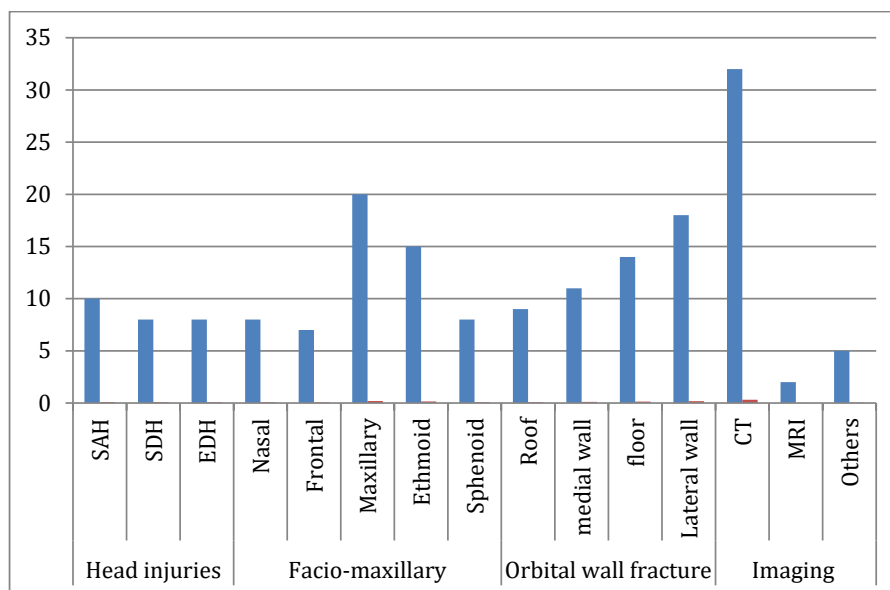


Figure 4: Showing associated co-morbid injury effects

Table 1: Shows the comparative analysis of gender at risk with the mode of injury

n=101 Mode of injury	Males		Females	
	Relative risk (RR)	Odds ratio (OR)	Relative risk	Odds ratio
RTA self fall	0.47	0.60	0.07	0.07
RTA	0.63	0.31	0.07	0.07
Sports	0.07	0.07	0	0
Metallic	0.17	0.19	0.03	0.03
Vegetative	0.07	0.07	0.07	0.07
Explosion	0.05	0.05	0.03	0.03
Bull gore	0.05	0.05	0.03	0.03
Self fall	0.09	0.09	0.05	0.05
Assault	0.05	0.05	0.03	0.3

Discussion

This observational study attempts to investigate the ocular injury effects based on the mode of impact at a tertiary health care hospital enrolling 111 eyes of 101 patients. The objectives were to classify and correlate various ocular effects of trauma with the mode of injury and nature of the impact, and to report the associated co-morbidities.

The mean age of the patients was 33.48 (+/-16.65) years. The mean age among males was 33.45 years and for females were 33.57 years. A study conducted by Wang W et al showed the average age of the patients with a history of ocular trauma was 37.0 (+/-19.3) years, ranging from 1 to 87 years old, with an average age of 37.4 years in males and 35.2 years in females, similar to the present study results [3]. This shows that ocular trauma is prevalent in the more reproductive age group.

The demographic profile consists of 82 (81.18%) males and 19 (18.81%) females. Male gender preponderance was observed

similar to a previous study that reported a male to a female ratio of 34.2% vs. 9.9% respectively. A higher male preponderance is thought to be related to occupational hazards at the workplace/at home, competing in dangerous sports and hobbies, alcohol consumption, and risk-chasing behavior [4].

A previous prospective study reported childhood injuries in 25%, work-related injuries in 44%, and sports injuries in 5%, in contrast to our study that revealed 5.4% for workplace injuries, and 2.4% for sports-related injuries with a higher incidence of RTA (33.33%) and RTA Self fall (23.42%) injuries [5]. Children represented 11.88% of the injuries in the present study implying the need for the prevention of childhood domiciliary and sports-related trauma.

Out of 111 eyes, most of the ocular injury effects were observed in 64 (57.65%) right eyes and 47 (42.34%) left eyes similar to a study that reported an increased risk of involvement for right eyes than left eyes possibly attributed to right-handed dominance in the

majority of the population [6]. Closed globe injuries were seen in 95 (85.56%) and open globe injuries in 16 (14.41%) eyes respectively similar to the results of another investigation that involved 71 (33.8%) eyes with open injuries and 155 (53.5%) eyes with closed injuries [7].

Accordingly, the mode of injuries was classified into RTA 37 (33.33%), RTA Self fall 26 (23.42%), metal-induced and exposure to vegetative matter 9 (8.10%), self fall at home/workplace 6 (5.40%), assault-related trauma in 4 (2.6%), sports-related injuries in 3 (2.7%), bull gore injuries in 3 (2.7%) and explosion in 3 (2.7%). A road traffic accident was the most common cause of ocular injuries (56.75%) in the present study similar to Smith AR et al report [7]. On the contrary, another study on open globe injuries revealed work-related accidents to be the most common cause of open globe injuries [8]. Ocular injuries due to sports were not seen among females and there was equal gender incidence (1.98%) of assault-related ocular trauma.

Our study showed a higher relative risk and odds ratio for males compared to females. The incidence rate of RTA-induced ocular

injuries calculated was 3.1% per 1000 populations and 2.3% per 1000 populations for RTA self-fall related injuries. RTA self fall-related injuries showed 0.40 and 0.67, and RTA related injuries showed 0.63 and 0.31 as the highest relative risk and odds ratio among males respectively. According to a study conducted by Wong TY, et al. younger age and male, preponderance had a higher odds ratio of 2.57(95% CI 2.0 to 3.29, p 0.001) and 4.42(95% CI 3.79 to 5.16, p 0.001) respectively [9]. Ocular injuries due to sports were not seen among females and there was an equal incidence of assault cases among both males and females (1.98%).

Anterior segment structures and lids involvement were frequently associated with ecchymosis and laceration. Posterior segment involvement was found in 21 (18.91%) cases. (Table 2) A retrospective study on epidemiological characteristics in Mediterranean geographical location reported contusion of the anterior segment to be the most common closed globe injury among patients hospitalized for ocular trauma [10]. In a retrospective study conducted on 380 eyes at a tertiary eye care center in Jharkhand (India) reported that most often cornea bears the brunt (56.6%) in ocular trauma [11].

Table 2: Showing effects of trauma on various ocular structures

OCULAR AND ADNEXAL STRUCTURES	EFFECTS OF TRAUMA
ORBITS	Orbital wall fractures
EYELIDS	Lacerations Periorbital edema Ecchymosis Ptosis
EXTRAOCULAR MUSCLES	Impingement
SCLERA	Tears
CONJUNCTIVA	Chemosis Tears Subconjunctival hemorrhage
CORNEA	Lacerations Edema Foreign bodies
ANTERIOR CHAMBER	Hyphema Reaction Hypopyon
IRIS	Traumatic uveitis Iridodialysis
PUPIL	Sphincter tears RAPD Anisocoria
LENS	Traumatic cataract Lens subluxation
VITREOUS	Vitreous hemorrhage
RETINA AND CHORIOD	Commotion retinae Berlins edema Traumatic optic neuritis Sub retinal hemorrhage Choroidal rupture

Computed tomography (CT) of the head and orbit was the recommended imaging modality to evaluate various ocular and adnexal injuries, while MRI was reserved wherever essential. Facio-maxillary trauma (52.2%) was the most common co-morbidity associated with ocular injuries. Among the orbital wall fractures, lateral orbital fractures were frequently observed. Previous revealed that 47% of cases were associated with ocular adnexal injuries and orbital wall fractures [7]. In our study more than 50% of patients had associated injuries to surrounding structures. Therefore it is essential to seek multi-departmental advice as teamwork to achieve the best outcome of the treatment.

Conclusion

This observational study investigated the burden of ocular trauma in society. This study revealed middle-aged males are at increased risk for ocular trauma as the RTA is the most common mode of injury and closed globe injuries are the most common ocular trauma. The ocular injury was largely associated with lateral orbital wall fractures, subconjunctival hemorrhage, and maxillary sinus involvement. CT was the most common imaging modality adopted and a majority of the patients were treated surgically.

References

1. Négrel AD, Thylefors B (1998) The global impact of eye injuries. *Ophthalmic Epidemiol* 5: 143-169.
2. MacEwen CJ, Baines PS, Desai P (1999) Eye injuries in children: the current picture. *Br J Ophthalmol* 83: 933-936.
3. Wang W, Zhou Y, Zeng J, Shi M, Chen B (2017) Epidemiology and clinical characteristics of patients hospitalized for ocular trauma in South-Central China. *Acta Ophthalmol* 95: e503-e510.
4. McCarty CA, Fu CL, Taylor HR (1995) Epidemiology of ocular trauma in Australia. *Ophthalmology* 106: 1847-1852. Fong LP: Eye injuries in Victoria, Australia. *Med J Aust* 162: 64-68.
5. Fong LP (1995) Eye injuries in Victoria, Australia. *Med J Aust* 162: 64-68.
6. Huang Z, Li H, Huang Y, Zhou Z (2002) Clinical study on ocular trauma in children. *Yan Ke Xue Bao* 18: 173-175.
7. Smith AR, O'Hagan SB, Gole GA (2006) Epidemiology of open- and closed-globe trauma presenting to Cairns Base Hospital, Queensland. *Clin Exp Ophthalmol* 34: 252-259.
8. Li EY, Chan TC, Liu AT, Yuen HK (2017) Epidemiology of Open-Globe Injuries in Hong Kong. *Asia Pac J Ophthalmol (Phila)* 6: 54-58.
9. Wong TY, Klein BE, Klein R (2000) The prevalence and 5-year incidence of ocular trauma. The beaver dam eye study. *Ophthalmology* 107: 2196-2202.
10. Cillino S, Casuccio A, Di Pace F, Pillitteri F, Cillino G (2008) A five-year retrospective study of the epidemiological characteristics and visual outcomes of patients hospitalized for ocular trauma in a Mediterranean area. *BMC Ophthalmol* 8: 6.
11. Sinha S (2008) Pattern of trauma to the anterior segment of eyes in a tertiary eye care center of Jharkhand. *J Indian Med Assoc* 106: 289-290.

Copyright: ©2022 SK Prabhakar. This is an open-access article distributed under the terms of the Creative Commons Attribution License, which permits unrestricted use, distribution, and reproduction in any medium, provided the original author and source are credited.