

## Emergency conditions in cardio surgery and obstetrics (Case Report)

Medakovic Snezana

Specialist Scrub Nurse, Institute for Cardiovascular Diseases  
Dedinje, Serbia

**Corresponding author**

Medakovic Snezana, Specialist Scrub Nurse, Institute for Cardiovascular Diseases Dedinje, Serbia, Tel: +381642011080, E-mail: smedakovic@yahoo.com

Submitted: 13 Aug 2018; Accepted: 20 Aug 2018; Published: 27 Aug 2018

Medical science evolves and progresses every day, and medical workers must be educated to lead every new step, because it is of life-importance for our patients and users.

Surgery is a branch of medicine and, the primary role is to help and to reconstruct the diseased parts. Cardiovascular surgical every day, every month records new procedures or techniques in the treatment of these diseases. The goal of these surgical procedures is helping the patient, reduce costs, reduce their stay in intensive care and allow the patient to continue a normal, successful life.

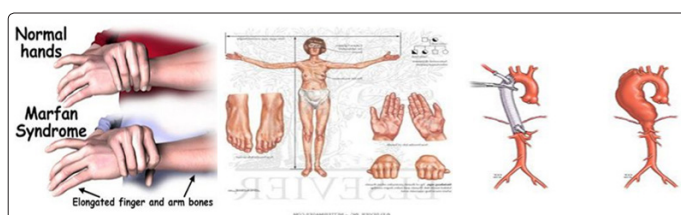
Surgery relies on medical science to establish reconstructive imitations of the function of organs that are not artificial. Reconstructive imitation of the function is achieved by using tissues and parts of organs and prosthetic material. The possibility of reconstruction also implies the application of the prosthesis as an imitation of the part of the organs and has a functional role.

I will speak about extremely rare cases in cardiovascular surgery which are, acute aortic dissections and obstetrics.

Spontaneous dissection of the ascending aorta in pregnancy is extremely rare, and it presents an urgent condition because both mother and child are endangered.

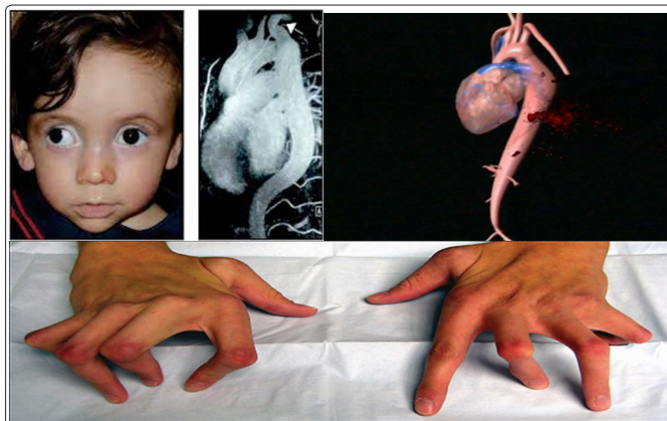
During 2015 and 2016, two pregnant women were admitted to the Institute of Cardiovascular Diseases “Dedinje”, Belgrade, Serbia in the last gestation weeks. Before, I must say that these conditions are very serious for both sexes, but especially for pregnant women, also cases that are described and recorded very often have an unwanted outcome by mother or newborn.

I will explain this case and explain the causes of acute dissection of the aorta. In the first please, the cause of this disease genetic. The most common and most famous is Marfan syndrome, which is an illness of the connective tissue, and people have a characteristic look: People with Marfan tend to be tall, and thin, with long arms, legs, fingers, and toes. They also typically have flexible, joints and scoliosis.



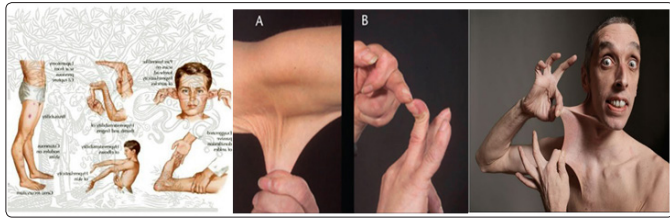
sl.1: Characteristics of Marfan syndrome and surgical solution

The next is Loeys-Dietz syndrom- is an autosomal dominant genetic connective tissue disorder, with underlying vasculopathy, characterized by aortic and other vascular aneurysmal dissection-rupture. People with this syndrome have abnormally long limbs and fingers, and dural ectasia and widely spaced eyes, bifid or split uvula, and skin findings such as easy bruising or abnormal scars.



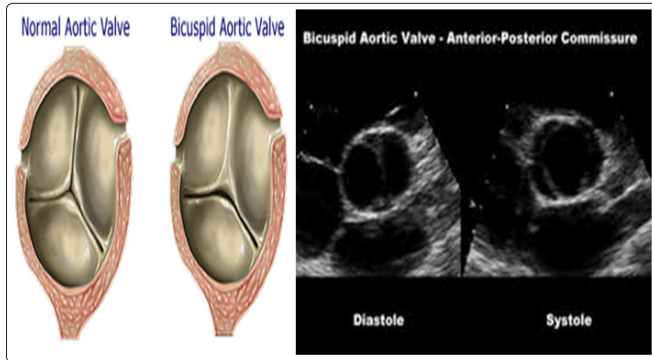
sl.2: Characteristics of Loeys-Dietz syndrome

When we talk about the most famous genetic diseases we should mention Ehlers Danlos syndrome as in the 19th century, there were several sideshow performers billed as The Elastic Skin Man, The India Rubber Man and Frog Boy, the reasons for this is because people with this disease have overly flexible joints, stretchy skin, abnormal scar formation and complication are aortic dissection, joint dislocations, scoliosis, chronic pain, or early osteoarthritis.



sl.3: Characteristics of Ehlers Danlos syndrome

One more genetic disease is Bicuspid aortic valve (normal is trilling aortic valve) and is a hereditary disease and usually patients don't have problems until later in life, but it's significant data for pregnancy.



sl.4. Characteristics of Bicuspid aortic valve and ultrasound diagnostics

A big problem with women who before pregnancy were healthy, is hypertension. If pregnant women don't control their blood pressure, it can lead to serious complications both for her health and, for the health of the child. These situations can lead to acute dissections or ruptured ascendent aortic. Of course, this traumatic condition can lead to traffic trauma.

In the hospital where I work, according to the urgent status protocol, it received a woman aged 37 years from the Valjevo area in her 35th gestation week, previously healthy woman, with three normal pregnancies.

Symptoms that indicate an emergency:

- destructive, long-lasting pain
- propagating the pain in the neck
- pain in the left lumbar posture with propagation in the left leg
- vital signs are stable

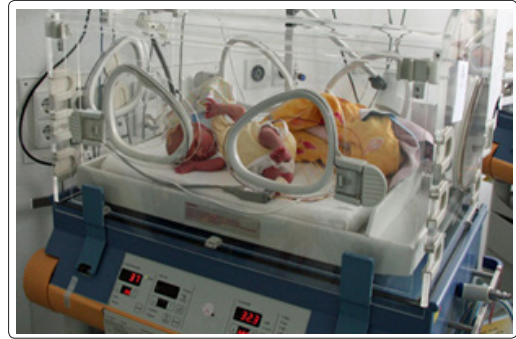The patient was taken as an emergency because she was diagnosed with acute dissection of the ascendent aorta, using ultra sound. The co-ordination of health professionals at all levels has contributed to a good, quick and effective preparation for the reception of this patient.

The multidisciplinary team consisted of:

- The gynecological-obstetrical team
- Neonatological team
- Cardiac surgery team
- Anesthesiological team

A decision was made to initiate a gynecological-obstetric surgery-section Caesar, and the girl was born 2610 gr, Apgar scores 5-6 from one to five minutes.

The nursing care of the alive newborn was taken over by the neonatological team and transported to the Institute of Neonatology.

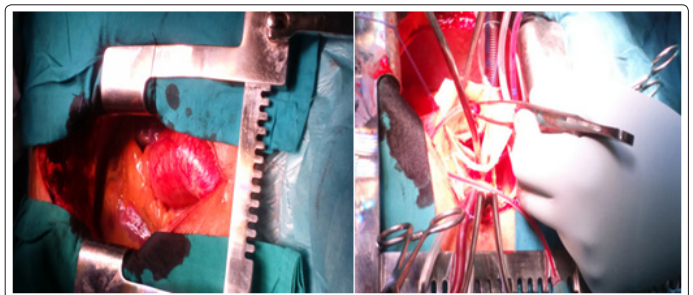


sl.5: Newborn prepared the transport in the Institute of Neonatology

Reconstructive cardiac surgery implies the application of the prosthesis as an imitation of the part of the organs, and has a functional role.

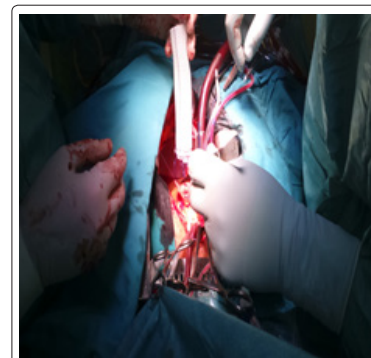Before surgery, the patient was diagnosed with transesophageal echocardiogram, that showed a normal left normal ventricular systolic function, normal wall motion, moderate to severe aortic regurgitation and a dissecting flap in the ascending aorta-aorta root.

In addition to the standard stages in the operation, it is important to say that the affected aorta opens and inspects all tissues and aortic valves, and the native aortic lumen is measured, which determines the size of the prosthetic material, and usually implants are combined prosthetic material.



sl.6: Inspects all tissues and aortic valves

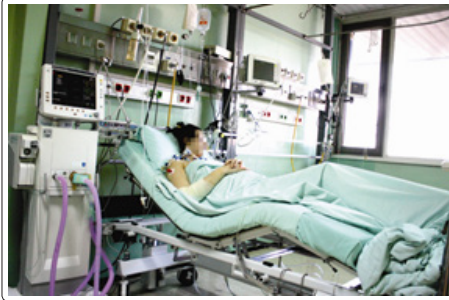The most commonly used prosthetic material is graft composite, meaning that they have the two components, mechanical valve and synthetic tubular graft, which completely replaces the native valve and aorta.



sl.7: surgery acute dissection aorta

The operation is completed by protocol using these surgical procedures. The patient is transported in a stable condition to an intensive care unit. After the post-operative recovery, the patient returned to her normal life. It should be said that these medical conditions do not always go well. The most common dilemma is whether to save a mother or a child. In both cases, at the Cardiovascular Institute, we had a positive result, saving the lives of both mothers and children.

The Institute for Cardiovascular Diseases “Dedinje”, the hospital where I work, and the Clinic for Cardio surgery, is one of the two largest centers for cardio surgery in Serbia. Every year, we perform over 2000 cardio procedures and repair ascending aorta works as a standard, for patients who need it. We believe that constant education of nurses is necessary to improve their knowledge and to enable us to provide as much care to our patients as is required.



sl.8: patient in unite intensive care

**Copyright:** ©2018 Medakovic Snezana. This is an open-access article distributed under the terms of the Creative Commons Attribution License, which permits unrestricted use, distribution, and reproduction in any medium, provided the original author and source are credited.