

Effect of Photo Activated Disinfection on Osseointegration of Immediate Implants Placed in Infected Sockets

Ahmed Nagi Alghandour^{1*}, Tarek Elsharkawy², Mohamed Elshalkamy³ and Abdelbadee Abdollah⁴

¹Master degree in Oral & Maxillofacial Surgery, Faculty of Oral and Dental Medicine, Cairo University, Egypt

²Professor of Oral & Maxillofacial Surgery, Faculty of Oral and Dental Medicine, Cairo University, Egypt

³Assistant Professor of Oral and Maxillofacial Surgery, Faculty of Dentistry, Suez Canal University, Egypt

⁴lecturer of Oral & Maxillofacial Surgery, Faculty of Dentistry, Suez Canal University, Egypt

*Corresponding author

Ahmed Nagi Alghandour, Master degree in Oral & Maxillofacial Surgery, Faculty of Oral and Dental Medicine, Cairo University, Egypt.

Submitted: 20 Sep 2017; Accepted: 17 Oct 2017; Published: 26 Oct 2017

Abstract

The technique of immediate implant placement was first described by Lazzara in 1989. This one-step surgical procedure reduces treatment time, improves esthetic out-comes, increases comfort during healing, and has proven to be a predictable strategy with a high success rate in absence of periapical lesions. The presence of active infection in the extraction site is considered one of the main contraindications to immediate implant insertion in the socket because of the increased possibility of infection spreading to peri-implant tissues during the healing period. Photodynamic therapy is based on the idea that nontoxic photosensitive agent, called photosensitizer activated by light with susceptible wavelength and produces singlet oxygen and free radicals, which are cytotoxic for the target cells. This technique has proven to reduce periapical infection and so provide more success rate for immediate implant in infected sockets.

Keywords: Dental Implant, Immediate Implant, Photodynamic Therapy, Infected Sockets, Healing, Periimplantitis, Photosensitizer, Disinfection

Introduction

Traditionally, before placing dental implants, the compromised teeth are removed and the extraction sockets are left to heal from several months up to 1 year [1].

However, alveolar ridge resorption after tooth extraction may considerably reduce the residual bone volume and affect the favorable positioning of implants which is required to produce optimal restoration [2].

Schulte and Heimke first introduced concept in 1976 to place the implant immediately into the post extraction socket without waiting for the site to heal to preserve the alveolar bone level from the collapse caused by healing and to reduce treatment time [3]. Anneroth and colleagues were the first to publish a study in an animal model (monkeys) [4]. In 1989, Lazzara first reported immediate implant placement in an extraction socket in humans [5].

The placement of implant immediately after tooth extraction with periapical lesion is still a debate and requires more studies to be

conducted [6]. However, Douglas had stated that in sockets with 3-4 intact walls, minimal periodontal resorption and good primary stability, immediate implantation is a safe procedure [7]. A report by Siegenthaler and Lindeboom suggested that the complication rates with implants placed in the infected sites compared to those of non-infected sites are almost the same [8]. Novaes Jr and Novaes AB in their study stated success by few pre and post-operative measures including antibiotic administration, meticulous cleaning and alveolar debridement [9].

The oral cavity harbors more than 700 prokaryote species most of these species are normal flora of the healthy oral cavity [10]. Some of these microorganisms are responsible for oral pathologies [10]. Bacteria such as *Actinobacillus actinomycetemcomitans*, *Pasteurella*, *Prevotella intermedia*, *Porphyromonas gingivalis*, *Treponema denticola*, and *Tannerella forsythia* are responsible for common forms of periodontitis and peri-implantitis [11].

During a surgical intervention, disinfection of the oral cavity is attempted by using different chemical solutions such as chlorhexidine, this is done to prevent, or at least reduce the risk of wound infections or bacteremia following the surgical intervention [12].

Photodynamic therapy or light-activated disinfection is a technology based on the production of free oxygen radicals capable

of affecting the membranes of microorganisms [13]. The technique is composed of a photosensitizer substance usually toluidine blue that can be activated by light with susceptible wavelength. The photosensitizer after its activation produces energy capable of transforming the surrounding oxygen into free radicals, the free radical then attacks the exposed microorganisms [13,14].

Photodynamic chemotherapy may be used in dentistry to reduce the bacterial load in cases of periodontal lesions, perimplantitis and during root canals [15,16].

Materials and Methods

This study conducted on a total of 24 immediate implants in patients who need extraction of at least two teeth that are non-restorable with periapical infection. Patient's age ranging from 20 to 50 years. They were selected and treated in the clinic of Oral and Maxillofacial surgery Department, faculty of Dentistry, Suez Canal University.

Inclusion criteria for patient selection were:

- Patients should be free of any chronic systemic disease that may contraindicate the surgery or negatively affect the healing after surgery.
- Patients should be free of any severe psychological or mental problems.
- Teeth with normal alignment in dental arch with proper inter-arch relationship.
- Teeth should have intact surrounding alveolar bone and have at least 2 mm of sound bone beyond the root apices.
- Badly decayed non-restorable with periapical infection teeth.
- Patients should have proper oral hygiene maintenance.
- Implants placed in maxilla and/or mandible bilaterally.

Exclusion criteria for patient selection were:

- Pregnant females.
- Presence of dehiscence or fenestration of the bony walls.
- Patients received irradiation therapy.
- Smokers.
- Alcohol or drug abusers.
- Teeth adjacent to each other to ensure debridement of each group alone.

Patient grouping

The previous examination and diagnostic procedures allowed selection of patients matching the criteria of case selection (each patient receive 2 or 4 immediate implants). They were randomly divided into two groups, each group received 12 implants: Group I (Control group): The socket in this group debrided using 2.5 ml of Chlorohexidine.1%. Group II (Study group): The other socket in this group disinfected by Apoza photo activated device (Lit600) which is an LED lamp emitting light in the red spectrum with a wavelength at 635 nm. A watery solution of toluidine blue O (TBO) was prepared to concentrations 10 µg/ml and stored in the dark container at 4°C until using .5 ml as photosensitizers in the experiments.

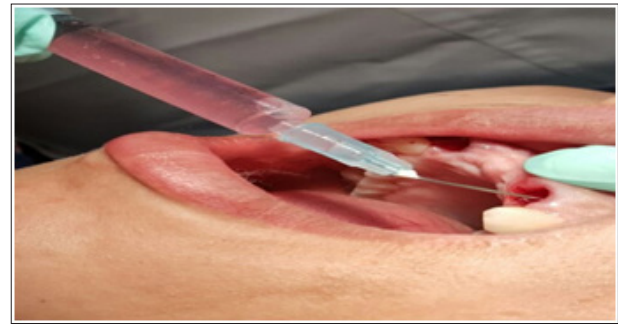


Figure 1: Debridement of left socket by chlorohexidine .1%

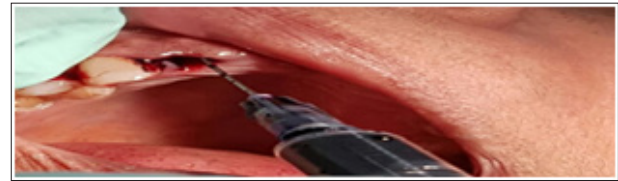


Figure 2: Application of toluidine blue in the right socket

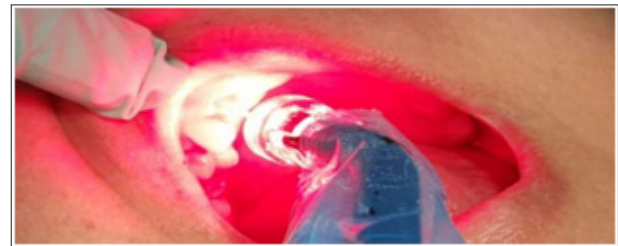

Figure 3: Photo activation disinfection of right socket

Postoperative assessment

1-Microbial assessment

The specimens are delivered to the microbiology lab within 1 hour which incubated for one day in blood agar diluted to 1:10000 which is non selective highly nutritive and indicator medium for subculture and counting which composed of nutrient broth oxide with 5% sterile blood. Four Specimens were collected two from control group after extraction and after debridement by chlorohexidine .1% , and two from study group one after extraction and one after photo activation disinfection.

2-Clinical assessment

Each patient returned for postoperative assessment after 7 days and after 6 months.

The following data of were collected:

I) Pain

Wong baker faces pain scale and the visual analogue pain scale is used to compare pain after the surgery in both implant sites. The pain scale is an easy method for pain evaluation by the patient on seventh day indicating the degree of pain the patient experienced using simple digits and simple faces expressions.

II) Edema

Horizontal and vertical facial measurements were taken; the first measurement was taken just before surgery and one measurement post operatively after 7 days.

III) Implant stability

Implant stability was measured by Osstell once during the surgery and second after 6 months.

IV) Probing depth

Probing depth is measured two times one after 7 days of surgery and one after 6 months. It was recorded on 4 surfaces; mesial, facial, distal and lingual using ASCH periodontal graduated probe inserted in the peri-implant sulcus. An individual score was obtained by calculating the average pocket score from all 4 surfaces of each implant.

3-Radiographic assessment

Evaluation of the osseointegration following implant placement was radiographically assessed through sequential indirect digital panoramic radiographs taken in predetermined time intervals immediately postoperatively and after 6 months. The radiographic parameters were fixed through all the study, all digital panoramic radiographs were taken using the same machine and the imaging technique is standardized according to the manufacturer's instruction specifications. All films were processed automatically under the same conditions, so that standardization is obtained also during film processing.

Results

A-Percentage reduction in bacterial counts

PDT group showed statistically significantly higher mean percentage reduction in bacterial counts than CHX group.

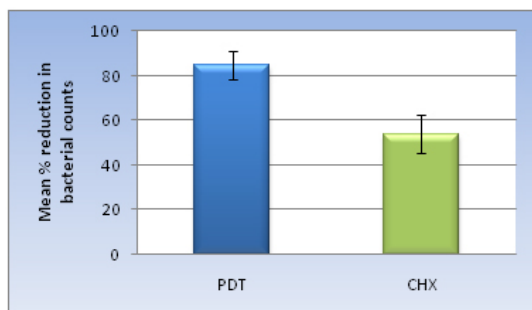


Figure 4: Bar chart representing mean and standard deviation values of percentage reduction in bacterial counts in the two groups

B-Pain

PDT group showed statistically significantly lower mean pain score than CHX group.

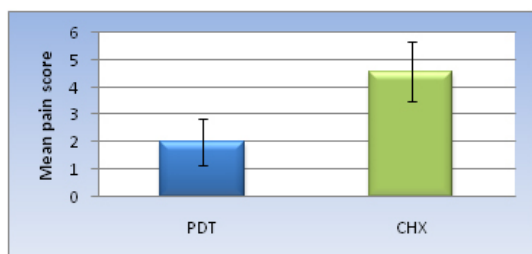


Figure 5: Bar chart representing mean and standard deviation values of pain scores in the two groups

C-Edema %

PDT group showed statistically significantly lower mean edema %

than CHX group.

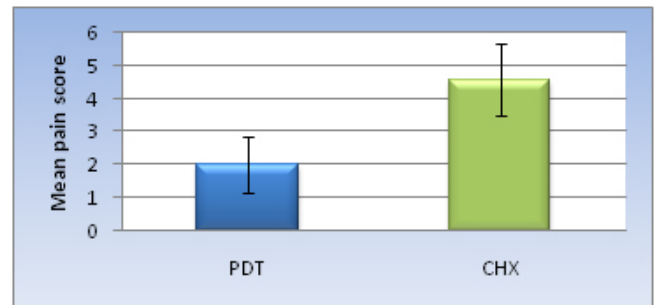


Figure 6: Bar chart representing mean and standard deviation values for edema % scores in the two groups

D-Implant stability (Osstell)

Immediately post-operative, there was no statistically significant difference between mean values in the two groups.

After 6 months; PDT showed statistically significantly higher mean value than CHX group.

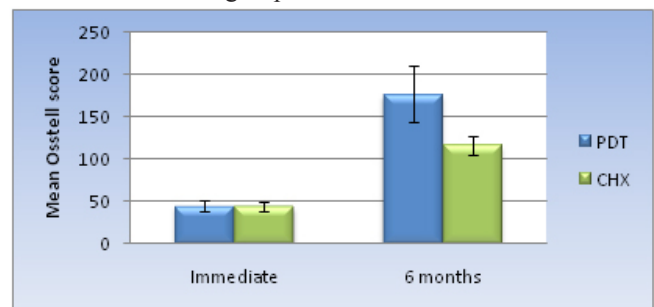


Figure 7: Bar chart representing mean and standard deviation values for Osstell values in the two groups

E-Probing Depth (PD)

Immediately post-operative as well as after 6 months, there was no statistically significant difference between mean values in the two groups.

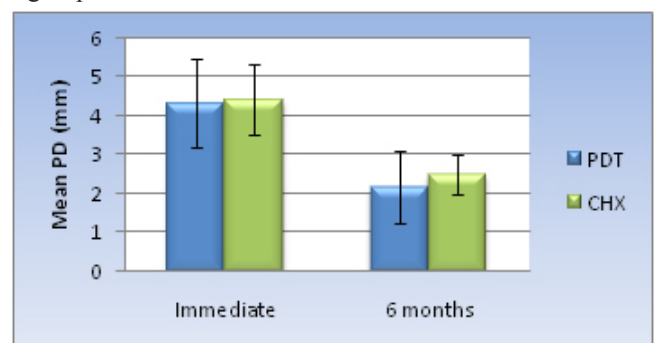


Figure 8: Bar chart representing mean and standard deviation values for PD values in the two groups

F-Bone density (Grey scale)

Immediately post-operative, there was no statistically significant difference between mean Grey scale values in the two groups.

After 6 months; PDT showed statistically significantly higher mean Grey scale value than CHX group.

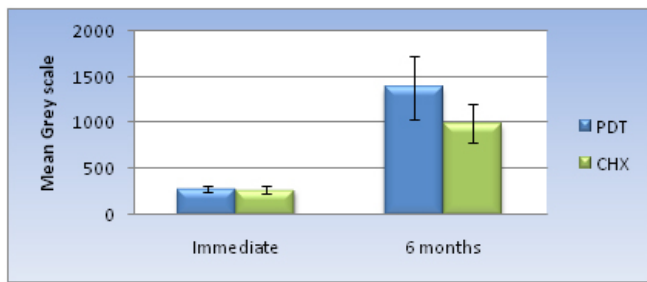


Figure 9: Bar chart representing mean and standard deviation values for Grey scale values in the two groups

Discussion

The disadvantage of the placement of implants into the sockets of teeth with periapical lesions is the potential for implant contamination during the initial healing period because of remnants of the infection [17]. Bacteroides species can inhabit tooth periapical lesions while being encapsulated in a polysaccharide that promotes its virulence, survival, and importance in mixed infections. Bacteroides forsythus has been shown to persist in asymptomatic periradicular endodontic lesions and may survive in bone in an encapsulated form after extraction and subsequently infect an implant [18].

The need for alternative efficient and affordable treatment of infections and illness has been imperative due to the widespread and increasing resistance of fungal, bacterial and viral pathogens to common antibiotics and therapies [19]. Photodynamic therapy has been used in recent decades and has been found useful in various diseases. Medical reports on successful application of photodynamic therapy of different diseases and studies on its effects caused a rapid growing interest in it. Some factors are responsible for its wide spreading such as bactericidal action, immunostimulating, analgesic and bioenergetics action, simplicity of performance, good tolerance by patients, absence of side-effects or adverse reactions and high medico-social and economic efficiency.

In our study we found that there was significant total bacterial count reduction on the photodynamic therapy study group more than chlorohexidine group (control side).

Lambrechts et al. explained that PAD using toluidine blue photosensitizer and low power diode laser light has proven to be a safe combination. Several safety issues have been examined as PAD does not give rise to deleterious thermal effect for adjacent tissues, PAD treatment does not cause sensitization and killing of adjacent human cells such as fibroblasts and keratinocytes, neither the dye nor the reactive oxygen species produced from it are toxic to the patient, bacteria are not able to produce resistant strains to the photoactive agent, PAD is effective against different types of microorganisms for root canals as (Enterococcus faecalis, streptococcus intermedius, Fusobacterium nucleatum, Peptostreptococcus micros, Prevotella intermedia), Perio pockets and mucosal diseases as (Porphyromonas gingivalis, Actinobacillus actinomycetemcomitans, Fusobacterium nucleatum, Streptococcus sanguinis, Bacteroides forsythus and Eikenella corrodens), Sites of peri-implantitis, Deep carious lesions as (Streptococcus mutans, Streptococcus sobrinus, Lactobacillus casei and Actinomyces

viscosus) and viral and fungal diseases like oral herpes and candidosis [20].

There are two mechanisms of action that have been proposed for lethal damage caused to bacteria by PAD:

(i) DNA damage (ii) Damage to cytoplasmic membrane, allowing cellular contents or inactivation of membrane transport systems and enzymes. Breaks in both single-stranded and double-stranded DNA, the disappearance of the plasmid super-coiled fraction have been detected in both gram positive and gram negative species after PAD. There is some evidence that PS that can more easily intercalate into double-stranded DNA can easily cause damage. Thus inactivation of membrane enzymes and receptors is also possible [21].

After the statistical analysis of data of the present study revealed that after 7 days, there was significant pain reduction in side of the photodynamic therapy than the other side, this may be attributed to the anti-inflammatory effect of the photodynamic therapy which is responsible for generation of reactive oxygen species (ROS) which is responsible for:

- Possible inactivation and inhibition of the release of proteolytic enzymes and pro-inflammatory cytokines.
- An increased release of interleukin one (IL-1) soluble receptor or of other soluble receptors and antagonists able to neutralize pro-inflammatory cytokines such as IL-1, IL-8, IL-12, IL-15 and tumor necrosis factors (TNFs).
- Conversely the release of immunosuppressive cytokines, such as TGF- β 1 and IL-10 may inhibit inflammation.
- Release of bradykinin and synthesis of inflammatory prostaglandins (PGs) is probably inhibited, with reabsorption of edema and pain relief [22].

These results agree with Von Felbert et al., their research showed pain reduction in patients with multiple actinic keratosis when treated with photodynamic therapy [23].

We revealed in this study that the side of photodynamic therapy through all the periods showed significantly lower mean percentage of facial edema than the other side, it attributed this due to photodynamic therapy reacts with biomolecules (antioxidants, PUFA, Proteins), generates ROS responsible for;

- Release of Bradykinine and synthesis of inflammatory Prostaglandins may be inhibited with reabsorption of edema and pain relief.
- The release of immunosuppressive cytokines such as TGF- β 1 and IL-10 may inhibit inflammation.
- An increased release of Interlukin-1 soluble receptor or of other soluble receptors and antagonists able to neutralize pro-inflammatory cytokines such as Interlukin- 1,8,12,15 & TNF.
- Possible inactivation and inhibition of the release of proteolytic enzymes and pro-inflammatory cytokines [23,24].

As for the radiographic assessment, digora software system was used to evaluate the bone density around the implant. It is taken immediately postoperatively and after 6 months.

The results showed significant higher mean percentage of bone density, decrease in probing depth and significant more stability of implant using Osstell in the side of photodynamic therapy.

The process of osseointegration involves a sequence of well-orchestrated biological responses initiated following implant placement involving immediate, rapid deposition of blood and interstitial fluid followed by amorphous deposition of proteoglycans and randomly aligned collagen and finally, direct bone apposition.

The intricate complexity of cell signaling networks involving growth factors (e.g. bone morphogenetic protein and fibroblast growth factor) and transcriptional factors (e.g. Sox9, Runx2 and Osterix) have all been shown to have pivotal roles in driving peri-implant tissue healing and regeneration gene expression signatures that are being investigated to enable better, predictive clinical responsiveness [25].

TGF-bs have a central role in mediating a diverse range of biological functions in wound healing such as cell migration, proliferation, secretion, differentiation and functions of a broad range of cell types [26]. While TGF-b promotes re-epithelization of wounds by promoting keratinocyte migration, it also stimulates extracellular matrix deposition and wound contraction by myofibroblasts. Further, it has potent immunomodulatory roles, both stimulating and inhibiting T-cells. A distinct immunosuppressive role for TGF-b includes its ability to drive development of regulatory T cells via expression of the transcription factor Foxp3 [27].

Low level laser had recently noted to activate latent TGF-B1, TGF-b1 has multiple roles in bone pathophysiology and is a key player in osseointegration [28,29].

Low level laser therapy increase DNA and RNA synthesis indicating an effect on cell growth and protein synthesis. It is suggested that low laser irradiation results in a small amount of singlet oxygen, which act as a free radical that influences the formation of adenosine triphosphate (ATP) which has an important role in metabolism. So laser irradiation is assumed to intensify the formation of transmembrane electrochemical proton gradients in mitochondria. Thus the efficiency of the proton-motive force is increased and more calcium is released from the mitochondria. The additional calcium transported into cytoplasm is believed to trigger mitosis and/or enhance cell proliferation [30].

Low level laser therapy was to have a pronounced effect on proliferation, differentiation and calcification of cultured osteoblastic cells. Low level laser therapy photo-activates osteoblastic cells, accelerates osteoblastic cell growth and calcification in vitro. Therefore it promotes bone regeneration [31,32].

Conclusion

From the current study, it could be concluded that:

- a) Significant decrease in pain severity in the photo activated disinfection group.
- b) Significant decrease in percentage of facial edema in the photo activated disinfection group.
- c) Significant increase in bone density around the implant in the side of photodynamic therapy after 6 months suggesting that the photo activated disinfection has bio-stimulating effect on bone regeneration and apposition.
- d) Photodynamic therapy group has a significant antibacterial effect compared to chlorohexidine group.
- e) Significant increase in implant stability in photo activated

disinfection group.

- f) Immediate implant placement can be considered as a safe, effective and predictable treatment option for restoration of fresh postextraction infected socket when appropriate preoperative procedures are taken to clean and decontaminate the surgical sites.

References

1. Adell R, Lekholm U, Rockler B, Brånemark PI (1981) A 15-year study of osseointegrated implants in the treatment of the edentulous jaw. *Int J Oral Surg* 10: 387-416.
2. Naves M, Horbylon BZ, Gomes F, Menezes H, Bataglion C, et al. (2009) Immediate implants placed into infected sockets: a case report with 3-year follow-up. *Braz Dent J* 20: 254-258.
3. Schulte W, Heimke G (1976) Ceramics in dental implantology 27: 17-23.
4. Anneroth G, Hedstrom KG, Kjellman O, Kondell PA, Nordenram A (1985) Endosseus titanium implants in extraction sockets. An experimental study in monkeys. *Int J Oral Surg* 14: 50-54.
5. Lazzara RJ (1989) Immediate implant placement into extraction sites: surgical and restorative advantages. *Int J Periodontics Restorative Dent* 9: 333-343.
6. Derks J, Schaller D, Hakansson J, Wennstrom JL, Tomasi C, et al. (2016) Effectiveness of Implant Therapy Analyzed in a Swedish Population: Prevalence of Peri-implantitis. *J Dent Res* 95: 43-49.
7. Bell CL, Diehl D, Bell BM, Bell RE (2011) The immediate placement of dental implants into extraction sites with periapical lesions: a retrospective chart review. *J Oral Maxillofac Surg* 69: 1623-1627.
8. Crespi R, Cappare P, Gherlone E (2010) Fresh-socket implants in periapical infected sites in humans. *J Periodontol* 81: 378-383.
9. Novaes Jr, Novaes AB (1998) Immediate implants placed into infected sites: a histomorphometric study in dogs. *Int J OralMaxillofac Implants* 13: 422-427.
10. Asas JA, Paster BJ, Stokes LN, Olsen I, Dewhirst FE (2005) Defining the normal bacterial flora of the oral cavity. *J Clin Microbiol* 43: 5721-32.
11. Romano F, Barbui A, Aimetti M (2007) Periodontal pathogens in periodontal pockets and in carotid atheromatous plaques. *Minerva Stomatol* 56: 169-79.
12. Gundermann KO (1989) The disinfection of the oral mucosa. *Zentralbl Bakteriol Mikrobiol Hyg* 187: 382-389.
13. Esposito M, Grusovin MG, De Angelis N, Camurati A, Campailla M, et al. (2015) The adjunctive use of light-activated disinfection (LAD) with FotoSan is ineffective in the treatment of peri-implantitis: 1-year results from a multicentre pragmatic randomised controlled trial. *Eur J Oral Implantol* 6: 109-119.
14. Andrade PF, Garlet GP, Silva JS, Fernandes PG, Milanezi C, et al. (2013) Adjunct effect of the antimicrobial photodynamic therapy to an association of non-surgical and surgical periodontal treatment in modulation of gene expression: a human study. *J Photochem Photobiol B* 126: 119-125.
15. Arweiler NB, Pietruska M, Skurska A, Dolinska E, Pietruski JK, et al. (2014) Nonsurgical treatment of aggressive periodontitis with photodynamic therapy or systemic antibiotics. Three-month results of a randomized, prospective, controlled clinical

- study. *Schweiz Monatsschr Zahnmed* 123: 532-544.
16. Schar D, Ramseier CA, Eick S, Arweiler NB, Sculean A, et al. (2013) Anti-infective therapy of peri-implantitis with adjunctive local drug delivery or photodynamic therapy: six-month outcomes of a prospective randomized clinical trial. *Clin Oral Implants Res* 24: 104-110.
 17. Quirynen M, Vogels R, Alsaadi G, Naert I, Jacobs R, et al. (2005) Predisposing conditions for retrograde peri-implantitis, and treatment suggestions. *Clin Oral Implants Res* 16: 599-608.
 18. Siqueira JF, Rijas IN, Oliveria JC, Santos KR (2001) Molecular detection of black-pigmented bacteria in infections of endodontic origin. *J Endod* 27: 563-566.
 19. Winckler KD (2007) Focus on antimicrobial photodynamic therapy (PDT). *Journal of photochemistry and photobiology* 86: 43-44.
 20. Lambrechts P, Huybrechts B, Bergmans L, Moisiadis P, Mattar D, et al. (2007) Photoactivated disinfection (PAD). *Dental Tribune, United Kingdom Edition* 20-25.
 21. Wainwright M (1998) Review - photodynamic antimicrobial chemotherapy (PACT). *J. Antimicrob. Chemother* 42: 13-28.
 22. Schneider M, Kirfel G, Berthold M, Frentzen M, Krause F, et al. (2012) The impact of antimicrobial photodynamic therapy in an artificial biofilm model. *Lasers Med Sci* 27: 615-620.
 23. Von Felbert V, Hoffmann G, Hoff-Lesch S, Abuzahra F, Renn CN, et al. (2010) Photodynamic therapy of multiple actinic keratoses: reduced pain through use of visible light plus water-filtered infrared A compared with light from light-emitting diodes. *Br J Dermatol* 163: 607-615.
 24. Gudgin Dickson EF, Goyan RL, Pottier RH (2002) New directions in photodynamic therapy. *Cell Mol Biol* 48: 939-954.
 25. Nishimura I (2013) Genetic networks in osseointegration. *J Dent Res* 92: 109-118.
 26. Sporn MB, Roberts AB (1990) TGF-beta: problems and prospects. *Cell Regul* 1: 875-882.
 27. Finnsen KW, Arany PR, Philip A (2013) Transforming growth factor beta signaling in cutaneous wound healing: lessons learned from animal studies. *Adv Wound Care (New Rochelle)* 2: 225-237.
 28. Bonewald LF, Mundy GR (1990) Role of transforming growth factor-beta in bone remodeling. *Clin Orthop Relat Res* 250: 261-276.
 29. Smith RA (1995) The effect on TGF-beta 1 on osseointegration. *J Calif Dent Assoc* 23: 49-53.
 30. Khadra M, Kasem N, Haanaes HR, Ellingsen JE, Lyngstadaas SP (2004) Enhancement of bone formation in rat calvarial bone defects using low-level laser therapy. *Oral surgery, Oral medicine, Oral pathology, Oral Radiology and Endodontics* 97: 693-700.
 31. Da Silva RV, Camilli JA (2006) Repair of bone defects treated with autogenous bone graft and low-power laser. *The journal of craniofacial surgery* 17: 297-301.
 32. Rochkind S, Kogan G, Luger EG, Salame K, Karp E, et al. (2004) Molecular structure of the bony tissue after experimental trauma to the mandibular region followed by laser therapy. *Photomedicine and laser surgery* 22: 249-253.

Copyright: ©2017 Ahmed Nagi Alghandour, et al. This is an open-access article distributed under the terms of the Creative Commons Attribution License, which permits unrestricted use, distribution, and reproduction in any medium, provided the original author and source are credited.