

Ectopic Pregnancy in a Caesarean Section Scar Case Report

Maheshgir S Gosavi*

Siraj Hospital, Senior Consultant, Thane, India

*Corresponding author

Maheshgir S Gosavi, Siraj Hospital, 4th Nizampura, Vanjarpatti Naka, Bhiwandi, Thane, Maharashtra state, India, Tel: +91-02522-253200, +91-8693027439.

Submitted: 22 June 2017; Accepted: 30 June 2017; Published: 08 July 2017

Abstract

I report a rare case of ectopic pregnancy occurring in the scar of a previous caesarean section, diagnosed by ultrasonography of pelvis and confirmed with histopathological diagnosis. I present the clinical details and imaging findings, followed by discussion of the etiology, pathogenesis, and imaging of this condition.

Keywords: Caesarean scar pregnancy, Ectopic pregnancy, Dilatation and curettage, Trans vaginal ultrasonography, Caesarean scar.

Introduction

Ectopic pregnancy is one of the leading causes of mortality among women of child-bearing age group. Most of these ectopic gestations are located in the fallopian tube, ampulla being the most common location. However, ectopic pregnancies are also known to occur in the cervix, ovary, previous caesarean scar, and abdomen. Intramural pregnancy with implantation in a previous caesarean section scar is probably the rarest location for ectopic pregnancy [1]. This type of pregnancy is prone for complications like uterine rupture, life-threatening hemorrhage, and hypovolemic shock.

The true incidence of pregnancy occurring in a uterine scar has not been determined because so few cases have been reported in the literature. However, the incidence of such cases seems to be on the rise [1,2]. This may reflect both the increasing number of caesarean sections being performed and the more widespread use of the transvaginal scan that allows earlier detection of such pregnancies [3]. The diagnosis is usually made on ultrasonography and can be confirmed during laparoscopy and/or laparotomy.

Case Presentation

A 33-year-old woman had come for routine antenatal check up after 6 weeks of amenorrhea and positive urine pregnancy test. She has complaints of bleeding per vaginum. She had history of 2 previous caesarean sections; first one performed 5 years back for intrapartum fetal distress and the second one performed 2 years back due to complete placenta previa. Transabdominal sonography supplemented by transvaginal sonography revealed empty uterine cavity and empty cervical canal with a irregular heterogenous mass in anterior uterine segment, with a gestational sac measuring 0.4 cm corresponding to 4wks 1 day. On Doppler examination peripheral rim of choriodecidual reaction vascularity was seen.

Patient underwent exploratory laparotomy with excision of mass

and repair of lower uterine segment. Histopathology proved the diagnosis of ectopic pregnancy in the lower uterine segment.

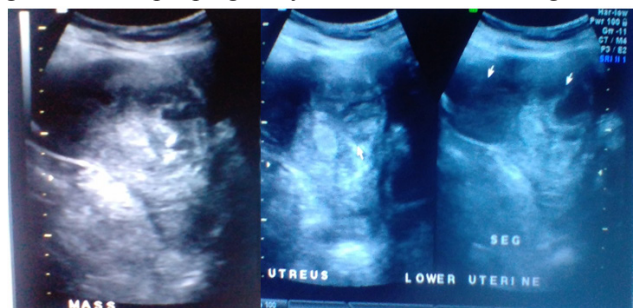


Figure 1: Trans abdominal Sonography shows irregular mass in lower uterine segment

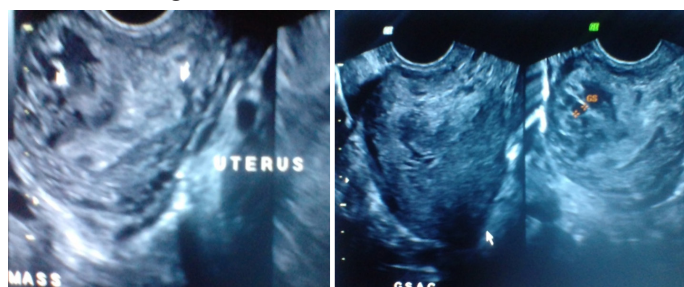


Figure 2: Trans Vaginal I Sonography shows irregular mass in lower uterine segment with gestational sac within.

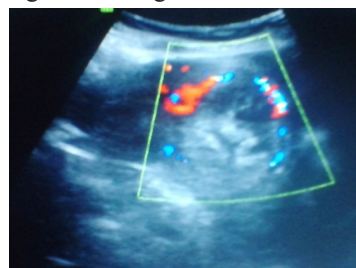


Figure 3: Doppler examination shows peripheral vascularity.

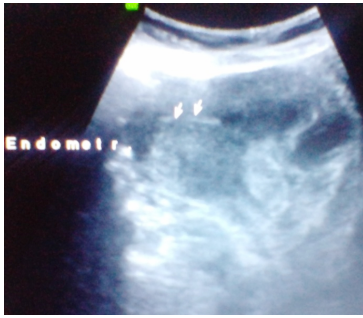

Figure 4: Endometrium Canal is Clear.

Discussion

There are many theories which explain the occurrence of intramural ectopic pregnancy. The most accepted theory seems to be that the blastocyst invades into the myometrium through a microscopic dehiscence tract, which may be the result of trauma of a previous caesarean section or any other uterine surgery or even after manual removal of the placenta [4,5]. Another mechanism for intramural implantation may be in vitro fertilization and embryo transfer, even in the absence of any previous uterine surgery. Vial et al. proposed that there were 2 different types of such ectopic pregnancies [6]. In the first type, after implantation of the gestational sac on the uterine scar, there is progression away from the serosal lining, either toward the cervicoisthmic space or toward the uterine cavity. Such a pregnancy may proceed to full term and a viable birth, but with an increased risk of life-threatening massive bleeding from the site of implantation [7]. The second type is a deep implantation into a uterine scar with progression towards the serosal surface. This culminates in rupture and bleeding during the first trimester of pregnancy. Some authors (Ghezzi et al.) believe that the difference between those 2 types of pregnancy is of paramount importance [2]. When there is a continuous connection to the uterine cavity, expectant management is justified because pregnancy may continue until a viable birth. In the latter type, if immediate treatment is not undertaken, the risk of late first-trimester uterine rupture and life-threatening bleeding is very high.

According to Jurkovic et al. in view of the lack of significant data, each woman should be given all the available information and the opportunity to decide on the management of her pregnancy. However, in a study done on 8 women diagnosed with caesarean scar ectopic pregnancy, of which 1 underwent expectant management, Maymon et al. believed that the prognosis for an uneventful term pregnancy is still very poor [3,8].

Typically, the diagnosis is made based on ultrasound evaluation of the uterus and confirmed during laparoscopy and/or laparotomy. Sonography combined with Doppler flow imaging has been advocated as a very reliable tool for detecting these cases.

Proposed ultrasound diagnostic criteria for diagnosis of an intramural ectopic gestation, with a differential diagnosis cervical ectopic pregnancy are (1) a gestational sac located between the bladder wall and the anterior isthmic portion of the uterus; (2) no trophoblastic tissue visible in the uterine cavity and cervical canal; and (3) clearly visible circular blood flow surrounding the sac.

Two principal management options are available, the medical or the surgical. The medical or conservative treatment mainly

consists of methotrexate, administered either systemically, locally, or combined [3,9,10,11]. A caesarean scar ectopic pregnancy is surrounded by fibrous scar rather than by a normal vascularized decidual reaction. This also may potentially delay complete resorption of the pregnancy. Concomitant fine needle aspiration of the remaining fluid in the sac is often adopted [9]. Nevertheless, on rare occasions, rupture of the scar and heavy bleeding may occur after medical treatment [3]. The medical approach is sometimes combined with bilateral uterine artery embolization, minimizing risk of life-threatening hemorrhage [2].

Two principal management options are available, the medical or the surgical. The medical or conservative treatment mainly consists of methotrexate, administered either systemically, locally, or combined [3,9-11]. A caesarean scar ectopic pregnancy is surrounded by fibrous scar rather than by a normal vascularized decidual reaction. This also may potentially delay complete resorption of the pregnancy. Concomitant fine needle aspiration of the remaining fluid in the sac is often adopted [9]. Nevertheless, on rare occasions, rupture of the scar and heavy bleeding may occur after medical treatment [3]. The medical approach is sometimes combined with bilateral uterine artery embolization, minimizing risk of life-threatening hemorrhage [2].

A number of reports have supported the surgical alternative, even in the absence of active bleeding [1,5,12]. This consists of elective laparotomy and excision of the gestational mass. These authors have advocated that resection of the old scar with a new uterine closure can reduce the risk of recurrence. In addition, in the absence of complications, the follow up period seems to be shorter compared with patients managed conservatively.

However, currently, no modality appears to be entirely reliable and none can guarantee uterine integrity [3,13]. It is a recognized fact that a caesarean section is associated with a future risk for placental pathologies (eg, placenta previa, placental abruption, and placenta accreta) and ectopic pregnancies. However, a caesarean scar pregnancy is considered to be even more aggressive than placenta previa or accreta because it invades the myometrium in the first trimester [14]. Patients who have undergone multiple caesarean sections appear to bear increased risk for in-scar implantation of the subsequent pregnancy because of increased scar surface area [3,8]. With the advent of transvaginal sonography and with the use of saline infusion, it is possible to assess post caesarean section uterine wall integrity even in the non-pregnant state [3,15,16]. Caesarean section scar defect is identified by the presence of fluid within the incision site or any filling defect (“niche”), which is defined as a triangular anechoic structure at the presumed site of the scar [15,16].

Conclusion

Intramural pregnancy with implantation in a previous caesarean section scar is probably the rarest location for ectopic pregnancy. This type of pregnancy may become complicated with uterine rupture and life-threatening hemorrhage. Therefore, early diagnosis of caesarean scar ectopic gestation using sonography combined with Doppler flow imaging is of paramount importance, followed by confirmation of pelvic MRI if and when indicated. Although expectant management has been attempted in some cases, currently available data support termination of such a pregnancy once the correct diagnosis is made [17,18].

Acknowledgements

The author would like to thank the pathologists, gynaecologists who provided very important feedback with regard to the clinical aspect of this patient's condition. They contributed significantly to the patient being promptly diagnosed and receiving a high standard of care.

References

1. Fylstra DL, Pound-Chang T, Miller MG, Cooper A, Miller KM (2002) Ectopic pregnancy within a Caesarian delivery scar: a case report. *Am J Obstet Gynecol* 187: 302e4.
2. Ghezzi F, Lagana D, Franchi M, Fugazzola C, Bolis P (2002) Conservative treatment by chemotherapy and uterine arteries embolization of a Caesarean scar pregnancy. *Eur J Obstet Gynecol Reprod Biol* 103: 88e91.
3. Jurkovic D, Hillaby K, Woelfer B, Lawrence A, Salim R, Elson CJ (2003) First-trimester diagnosis and management of pregnancies implanted into the lower uterine segment Caesarian section scar. *Ultrasound Obstet Gynecol* 21: 220e7.
4. Cheng PJ, Chueh HY, Soong YK (2003) Sonographic diagnosis of a uterine defect in a pregnancy at 6 weeks gestation with a history of curettage. *Ultrasound Obstet Gynecol* 21: 501e3.
5. Fylstra DL (2002). Ectopic pregnancy within a Caesarean scar: a review. *Obstet Gynecol Surv* 57: 537e43.
6. Vial Y, Petignat P, Hohlfeld P (2000) Pregnancy in a Caesarian scar. *Ultrasound Obstet Gynecol* 16:592e3.
7. Herman A, Weinraub Z, Avrech O, Maymon R, Ron-El R, Bukovsky Y (1995) Follow up and outcome of isthmic pregnancy located in a previous caesarean section scar. *Br J Obstet Gynecol* 102: 839e41.
8. Maymon R, Halperin R, Mendlovic S, Schneider D, Vaknin Z, Herman A, et al (2004) Ectopic pregnancies in Caesarean section scars: the 8 year experience of one medical centre. *Hum Reprod* 19: 278e84.
9. Ravhon A, Ben-Chetrit A, Rabinowitz R, Neuman M, Beller U (1997) Successful methotrexate treatment of a viable pregnancy within a thin uterine scar. *Br J Obstet Gynecol* 104: 628e9.
10. Shufaro Y, Nadjari M (2001). Implantation of a gestational sac in a Caesarian section scar. *Fertil Steril* 75: 1217.
11. Nawroth F, Foth D, Wilhelm L, Schmidt T, Warm M, Romer T (2001) Conservative treatment of ectopic pregnancy in a Caesarian section scar with methotrexate: a case report. *Eur J Obstet Gynecol* 99: 135e7.
12. Rampen A (1997) An ectopic pregnancy embedded in the myometrium of a previous Caesarian section scar. *Acta Obstet Gynecol Scand* 76: 492.
13. Lee CL, Wang CJ, Chao A, Yen CF (1999) Soong YK. Laparoscopic management of an ectopic pregnancy in a previous caesarean section scar. *Hum Reprod* 14: 1234e6.
14. Seow K-M, Hwang J-L, Tsai Y-L (2001) Ultrasound diagnosis of a pregnancy in a Caesarian section scar. *Ultrasound Obstet Gynecol* 18: 547e51.
15. Armstrong V, Hansen WF, Van Voorhis BJ, Syrop CH (2003) Detection of Caesarian scars by transvaginal ultrasound. *Obstet Gynecol* 101: 61e5.
16. Monteagudo A, Carreno C, Timor-Tritsch IE (2001) Saline infusion sonohysterography in nonpregnant women with previous Caesarian delivery: the 'niche' in the scar. *J Ultrasound Med* 20: 1105e15.
17. Hamilton CJ, Legarth J, Jaroudi KA (1992) Intramural pregnancy after in vitro fertilization and embryo transfer. *Fertil Steril* 57: 215e7.
18. Sugawara J, Senoo M, Chisaka H, Yaegashi N, Okamura K (2005) Successful conservative treatment of a cesarean scar pregnancy with uterine artery embolization. *Tohoku J Exp Med* 206: 261e5.

Copyright: ©2017 Maheshgir S Gosavi. This is an open-access article distributed under the terms of the Creative Commons Attribution License, which permits unrestricted use, distribution, and reproduction in any medium, provided the original author and source are credited.