

## Ectopic Gallbladder: An Incidental Finding

Mubashar Hussain<sup>1</sup>, Jimmy Mena<sup>2\*</sup> and Kristine Joyce Cadiz<sup>3</sup>

<sup>1</sup>Consultant Department of General Surgery, Newham University Hospital, Barts health trust, London

<sup>2</sup>Senior Clinical Fellow Department of General Surgery, Newham University Hospital, Bart's health trust, London

<sup>3</sup>Junior Clinical Fellow Department of General Surgery, Newham University Hospital, Bart's health trust, London

### \*Corresponding author

Jimmy Mena, Senior Clinical Fellow Department of General Surgery, Newham University Hospital, Barts health trust, London

Submitted: 06 Aug 2020; Accepted: 26 Aug 2020; Published: 04 Sep 2020

### Background

Ectopic gallbladder is a rare entity with an incidence of 0.1%- 0.7% [1]. Normally, it lies on the gallbladder fossa, on the inferior surface of the liver in between the right and left hepatic lobes, maintaining a constant relationship to porta hepatis [2]. On Ultrasonographic imaging, the gallbladder can be identified by the relationship of the gallbladder neck anterior to the right branch of the portal vein. Ectopic gallbladder can be located in various positions such as intrahepatic, within the lesser omentum, retroduodenal, within falciform ligament, abdominal wall muscles and in thoracic cavity [3, 4]. An ectopic gallbladder is a dangerous entity as it can lead to misdiagnosis.

We were presented a case of ectopic gallbladder, which was missed in ultrasound, and CT scan report but was discovered intra operatively during laparoscopic cholecystectomy

**Keywords:** Ectopic, Gallbladder

### Abbreviations

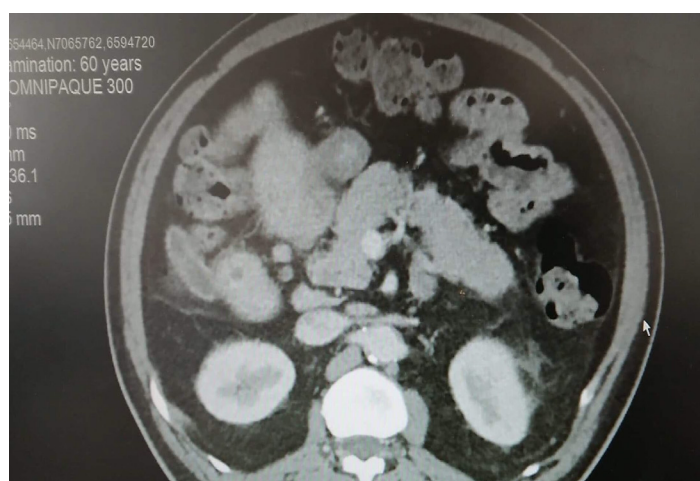
CT: Computed tomography

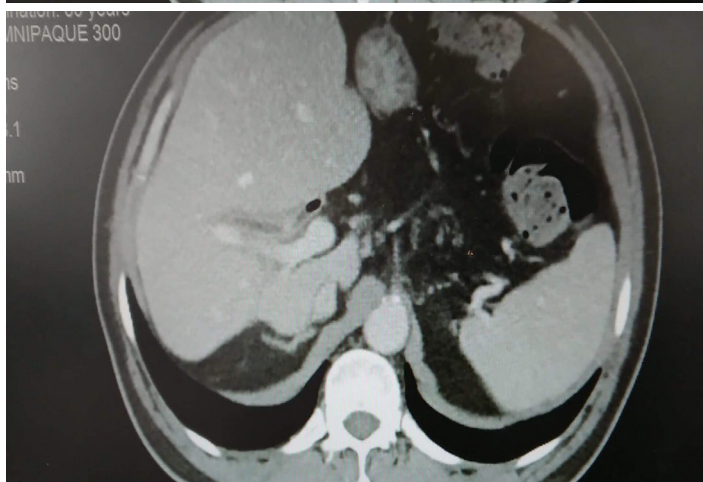
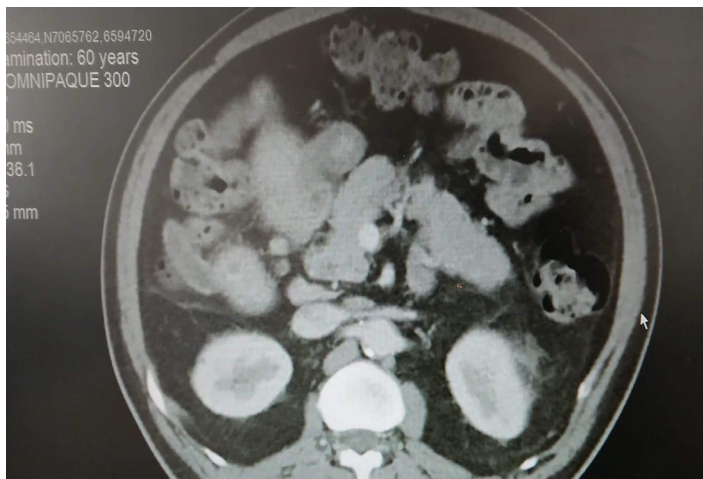
### Case Presentation

A 60-year-old male came in with 3-year-history of recurrent episodes of abdominal pain, nausea, and fever. The latest episode were three months before the operation. On examination, there was RUQ tenderness, and Murphy sign positive.

### Imaging studies

Ultrasonography showed a gallbladder that is normal in shape, wall thickness, and no gallstones seen. No peri cholecystic fluid nor collection. While CT scan showed a gallbladder that was sub-hepatic located just beneath the right hepatic lobe, with apparently elongated cystic duct, which was not mentioned in report but was discussed later with a radiology consultant.





The patient was then booked for an elective laparoscopic cholecystectomy and patient was consented for procedure.

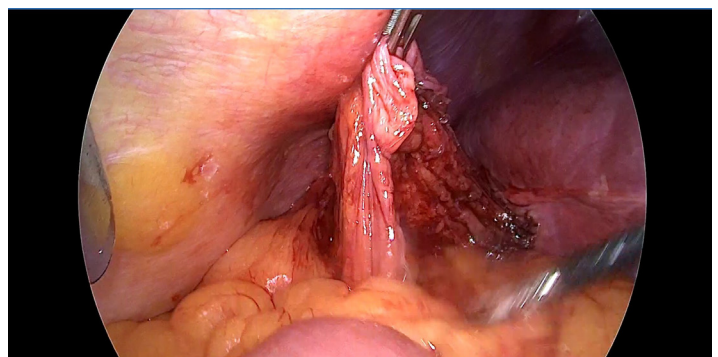
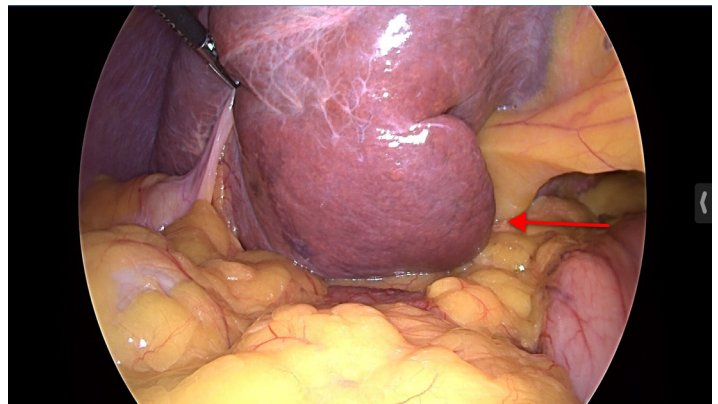
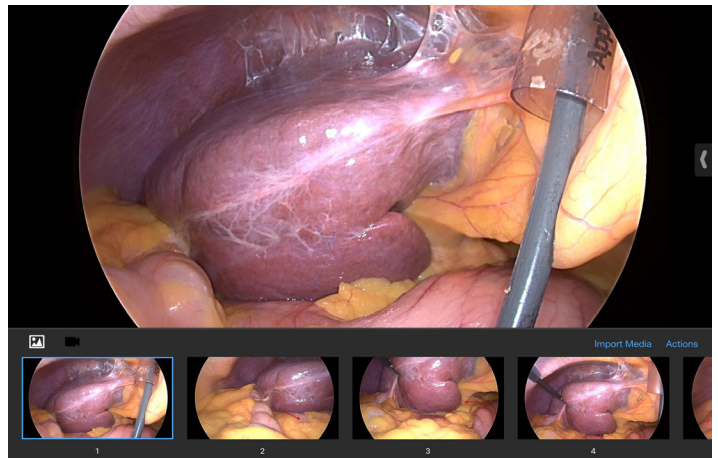
During the operation, four ports were inserted in the anterior abdominal wall, followed by intra peritoneal gas insufflation. An attempt to identify the gallbladder in the normal site was done; gallbladder was not identified.

Intraoperatively the hepatic flexure was noted to be attached to the liver anterolaterally with a band. The band was excised using hook diathermy, and there was another band noted to be attached to liver and going beneath the ascending colon. The band was followed and at the end was the gallbladder hanging and it looked like an elongated, cystic, luminal structure, which was found to be linked with another band which is then attached to the ascending colon.

Both bands were excised using diathermy hook, the gallbladder was dissected from omental adhesions surrounding it until cystic duct was properly identified. The cystic duct was elongated, and tortuous, curving above the hepatic flexure and going down the

liver. Retrograde dissection of gallbladder was done followed by identification of cystic artery which was then clipped and cut. The cystic duct was clipped and, ligated with endo-loop to be more secure and was cut safely, leaving a relatively long cystic duct stump.

The gallbladder was removed and sent for histopathology. Good haemostasis was achieved, and drain was placed and left for one day. Port-sites were closed in layers. Post operatively, the patient had uneventful recovery, enteral feeding was tolerated, and drain was removed the following day. Patient was then deemed fit for medical discharge with a follow-up in the outpatient clinic.



## Discussion

The gallbladder is generally found in the right upper quadrant of abdomen situated in segments IVB and V of the liver [5]. Anatomically, the gallbladder is divided into three sections: the fundus, body and neck, it measures approximately 8 centimetres in length and 4 centimeters in diameter when fully distended [6].

There are three-types of congenital anomalies of the gallbladder in terms of - shape, location and congenital absence. In terms of location, an ectopic gallbladder is one, where gallbladder is not located in its usual anatomical position but rather, it is identified in an unusual site on routine imaging.

Ectopic gallbladder may cause clinical symptoms or may be asymptomatic. If an ectopic one is situated away from peritoneum, typical signs and symptoms of acute cholecystitis may not be observed. The ectopic gallbladder may be floating and is suspended by a long mesentery, which is susceptible to torsion and gangrene [7-10]. In the case presented, rather than finding the gallbladder in its usual anatomical position, it was identified as an elongated, cystic structure in the sub hepatic region- beneath the right hepatic lobe.

## Conclusion

Ectopic gallbladder can raise diagnostic dilemma. Hepatobiliary scan plays an important role in diagnosing various gallbladder anomalies including agenesis, and ectopic position. Proper scan review and report is essential for full assessment pre-operatively.

## Acknowledgements

I appreciate the great effort done by Mr Hussain Mubashar for the great support and guidance to collect and interpret data and present it in my first case report publication.

## Funding

There is no funding source.

## Contributions

MH was the main surgeon during this procedure and hecritically revised the manuscript. JM was in charge of acquisition of the data and writing the case scenario. KC was in charge of editing and reviewing the related literature. All authors read and approved the final manuscript.

## References

1. Rather AT, Khan HS, Singh M, Choh AN (2013) A Rare Case of Suprahepatic Gallbladder with Phocomelia and Pancytopenia: Detected by Tc- 99m Mebrofenin Scintigraphy. *World Journal of Nuclear Medicine* 12: 41-44.
2. Meloughlin JM, Fanti EJ, Kura LM (1987) Ectopic gallbladder: Sonographic and scintigraphic. *The Journal of Clinical Ultrasound* 15: 258-261.
3. Popli MB, Popli V, Solanki Y (2010) Ectopic Gallbladder: A Rare Case. *The Saudi Journal of Gastroenterology* 16: 50.
4. Audi P, Noronha PF, Rodrigues J (2009) Intrahepatic gallbladder- A case report and review of literature. *The internet journal of surgery* 24: 167-172.
5. Dever RC (1968) Suprahepatic gallbladder with torsion and gangrene. *J Fla Med Assoc* 55: 531.
6. Bockman DE, Freeny PC (1992) Anatomy anomalies of the biliary tree. *Laparos Surg* 1: 92.
7. Agarwal V, Pande S, Garg SK, Jangid DR (2011) Anomalously placed suprahepatic gallbladder: A case detected on F-18 FDG PET/CT. *Indian J Nucl Med* 26: 120-122.
8. Maeda N, Horie Y, Shiota G, Suou T, Andachi H, et al. (1998) Hypoplasia of the left hepatic lobe associated with floating gallbladder: A case report. *Hepatogastroenterology* 45: 1100-1103.
9. Mcnamee EP (1974) Intrahepatic gallbladder. *Am J Roentgenol; Radium Therapeutic Nucl Med* 121: 396-400.
10. Sharmin Reza, Faria Nasreen, Sharmin Quddus, Tapati Mandal, Ferdous Ara Hussain (2014) Ectopic gallbladder – An interesting case report. *J Nucl Med* 17: 156-158.

**Copyright:** ©2020 Jimmy Mena. This is an open-access article distributed under the terms of the Creative Commons Attribution License, which permits unrestricted use, distribution, and reproduction in any medium, provided the original author and source are credited.