

De novo Pemphigus Vegetans

Dr. Rita Vora

Skin opd no 111, Department of Dermatology, Shree Krishna Hospital, Pramukhswami medical college, Bhaikaka University, Karamsad -388325

*Corresponding author

Dr. Rita Vora, Skin opd no 111, Department of Dermatology, Shree Krishna Hospital, Pramukhswami medical college, Bhaikaka University, Karamsad -388325

Submitted: 03 Jun 2022; Accepted: 09 Jun 2022; Published: 20 Jun 2022

Citation: Dr. Rita Vora, (2022). De novo Pemphigus Vegetans, Int J Clin Expl Dermatol, 7(1), 29-32.

Abstract

Pemphigus vegetans is an autoimmune disease characterized by flaccid bullae or pustules that erode to form hypertrophic plaques involving predominantly skin flexures and mucous membranes [1]. We are presenting an unusual case of de novo pemphigus vegetans with extensive involvement of genitals, perianal area, buttocks, nails, oral mucosa, and cerebriiform tongue which was initially mistaken for malignancy due to its unusual presentation.

Keywords: De novo, Pemphigus Vegetans, Hypertrophic plaque

Introduction

Pemphigus vegetans is the rarest form of pemphigus vulgaris, accounting for approximately 1% to 2% of all cases and is considered a benign subgroup [2]. It is characterized by vesicles, bullae, pustules and erosions that consequently form vegetating masses. Clinically, two subtypes are recognized: Neumann and Hallopeau variants. The former is a belligerent non-healing bullous disorder contradictory to self remitting benign variant of Hallopeau [1]. Hallopeau type, initially characterized by pustular lesions that, after rupturing, merge and gradually evolve into vegetating erosions. The disorder affects chiefly middle-aged adults. Lesions are primarily flexural, although vegetations may occur at any site [3].

Case report

A 65 -year-old woman presented to our dermatology out-patient department with reddish elevated vegetative lesions over buttocks, genitals and groins which were associated with itching and oozing of fluid since 2 months without any history of vesicular, pustular or bullous lesions. Subsequently lesions transformed into thick, elevated, moist vegetating masses. Patient also developed clear fluid filled lesion under the nail plate of left toe nail followed by the detachment of nail from nail bed within few days.

Cutaneous examination showed few (4-5), well-defined, erythematous to hyperpigmented, indurated, plaques of size ranging from 1 × 1 cm to 6 × 7 cm with verrucous, vegetating moist surface present over bilateral groins, perianal area and buttocks. [Figure 1a&b] Few erythematous papules present over inner surface of right thigh and buttocks. Mucosal examination showed 3-4, well-defined, erythematous to hyperpigmented, indurated, plaques of size ranging from 1 × 1 cm to 3 × 4 cm with verrucous, vegetating moist surface present over bilateral labia majora and minora. [Figure 1a] Oral

cavity examination revealed multiple painful erosions over left angle of mouth, bilateral buccal mucosa and hard palate. Tongue was fissured and cerebriiform. [Figure 1c] Clear fluid filled vesicle was present under nail plate of right index finger and right thumb with detachment of distal nail plate of both nails. Gram stain taken from genital lesion discharge was negative. Histopathological examination showed verrucous and pseudoepitheliomatous hyperplasia with intraepidermal eosinophilic pustule formation. Suprabasal acantholysis with infiltration of plenty of eosinophils seen in dermis suggestive of pemphigus vegetans. [Figure 2a and b].

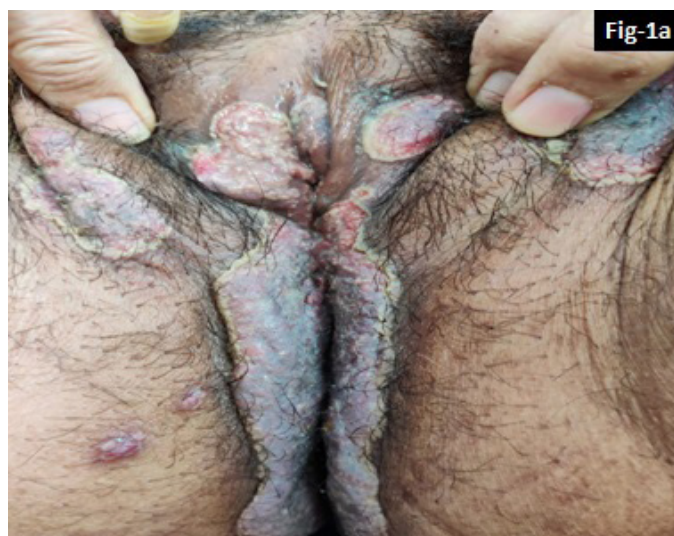

Figure 1a: 5-6 , well-defined, erythematous to hyperpigmented, indurated, plaques of size ranging from 1 × 1 cm to 3 × 4 cm with verrucous, vegetating moist surface present over bilateral groins, bilateral labia majora and minora.

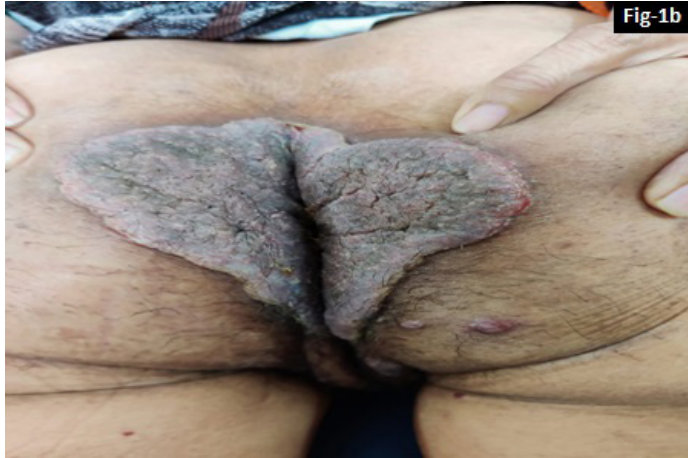

Figure 1b: Single well-defined, erythematous to hyperpigmented, indurated, plaque of size 6 × 7 cm with verrucous, vegetating moist surface present over perineal area and buttocks.

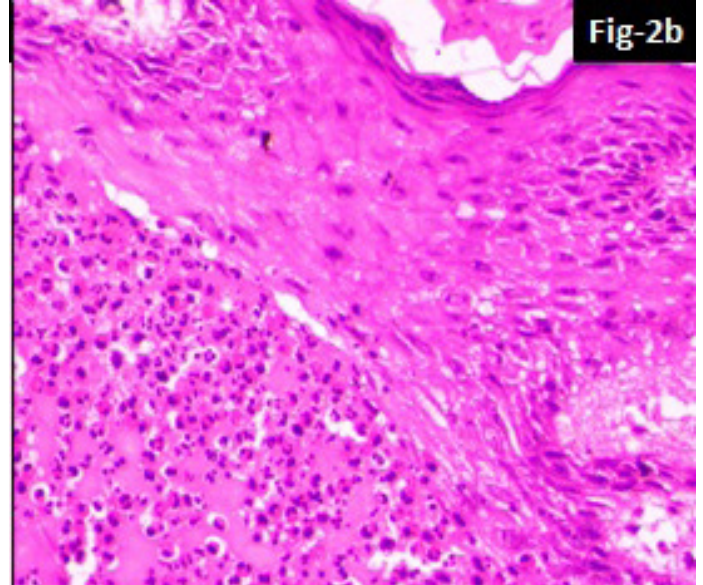


Figure 2b: Infiltration of plenty of eosinophils seen in dermis [H& E 40X]

Direct immunofluorescence revealed IgG and C3 deposition along the dermoepidermal junction.[Figure 3] We started our patient with oral methylprednisolone in tapering doses along with azathioprine which showed excellent result with significant clearing of her lesions.[Figure 4 a and b]

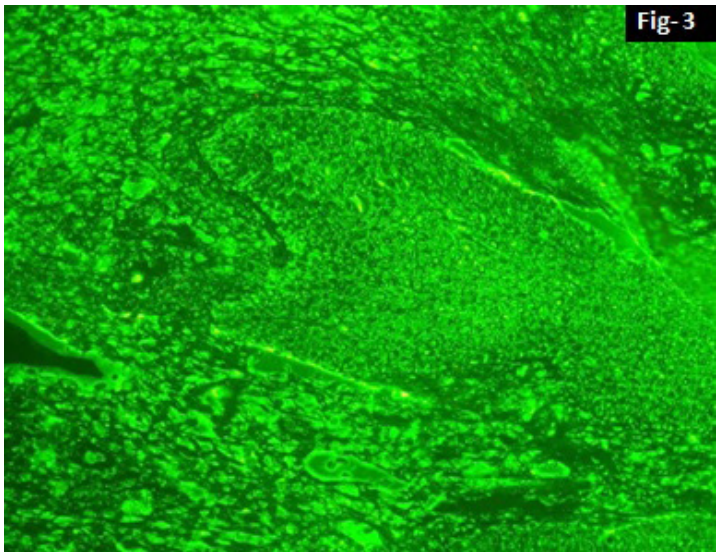


Figure 3: Direct immunofluorescence revealed IgG and C3 deposition along the dermoepidermal junction

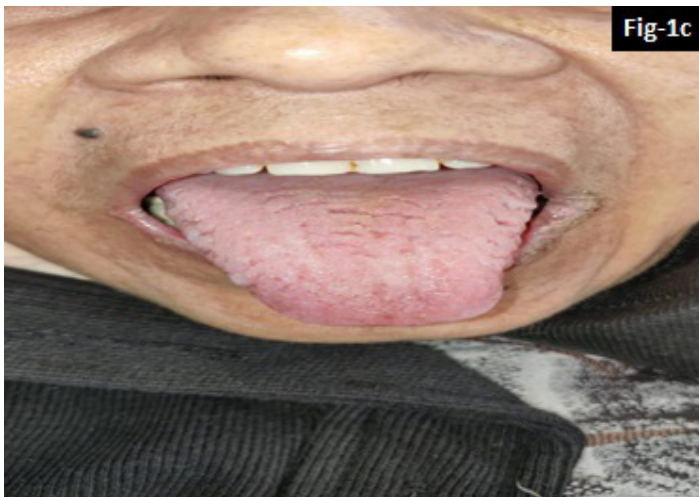

Figure 1c : Cerebriiform tongue

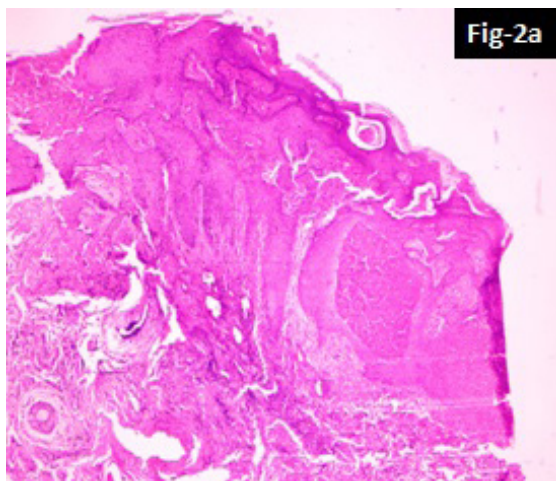


Figure 2a: Verrucous and pseudoepitheliomatous hyperplasia with intraepidermal eosinophilic pustule formation. Suprabasal acantholysis with infiltration of plenty of eosinophils seen in dermis [H& E 4X]

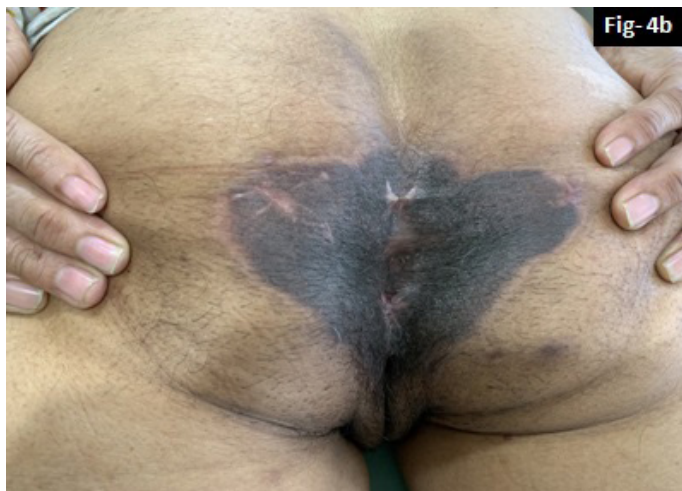
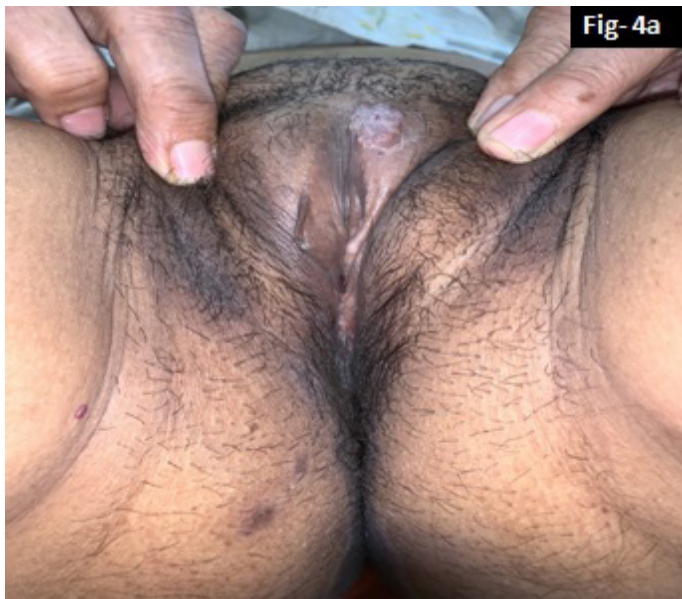
Figure 4 a&b: Post treatment significant clearance of lesions.

Discussion

Pemphigus vegetans is a rare variant of pemphigus vulgaris, first described by Neumann in 1876 [4]. It is categorized into two subtypes based on the initial presentation and disease course: Hallopeau and Neumann. The former begins as pustules and has a relatively benign course while the later, which is more frequent starts as flaccid vesicles and bullae and shows a poor response to therapy. Both the forms gradually evolve into hypertrophic vegetating plaques predominantly distributed in the intertriginous sites, although any site may be involved. Oral mucosa is affected in nearly 60-80% cases and often at the onset of the disease. Less commonly, pemphigus vegetans may be localized to unusual sites such as scalp, face, breast, leg and sole [2, 5-6].

Various conditions that have to be kept in the differential diagnosis include the vegetating lesions of other bullous autoimmune skin diseases, such as bullous pemphigoid or immunoglobulin A (IgA)

pemphigus, the chronic inflammatory plaques of Hailey-Hailey disease, and especially vegetating pyoderma [7]. Cerebriform tongue also seen in our case has been quoted as an eponymous sign for pemphigus vegetans [8]. Cytology (Tzanck test), histology, immunofluorescence, and ELISA search for anti-desmoglein antibodies are the diagnostic laboratory tools.

The principal autoantigen in pemphigus vegetans is desmoglein (Dsg) 3, although in some cases Dsg1 and desmocollin 1, 2 and 3 have also been implicated [7].

The standard treatment of this disease is with oral or systemic steroids on daily basis or DCP therapy [2-3,9].

Adjuvant immunosuppressants and immunomodulatory agents including azathioprine, cyclophosphamide, cyclosporine, intravenous immunoglobulin, nicotinamide with tetracycline, dapsone, and retinoids may be required to enhance the treatment Response [5].

To emphasize pemphigus vegetans, although a variant of pemphigus vulgaris, can present at atypical site or show limited involvement without involving mucosa giving a diagnostic challenge. So, it is important that though pemphigus vegetans being an uncommon should not be forgotten and must be kept as a differential in patients presenting with recalcitrant verrucous or papillomatous plaques.

References

1. Downie, J. B., Dicostanzo, D. P., & Cohen, S. R. (1998). Pemphigus vegetans—Neumann variant associated with intranasal heroin abuse. *Journal of the American Academy of Dermatology*, 39(5), 872-875.
2. Jain, V. K., Jindal, N., & Imchen, S. (2014). Localized pemphigus vegetans without mucosal involvement. *Indian Journal of Dermatology*, 59(2), 210.
3. Dhamija, A., D'souza, P., Meherda, A., & Kothiwala, R. K. (2012). Pemphigus vegetans: An unusual presentation. *Indian Dermatology Online Journal*, 3(3), 193.
4. Leroy, D., & JC, M. (1982). Pemphigus vegetant a type clinique de dermatite pustuleuse chronique de hallopeau.
5. Zarea, I., Sellami, A., Bouguerra, C., Sellami, M. K., Chelly, I., Zitouna, M., ... & Osman, A. B. (2011). Pemphigus vegetans: a clinical, histological, immunopathological and prognostic study. *Journal of the European Academy of Dermatology and Venereology*, 25(10), 1160-1167.
6. Wei, J., HE, C. D., WEI, H. C., Li, B., WANG, Y. K., JIN, G. Y., ... & CHEN, H. D. (2011). Facial pemphigus vegetans. *The Journal of Dermatology*, 38(6), 615-618.
7. Khullar, G., De, D., Narang, T., Saikia, U., & Handa, S. (2015). Pemphigus vegetans localized to unusual sites. *Indian Journal of Dermatology, Venereology and Leprology*, 81(5), 509.
8. Premalatha, S., Jayakumar, S., YESUDIAN, P., & Thambiah, A. S. (1981). Cerebriform tongue—a clinical sign in pemphigus vegetans. *British Journal of Dermatology*, 104(5), 587-587.

-
9. Oliveira, M. A. D., Lourenço, S., Gallottini, M., & Ortega, K. L. (2012). Oral pemphigus vegetans: A case report. *Dermatology Online Journal*, 18(10).

Copyright: ©2022, Dr. Rita Vora. This is an open-access article distributed under the terms of the Creative Commons Attribution License, which permits unrestricted use, distribution, and reproduction in any medium, provided the original author and source are credited.