

Continent Cystostomy Using the Benчекroun Hydraulic Valve: Role of Self-Catheterization to Prevent Serious Complications

Fouimtizi Jaafar*, Maachi Youssef, Slaoui Amine, Karmouni Tariq, EL Khader Khalid, Koutani Abdellatif and Iben Attya Ahmed

Urology B Department, Avicenne Hospital, University Hospital Center IBN SINA, University Mohammed V, Rabat, Morocco.

*Corresponding Author

Jaafar Fouimtizi, Urology B Department, Avicenne Hospital, University Hospital Center IBN SINA, University Mohammed V, Rabat, Morocco

Submitted: 2024, Feb 09; Accepted: 2024, Mar 15; Published: 2024, Mar 20

Citation: Jaafar, F., Youssef, M., Amine, S., Tariq, K., Khalid, E. K. et al. (2024). Continent Cystostomy Using the Benчекroun Hydraulic Valve: Role of Self-Catheterization to Prevent Serious Complications. *World J Clin Med Img*, 3(1), 01-02.

Keywords: Self-Catheterization, Continent Urinary Diversion, Benчекroun Hydraulic valve

1. Introduction

Continent urinary diversion, such as Benчекroun hydraulic valve, are a useful adjunct in the elaboration of continent urinary reservoir. This valve can be installed either as a salvage technique for failed efferent lambs or as a de novo application on conventional ileocolic bladders [1]. We report the case of a 46-year-old female patient who underwent 18 years ago a cystectomy for bladder exstrophy and a neobladder reconstruction with a Benчекroun hydraulic valve. Later on, the patient has developed a schizophrenia and stopped doing the self-catheterization. She was taken to the emergency

department by her family for a deterioration of general condition. The blood sample found a renal failure with a hyperkalemia at 7mEq/L and a CT-Scan showed a bilateral pyelocaliceal dilation with multiple big neobladder stones. The patient unfortunately passed away due to a respiratory distress secondary to her nephrogenic pulmonary edema. We therefore highlight the role of self-catheterization in continent urinary diversion otherwise severe complications can occur such as bladder stones or renal failure. Another point to emphasize is the absence of cognitive disorders so the patient can ensure an intermittent self-catheterization.

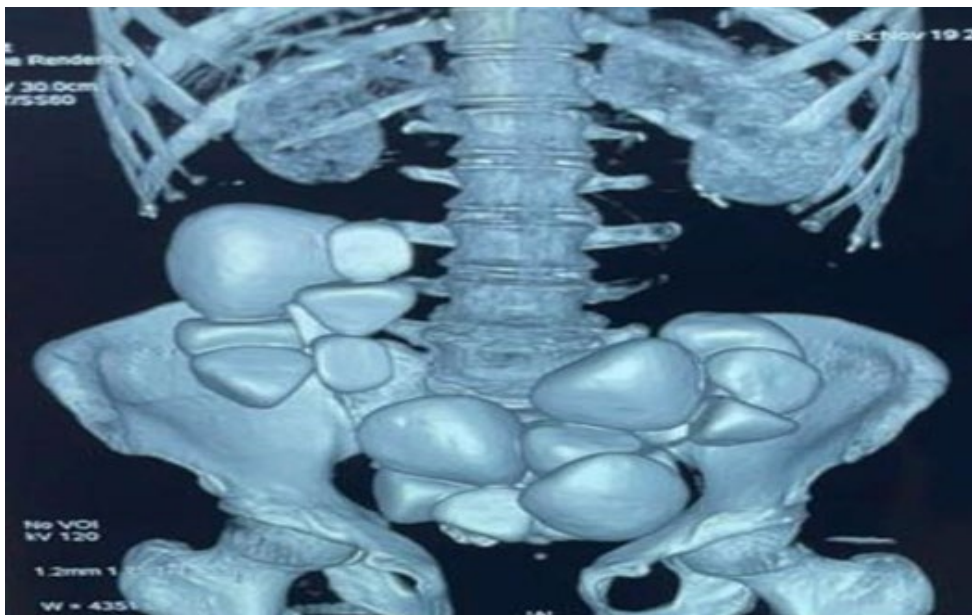


Figure 1: CT-Scan Showing Multiple Bladder Stones

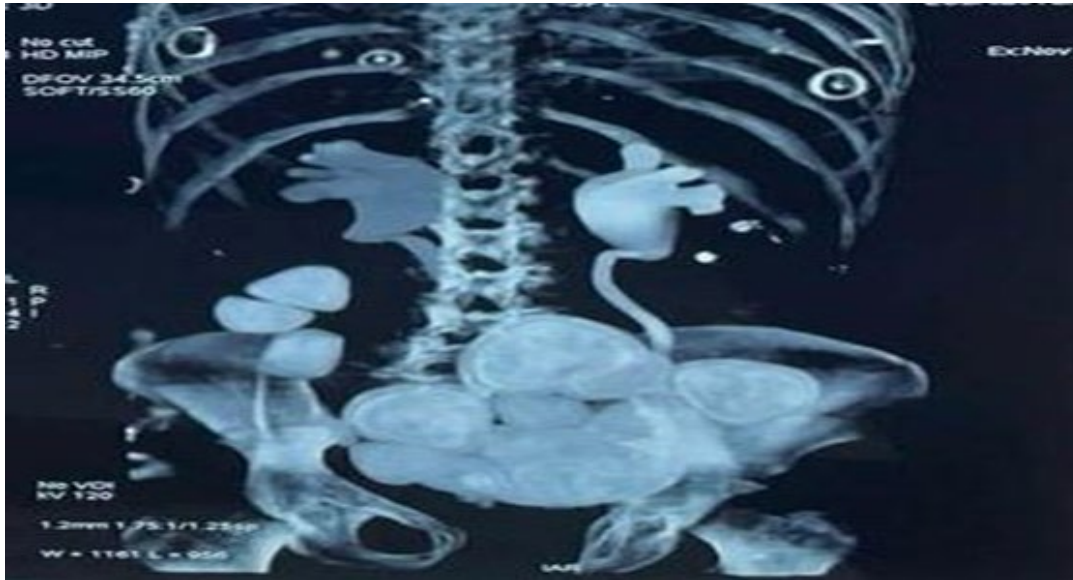


Figure 2: CT-Scan Showing Bilateral Pyelocaliceal Dilation

References

1. Quinlan, D. M., Leonard, M. P., Brendler, C. B., Gearhart, J. P., & Jeffs, R. D. (1991). Use of the Benckroun Hydraulic Valve as A Catheterizable Continence Mechanism. *The Journal of Urology*, 145(6), 1151–1155.

Copyright: © 2024 Jaafar Fouimtizi, et al. This is an open-access article distributed under the terms of the Creative Commons Attribution License, which permits unrestricted use, distribution, and reproduction in any medium, provided the original author and source are credited.