

Complications Associated with Oocyte Retrieval: An Unusual Case of Hematuria and Recurrent Urinary Retention

Jennifer W H Wong* and Ian A Oyama

Department of Obstetrics, Gynecology, and Women's Health, John A. Burns School of Medicine, University of Hawaii, Honolulu, Hawaii, United States

*Corresponding author

Jennifer WH Wong, MD. Department of Obstetrics, Gynecology, and Women's Health, John A. Burns School of Medicine, University of Hawaii, 1319 Punahou Street Suite #824 Honolulu, Hawaii, 96826; Phone: (808) 203-6532; Fax: (808) 955-2174; E-mail: jwhwong@hawaii.edu

Submitted: 09 Jan 2019; Accepted: 27 Jan 2019; Published: 14 Feb 2019

Abstract

Background: Complications associated with oocyte retrieval include ovarian hyperstimulation syndrome, ovarian torsion, infection, bleeding, and even acute urinary retention.

Case: A 29 year old female presented to the emergency department for dizziness and syncope following oocyte retrieval and was admitted for ovarian hyperstimulation syndrome. Her urinary catheter was obstructed by blood clots and relieved with bladder irrigated. The catheter was removed after twenty-four hours, and she was able to void spontaneously. Four days after discharge, she returned for urinary retention. She underwent cystoscopy and 10cc of blood clots was evacuated. The bladder appeared normal without intravesicular bleeding, and she was discharged home. Twelve hours later, the patient returned for urinary retention. Another cystoscopy was performed and 150cc of blood clots was evacuation. Her symptoms resolved.

Conclusion: Hematuria and urinary retention are rare but serious complications of oocyte retrieval. Management options include a urinary catheter, bladder irrigation, urologic imaging, and cystoscopy.

Keywords: Fertilization in vitro, Hematuria, Oocyte Retrieval, Ovarian Hyperstimulation Syndrome, Urinary Retention.

Introduction

The incidence of in vitro fertilization and oocyte donation has increased rapidly in recent years. Over 20,000 pregnancy attempts using donated oocytes or embryos are initiated each year in the United States [1]. While oocyte donation is a very effective method of treating infertility and is generally considered safe, it is not completely without complications.

Complications associated with oocyte donation can be both short- and long-term, including psychological harm and an unknown effect on future ovarian reserve. Acute complications are attributed to controlled ovarian stimulation, oocyte retrieval, and anesthesia [2]. Common minor complaints include nausea, bloating, and lower abdominal tenderness. The incidence of serious complications is approximately 0.7% [3,4] and include ovarian hyperstimulation syndrome, ovarian torsion, ruptured ovarian cyst, infection, and hemorrhage [2-4]. We present an unusual case of hematuria and recurrent urinary retention after oocyte retrieval.

Case

A healthy 29 year old gravida-0 oocyte donor presented to the emergency department for dizziness and syncope after ultrasound-

guided transvaginal oocyte retrieval. The patient was unable to ambulate so a urinary catheter was inserted, followed by drainage of bloody urine. Vital signs were stable. Complete blood count and electrolytes were normal, except for slightly decreased hemoglobin at 9.6g/dl. Pelvic ultrasound revealed 12cm ovaries bilaterally, a moderate amount of free fluid in Morrison's pouch, and a very distended bladder with an intravesicular mass consistent with a blood clot (Figure 1). The catheter was irrigated, and the blood clot was evacuated with resolution of the intravesicular mass on ultrasound. The patient was admitted for ovarian hyperstimulation syndrome.

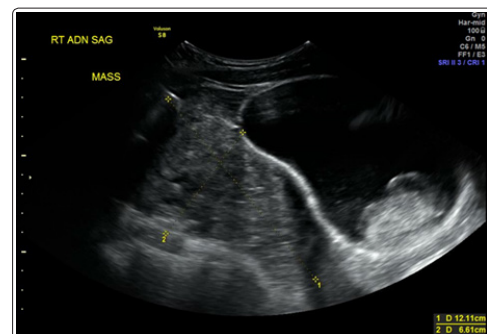


Figure 1: Pelvic ultrasound showing a 12cm right ovary and a distended bladder despite urinary catheter with an intravesicular blood clot (astrix)

The following day, the patient was tachycardia with orthostatic hypotension. Her hemoglobin dropped to 7.3g/dl, and she was transfused 2 units of packed red blood cells. Computerized tomography revealed a moderate amount of hemoperitoneum without extravasation of contrast from the bladder. Urogynecology was consulted and was reassured that urine was not leaking into the abdomen. Thus, the catheter was discontinued after twenty-four hours, and the patient was discharged on hospital day three.

Four days later, the patient presented to the emergency department for acute urinary retention. A urinary catheter was inserted and drained 300cc of bright red blood. She underwent cystoscopy, and 10cc of blood clots was evacuated from the bladder. The bladder appeared normal without active intravesicular bleeding. The patient was able to void spontaneously and was discharged home.

Twelve hours later, the patient returned to the emergency department with the same complaint of urinary retention. A urinary catheter was inserted but unable to drain. She underwent a second cystoscopy with evacuation of 150cc of blood clots. Again, the bladder appeared normal with non-bloody jets from the ureteral orifices. The patient was monitored for twelve hours postoperatively and was able to void spontaneously. Her urine remained clear, and she was discharged home with resolution of her symptoms.

Summary and Conclusion

To date, there are only a few cases of hematuria with urinary retention after oocyte retrieval in the literature. Our case is the first report of recurrent urinary retention after oocyte retrieval. In 2011, Jayakrishnan et al. reported a case of oocyte retrieval leading to massive hematuria, obstructive urinary retention, and hemodynamic instability. A bladder pseudoaneurysm was diagnosed on cystoscopy and cauterized [5]. This patient had a clear source of intravesicular bleeding. In contrast, our patient's two cystoscopies were negative, and the source of her intravesicular bleeding remains unclear. It is possible that our patient's ovarian hyperstimulation syndrome contributed to the severity of her hematuria since ovarian hyperstimulation syndrome results in increased vascular permeability and leaking. No studies have been performed on the effect of ovarian hyperstimulation syndrome on vesicular vasculature.

Occasionally, aspiration needles will transverse the bladder during the process of follicular puncture. Given the minute diameter of the needle, the bladder puncture commonly goes unrecognized, and the bladder heals spontaneously without intervention [6]. However, in cases of severe hematuria causing urinary retention, the ideal management is unknown. Conservative management with a urinary catheter and bladder irrigation should be first attempted. Three reported cases of hematuria and urinary retention after oocyte retrieval were successfully treated with bladder irrigation and urinary catheter placement for one to four days [4,7,8]. Our patient's urinary retention was initially responsive to conservative management, and then her recurrence of acute urinary retention prompted our decision to perform cystoscopy for both diagnostic and therapeutic purposes. Cystoscopy and urologic imaging can be considered as the next reasonable steps for urinary retention refractory to conservative management.

In conclusion, hematuria and urinary retention are rare but serious complications of oocyte retrieval. Although the prevalence of oocyte donations and retrievals continue to rise, there remains a

paucity of knowledge regarding procedural complications and management of these complications. Additional studies are needed on the pathophysiology and management of acute urinary retention after oocyte retrieval.

Acknowledgements

We would like to thank the Kapiolani Medical Center for Women and Children in Honolulu, Hawaii for their dedication to patient care. Many thanks to all of the physicians and healthcare providers who care for these patients.

References

1. Centers for Disease Control. Assisted Reproductive Technology: Fertility Success Rates Report 2014. US Department of Health and Human Services: Atlanta, GA. 2016.
2. Practice Committee of the American Society for Reproductive Medicine; Practice Committee of the Society for Assisted Reproductive Technology (2014) Repetitive Oocyte Donation: A Committee Opinion. *Fert Steril* 102: 964-966.
3. Maxwell KN, Cholst IN, Rosenwaks Z (2008) The Incidence of both Serious and Minor Complications in Young Women Undergoing Oocyte Donation. *Fert Steril* 90: 2165-2171.
4. Sauer MV (2001) Defining the Incidence of Serious Complications Experienced by Oocyte Donors: A Review of 1000 Cases. *Am J Obstet Gynecol* 184: 277-278.
5. Jayakrishnan K, Raman VK, Vijayalakshmi K, Baheti S, Nambiar D (2011) Massive Hematuria with Hemodynamic Instability-Complication of Oocyte Retrieval. *Fertil Steril* 96: e22-e24.
6. Alvarez C, Sanchez I, Martinez-Moya M (2012) Bladder Injury after Transvaginal Oocyte Retrieval in IVF Cycles: A Prospective Study. *Hum Reprod* 27.
7. Modder JM, Kettel LM, Sakamoto K (2006) Hematuria and Clot Retention after Transvaginal Oocyte Aspiration: A Case Report. *Fert Steril* 86: 720.e1-2.
8. Perfetto CO, Milki AM (2012) Diagnosis and Management of Bladder Hematoma after Oocyte Retrieval. *Fert Steril* 97: S10-S11.

Copyright: ©2019 Jennifer WH Wong. This is an open-access article distributed under the terms of the Creative Commons Attribution License, which permits unrestricted use, distribution, and reproduction in any medium, provided the original author and source are credited.