

## Comparison of General and Regional Anesthesia in Morbidly Obese Patient: Case Report

Maja Pesic<sup>1\*</sup>, Ivan Ivanovski<sup>2</sup>, Katarina Klican-Jaic<sup>3</sup>, prim Josip Kovac<sup>4</sup> and doc Marinko Vucic<sup>5</sup>

<sup>1</sup>Department of anesthesiology, intensive care and pain management, Sisters of Mercy University Hospital in Zagreb, Croatia

<sup>2</sup>Department of anesthesiology, intensive care and pain management, Sisters of Mercy University Hospital in Zagreb, Croatia

<sup>3</sup>Department of anesthesiology, intensive care and pain management, Sisters of Mercy University Hospital in Zagreb, Croatia

<sup>4</sup>Department of anesthesiology, intensive care and pain management, Sisters of Mercy University Hospital in Zagreb, Croatia

<sup>5</sup>Department of anesthesiology, intensive care and pain management, Sisters of Mercy University Hospital in Zagreb, Croatia

### \*Corresponding author:

Dr. Maja Pesic, Department of anesthesiology, intensive care and pain management, Sisters of Mercy University Hospital in Zagreb, Croatia, Address: Zagorska 62, Tresnjevka, Zagreb, Tel: +385989103005; E-mail: majapesic1980@gmail.com

Submitted: 27 Apr 2018; Accepted: 07 May 2018; Published: 11 May 2018

### Abstract

Obese patients and weight related health problems represent a great challenge for modern anesthesiologists to find most adequate and optimal anesthesiology technique. We would like to present a case of morbidly obese patient scheduled for flexible ureterorenoscopy and laser lithotripsy operation as treatment for nephrolithiasis at our urology clinic. Patient was a morbidly obese woman with BMI of 57 kg/m<sup>2</sup>, with history of asthma; diabetes mellitus type II, arterial hypertension and hypothyreosis. Our case is specific because this patient had the same operation twice in two month period, first operation was done in general endotracheal anesthesia, and second one in regional spinal anesthesia. We show the preoperative, intraoperative and postoperative clinical course of the patient for both anesthetics. Patient clinical course was much better and she spent less time in hospital with spinal anesthesia. We think that spinal anesthesia would be a better choice in morbidly obese patient, off course, taking in to account indications and contraindications for it.

**Keywords:** Morbidly Obese, General Endotracheal Anesthesia, Spinal Anesthesia, Flexible Ureterorenoscopy

### Abbreviations

WHO- World Health Organization  
 BMI-body mass index  
 FVC-forced vital capacity  
 FEV-forced expiration volume  
 CVC-central venous catheter  
 PCNL- percutaneous nephrolithotomy  
 DM2-diabetes mellitus type 2  
 CXR-chest x-ray  
 FURS-flexible ureterorenoscopy  
 PIP- peak inspiratory pressure

### Introduction

Obesity is a disease that is affecting almost every human organ system and causing chronic medical diseases. Diseases such systemic hypertension, diabetes mellitus, obstructive sleep apnea syndrome, non-alcoholic steatohepatitis and metabolic syndrome are just some of the most common comorbidities associated with obesity [1-3]. In adults, the body mass index, defined as ratio of body weight in

kilogram and squared body height in meter, has been used as the comparative measure of obesity. WHO define overweight as BMI = 25–29 kg/m<sup>2</sup>, obese BMI = 30–39 kg/m<sup>2</sup> and morbidly obese as BMI 40 kg/m<sup>2</sup>. Evidence that obesity is worldwide health problem and pandemic are the WHO figures about its incidence and prevalence which is constantly rising in western countries in the last few decades [4]. Having in mind those facts there is greater chance nowadays to have an obese patient scheduled for surgery. Anaesthesiologists should be able to make an evidence based decision about selecting the anaesthetic technique that carries the least risk for the patient [5, 6]. Unfortunately there is still not enough research to make well establish scientific facts on anesthesia in obese patient [5]. One of the problems that an anesthesiologist has to solve is a choice between regional and general anesthesia. Regional anaesthesia avoid generic difficulties usually faced with general anaesthesia such as difficult intubation, perioperative respiratory insufficiency, cardiopulmonary depression and postoperative nausea and vomiting but it can be used only in selected operative procedures [1-6]. However, regional anaesthesia is generally believed to be associated with a great rate of unsuccessful blocks [7, 8]. Spinal anesthesia is one of the modalities of regional anesthesia, usually placed in to a subgroup of neuroaxial anesthesia together with epidural anesthesia.

Flexible ureterorenoscopy and laser lithotripsy operation is a type of treatment for nephrolithiasis. It is usually done in dorsal lithotomy position with 15% Trendelenburg and it is possible to be performed in neuroaxial (spinal) anesthesia and general anesthesia [9].

### Materials and Methods

We are presenting the case of morbidly obese female patient who was scheduled for flexible ureterorenoscopy and laser lithotripsy operation as treatment for nephrolithiasis at our urology clinic. Patient is a morbidly obese woman with BMI of 57 kg/m<sup>2</sup>. She has a history of diabetes mellitus type II for 4 years, asthma for 12 years, and arterial hypertension for 20 years and hypothyroidism for 5 years after thyroidectomy and parathyroidectomy. She has also done PCNL, cholecystectomy and appendectomy in earlier life. All anesthetics were without complication except in 2011. When she had bronchospasm after PCNL in general anesthesia. She was prescribed with Losartan plus, Lacipil, Nixar for arterial hypertension; Montelukast and Alvesco for asthma; Euthyrox and Rocatrol for hypothyroidism and parahypothyroidism; and Siofor for DM2. No allergies were noted in her medical history. Our patient had the same operation twice in two month period. First operation was in May 2017 when the operation was done in general endotracheal anesthesia, and second one in July 2017 done in regional spinal anesthesia.

First operation, as was said before, was done in general anesthesia. In preoperative assessment pulmonologist and spirometry was normal regarding her asthma even though she didn't have any signs of exacerbation. She didn't feel any shortness of breath or heavy breathing, and her lung sounds were normal and clear of any wheezing. She also tolerated supine position very well. Spirometry came good; FVC 92%, FEV1 97%, FEV1/FVC 0,871, SaO<sub>2</sub> 96%. Pulmonologist constituted that there are no pulmonary obstacles for the operation, prescribed continuation of her therapy and premedication with 40 mg of SoluMedrol IV. Patient also received CVC in right v. jugularis interna with confirmation of the position with CXR. As a premedication, patient received Fragmin 7500 i.j.sc. At 22:00h night before operation and SoluMedrol 40 mg IV. 1 h and Dormicum 7.5 mg PO 1h before the op. Balanced intravenous-inhalation anesthesia was used. After preoxygenation for 10 min we succeeded to achieve the maximum SaO<sub>2</sub> of 96%. Anesthesia was induced with Propofol, Sufentanyl and Esmeron and was continued with Sevoflurane at MAC0, 8% and Esmeron on perfusion of 12, 5 ml/h. Tracheal tube size of 7,5mm inner diameter and normal laryngoscope was used, and intubation went without problems. Volume control mechanical ventilation was started. After the induction SaO<sub>2</sub> fell to 92-93% and stopped on that values only after recruitment maneuvers and rising of FiO<sub>2</sub> on 100%, although high inspiratory peak (PIP>35mmH<sub>2</sub>O) pressures were measured. 30 min in the operation, around 10 min after Trendelenburg position patient started to denature and PIP started to rise, with EtCO<sub>2</sub> curve and auscultation of the lung suggesting bronchospasm. We were able to stop and reverse the problem with application of 260 mg of Aminophyllin IV. And inhalation of Ventolinum. Operation was finished 30 min later. During operation we were able to keep the SaO<sub>2</sub> around 92%, EtCO<sub>2</sub> 4, 0 kPa and PIP below 35cmH<sub>2</sub>O, but EtCO<sub>2</sub> curve and physical signs were still suggesting for bronchospasm. We used inhalation of Ventolin again just prior to application of Bridion for decarboxylation. Extubation went without problems but patient was received in High Care unit for better monitoring because of heavy breathing and whizzing on auscultation. She recovered completely

in next 24h with only her standard therapy, was released to her of room next day and home the day after. After the operation, patient received Ketonal 100mg, Perfalgan 1g and Tramadol 100mg in first 24 h, additional pain therapy wasn't necessary. She spent 48h in hospital postoperatively. Patient was discharged from hospital with JJ catheter because residual concrement in right kidney.

Second FURS operation was in November. The patient didn't have any pulmonary symptoms; she received the same premedication as in first operation. CVC was also inserted as in first operation prior to surgery, with negative ECHO sliding technique as test for pneumothorax. This time spinal anesthesia was applied. We used 25G Quincke needle on a level of L3/L4. After appearance of liquor a mixture of 1, 5 ml of 0, 5% Chirocaine, 5 mcg Sufentanyl and 0, 6 ml of 40% Glucose was administered intrathecally. The spinal space was found after third attempt. Patient was immediately laid down and was left in supine position for 15 min for fixation of the block. Surgery started 20 min after the spinal block. There was no pain or any uncomfortable feeling. Her SaO<sub>2</sub> fell from 96% to 92% after lithotomy position with O<sub>2</sub> application on nasal catheter. SaO<sub>2</sub> was stable through the rest of the operation on 97%. The operation was of similar length, it was over 30 min after. Patient was respiratory and hemodynamically stable with PIP <25cmH<sub>2</sub>O. She was transferred to her room immediately after surgery. She received Ketonal 100mg one hour after surgery, and did not request any more analgesics. Patient was discharged home next day, after removal of CVC.

### Results

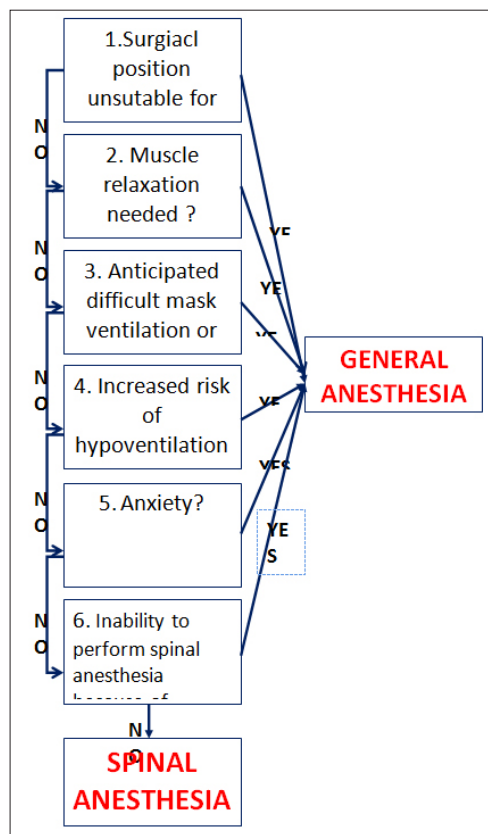
Obese patients have a higher incidence of hypoxia and respiratory events than patients with normal BMI because these patients desaturate more quickly during apneic periods. The anticipation and management of respiratory problems is critical [10-12]. Premedication of the obese patient should ideally allow anxiolysis without abolishing airway reflexes or preventing patient cooperation prior to induction of general anesthesia [13, 14]. The following factors may lead to a choice of general anesthesia with assisted or controlled ventilation: surgical procedure, positioning, relaxation, anticipated difficult mask ventilation or intubation, increased risk of hypoventilation/hypercapnia, anxiety, redundant tissue [2]. Surgical procedure and surgeon need for patient relaxation is the first criteria that anesthesiologist should have in mind when choosing the method of anesthesia because a lot of operations are not possible to perform in spinal anesthesia or require muscle relaxation to be performed [8]. Second, positioning of the patient can cause respiratory insufficiency because of decreased respiratory tolerance for supine/ head-down positioning or it could be too uncomfortable for him [10-13, 15]. Difficult airway management and expected hypercapnia in patients with OSAS or obesity hypoventilation syndrome should be in mind when decision about the type of anesthesia is being made [14]. If we are suspecting those problems, our opinion, as is the opinion of experts on this topic, is that it would be prudent to intubate in a controlled manner at the beginning of the case rather than after problems develop [3, 16-18]. Anxiolytics and sedatives can lead to hypoventilation and/or airway compromise so spinal anesthesia should probably be avoided in very anxious people [19]. The technical difficulty with placement of local, regional, or neuraxial anesthesia is still a common problem among anesthesiologists causing usually to favor the general anesthesia but limited but existing data show that with appropriate equipment and ultrasound guidance it can be easily overcome [20-23]. We can see in our case report that spinal anesthesia was much better choice for this patient. (Table 1.)

**Table 1: Comparison of general vs. regional anesthesia outcome in our case report**

	General anesthesia	Spinal anesthesia
Patient satisfaction	lower	higher
Postoperative hospital time	Longer (48h)	Shorter (28h)
Postoperative high care unit	YES	NO
Respiratory complications	YES	NO
Need for respiratory drugs	More	Less
Postoperative analgesia	YES	NO
Need for opioid analgesia postoperavily	YES	YES
Full recovery	YES	YES

First the operation was suitable for spinal anesthesia, and it did not require any muscle relaxation. We were worried that the positioning of the patient would cause too much uncomforted and/or lead to hypoventilation in case of spinal anesthesia but as we can see we were wrong [21, 22]. We think that general anesthesia caused bigger

drop in FRC and right to left shunt causing respiratory insufficiency and triggering bronchoconstriction. Drop of FRC and right to left shunt in general anesthesia and prone/ Trendelburg position is already described in literature [12-15]. Although spinal space was found at third attempt it didn't caused any major inconvenience or pain. We can also see that intraoperative and postoperative course was much better with spinal anesthesia. Patient hospital stay after spinal anesthesia was 48h shorter, she received no additional drugs for respiratory stabilization and she received less postoperative analgesics. Patient recovery was much better and faster in surgery done in spinal anesthesia. Because this patient was much more satisfied with spinal anesthesia, her clinical course was much better and she spent less time in hospital, we think that spinal anesthesia would be a better choice in morbidly obese patient, off course, taking in to account indications and contraindications for it. As at the time there are not enough research on this subject we think that high-number randomize multicentre studies are a must [8]. We think that uniform form of recommendations should be made at the moment, with existing evidence, to stimulate research and bring awareness on this subject. Our results are in accordance with literature and expert's opinion at the date [8]. We created small algorithm based on researched materials to help with decision making on the type of anesthesia in morbidly obese patient. (Picture 1.)



**Picture 1:** Decision algorithm for general vs. spinal anesthesia in morbidly obese

**Acknowledgement**

Production of this paper was not funded by any company or grant. We thank to our colleges at our urology clinic and anesthesiology department for support.

## References

1. Adams JP, Murphy PG (2000) Obesity in anaesthesia and intensive care. *Br J Anaesth* 85: 91-108.
2. Huschak GI, Busch T, Kaisers UX (2013) Obesity in anesthesia and intensive care. *Best Pract Res Clin Endocrinol Metab* 27: 247-260.
3. Roman Schumann (2018) Anesthesia for the obese patient. Obesity and overweight (2017).
4. Dindo D, Muller MK, Weber M, Clavien PA (2003) Obesity in general elective surgery. *Lancet* 361: 2032-2035.
5. Bluth T, Pelosi P, de Abreu MG (2016) The obese patient undergoing nonbariatric surgery. *Curr Opin Anaesthesiol* 29: 421-429.
6. Sprung J, Bourke DL, Grass J, Hammel J, Mascha E, et al. (1999) Predicting the difficult neuraxial block: a prospective study. *Anesth Analg* 89: 384-389.
7. Agnes M Lamou, Ashraf S Habib (2016) Managing anesthesia for cesarean section in obese patients: current perspectives. *Local Reg Anesth* 9: 45-57.
8. Shaikh AH, Khalid SE, Zaidi SZ (2008) Ureteroscopy under spinal versus general anaesthesia: morbidity and stone clearance. *J Coll Physicians Surg Pak* 18: 168-171
9. Littleton SW (2012) Impact of obesity on respiratory function. *Respirology* 17: 43-49.
10. Kabon B, Nagele A, Reddy D, Chris Eagon, James W Fleshman, et al. (2004) Obesity decreases perioperative tissue oxygenation. *Anesthesiology* 100: 274-280.
11. Ladosky W, Botelho MA, Albuquerque JP Jr (2001) Chest mechanics in morbidly obese non-hypoventilated patients. *Respir Med* 95: 281-286.
12. Joshi GP, Ahmad S, Riad W, Eckert S, Chung F, et al. (2013) Selection of obese patients undergoing ambulatory surgery: a systematic review of the literature. *Anesth Analg* 2013; 117: 1082-1091.
13. Cartagena R (2005) Preoperative evaluation of patients with obesity and obstructive sleep apnea. *Anesthesiol Clin North America* 23: 463-478.
14. Pelosi P, Croci M, Calappi E, Mulazzi D, Cerisara M, et al. (1996) Prone positioning improves pulmonary function in obese patients during general anesthesia. *Anesth Analg* 83: 578-583.
15. A. De Jong, N. Molinari, Y. Pouzeratte, D. Verzilli, G. Chanques, et al. (2015) Difficult intubation in obese patients: incidence, risk factors, and complications in the operating theatre and in intensive care units. *BJA: British Journal of Anaesthesia* 114: 297-306.
16. Bond A (1993) Obesity and difficult intubation. *Anaesth Intensive Care* 21: 828-830.
17. Brodsky JB, Lemmens HJ, Brock-Utne JG, Vierra M, Saidman LJ (2002) Morbid obesity and tracheal intubation. *Anesth Analg* 94: 732-736.
18. J Ingrande, H J M Lemmens (2010) Dose adjustment of anaesthetics in the morbidly obese *British Journal of Anaesthesia* 105: 16-23.
19. de Filho GR, Gomes HP, da Fonseca MH, Hoffman JC, Pederneiras SG, et al. (2002) Predictors of successful neuraxial block: a prospective study. *Eur J Anaesthesiol* 19: 447-451.
20. McCulloch WJ, Littlewood DG (1986) Influence of obesity on spinal analgesia with isobaric 0.5% bupivacaine. *Br J Anaesth* 58: 610-614.
21. Regli A, von Ungern-Sternberg BS, Reber A, Schneider MC (2006) Impact of spinal anaesthesia on peri-operative lung volumes in obese and morbidly obese female patients. *Anaesthesia* 61: 215-221.
22. Taivainen T, Tuominen M, Rosenberg PH (1990) Influence of obesity on the spread of spinal analgesia after injection of plain 0.5% bupivacaine at the L3-4 or L4-5 interspace. *Br J Anaesth* 64: 542-546.

**Copyright:** ©2018 Maja Pestic, et al. This is an open-access article distributed under the terms of the Creative Commons Attribution License, which permits unrestricted use, distribution, and reproduction in any medium, provided the original author and source are credited.