

Case Report

Journal of Pediatrics & Neonatal Biology**Challenges in Managing a Large Metallic Foreign Body in Oropharynx of a Child: A Case Report**Manisha Paneru^{1*}, Ajit Nepal² and Binam Ghimire³¹Lecturer, Department of Otorhinolaryngology, Head & Neck Surgery, Patan Academy of Health Sciences²Professor, Department of Otorhinolaryngology, Head & Neck Surgery, Patan Academy of Health Sciences³Lecturer, Department of Anesthesiology and Critical care, Patan Academy of Health Sciences***Corresponding Author**

Manisha Paneru, Lecturer, Department of Otorhinolaryngology, head and neck surgery, Patan Academy of Health Sciences.

Submitted: 2023, July 12; **Accepted:** 2023, Aug 14 ; **Published:** 2023, Aug 16**Citation:** Paneru. M., Nepal. A., Ghimire, B. (2023). Challenges in Managing a Large Metallic Foreign Body in Oropharynx of a Child: A Case Report. *J Pediatr Neonatal Biol*, 8(3), 247-249.**Abstract**

Foreign Body (FB) ingestion is common in pediatric population. Curious nature and tendency to put objects in mouth are the key factors for its higher prevalence among them. Most of the ingested foreign bodies pass through the entire alimentary tract uneventful; however some require surgical interventions for its removal.

Keywords: Aero-Digestive Tract, Children, Foreign Body, Oropharynx**1. Introduction**

Foreign body Ingestion is fairly common among the pediatric population; as they tend to be very curious and have tendency to put objects in mouth [1]. These ingested foreign body in upper aerodigestive tracts accounts for significant i.e. around 30 % of out-of-hour referrals to ENT surgeons [2]. Children of 5 years of age and younger are responsible for 75% of all FB ingestions, and 20% of children 1 to 3 years of age are reported to have ingested some kind of foreign body in their life [2-4].

Although many ingested items are relatively innocuous and pass uneventfully through the entire gastrointestinal tract and eventually through the feces, some FBs result in its impaction and can cause grievous harm necessitating surgical intervention [5].

Prompt diagnosis and early intervention of foreign body aerodigestive tract is crucial to prevent morbidity (aerodigestive tract stricture, esophageal perforation) and mortality [6].

Objects lodged at or above the cricopharynx can be removed via direct laryngoscopy thus avoiding the need of hypopharyngoscopy further. However, rigid or flexible endoscopy remains the choice of intervention for removal of objects lodged below cricopharynx and when laryngoscopy is unsuccessful in removing objects lodged above this area [7].

2. Case Report

A 13-month-old female child presented to the Emergency Department of Patan Academy of Health Sciences (PAHS)

Nepal, with an alleged history of accidental ingestion of large circular metallic object 1.5 hours back while playing with the same following which child had excessive drooling and noisy breathing. On physical examination, the child's pulse was 120/min, BP (Blood Pressure) 70/50 mm of Hg, and respiratory rate of 40/min. She showed signs of inspiratory stridor and decreased air entry while lying flat. A foreign body in aerodigestive tract was suspected; thus, X-ray soft tissue neck (Anterior-Posterior (AP) and lateral) was requested which revealed a radio-opaque, vertically oriented circular foreign body in the region of oropharynx and partly extending up to naso-hypopharynx. (Figure 1A and B). Physical examination revealed no other significant abnormalities.

Thus, rigid endoscopy (hypopharyngoscopy) was subsequently planned under general anesthesia. In the operating room child was sedated and while intubating, huge metallic container was seen which was occupying whole of the oropharynx and inferior part of nasopharynx with sharp margin facing anteriorly causing partial airway obstruction.

Intubation was difficult due to large size of foreign body. Further, downward manipulation was also risky due to risk of falling down to hypopharynx and getting flipped to cause the complete airway obstruction. Tracheostomy set was also kept ready. Eventually after direct laryngoscopic visualization and careful manipulation, FB was removed by Freer's elevator and Magill's forceps without any trauma to soft palate or posterior pharyngeal wall. However, Uvula appeared grossly edematous. On inspecting the foreign body, it was a huge (2.5x2.5cm)

metallic hollow circular, 0.7 cm deep container having sharp edge and mirror on opposite surface (Figure 2A &B). Child was immediately intubated after the procedure to secure the airway and was admitted to the pediatric intensive care unit. The

following day, child was asymptomatic and was transferred to pediatric ward. She was discharged on third postoperative day and was doing absolutely fine on scheduled follow up after a week.

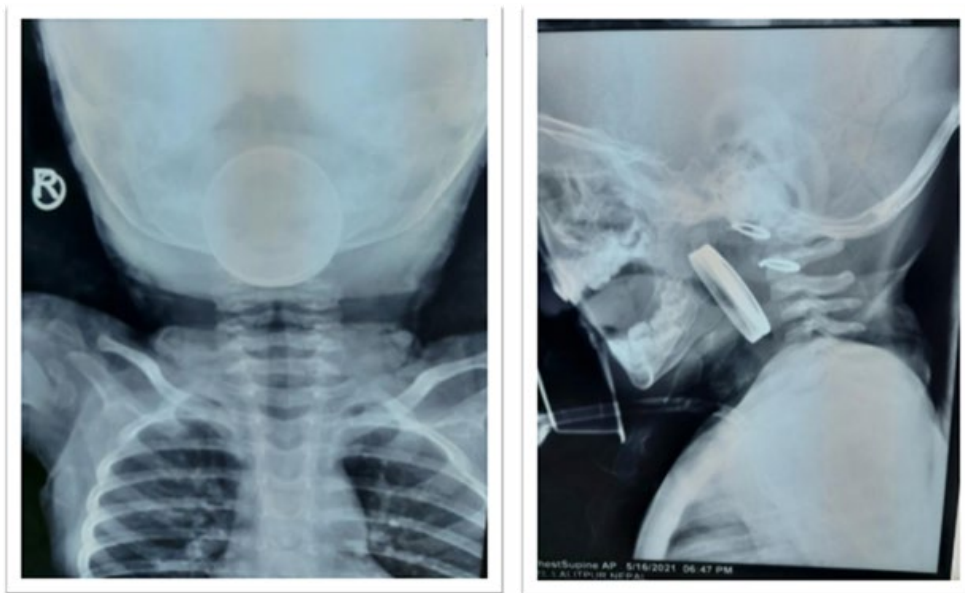


Figure 1: (A&B): X-ray Soft Tissue Neck Ap And Lateral View Showing Radio Opaque Foreign Body

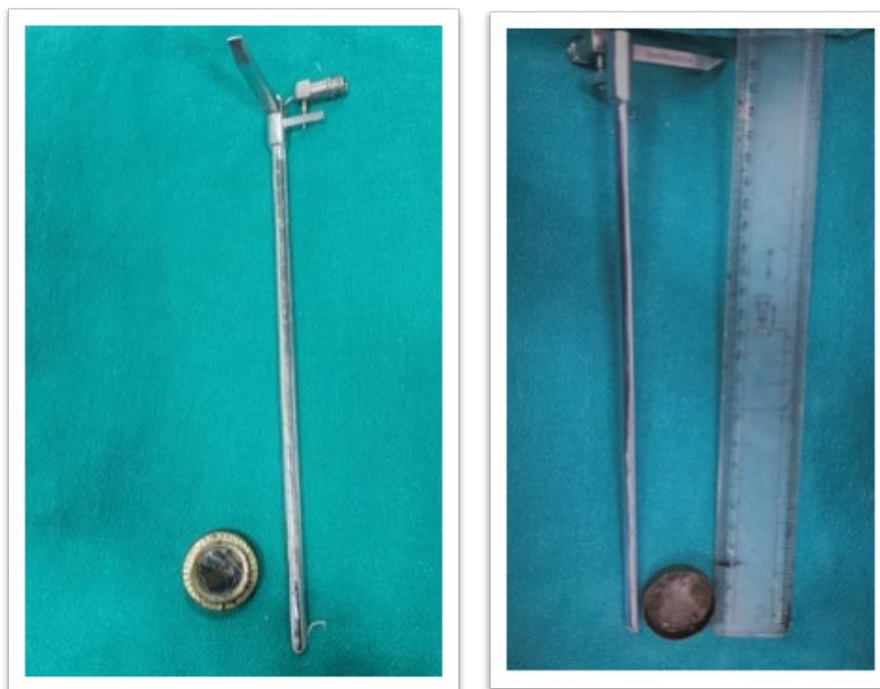

Figure 2: (A&B); Foreign Body, Metallic Container (2x2cm) With Mirror and Sharp Edge Opposite Surface.

3. Discussion

Lodged foreign body in aero-digestive tract of children is one of the frequently observed conditions in pediatric emergency department. Its incidence is equal in both the genders [8]. Children can swallow myriad of objects due to easy accessibility of objects like coins, toys, batteries and jewelries in households.

The vast majority of smaller smooth ingested foreign bodies will

pass spontaneously via gastrointestinal tract without any damage. However, certain foreign bodies may lodge in areas of normal narrowing or curvatures of esophagus most commonly in upper esophagus i.e., cricopharynx [9]. Among this FB that comes to clinical attention, 80%-90% pass through gastrointestinal tract (GI) without causing any harm. Another 10%-20% require a careful manipulation for endoscopic removal, with <1% of foreign objects require open surgical exploration [5].

Usually FB ingestion/ inhalation presents with excessive drooling, poor feeding, dysphagia, vomiting and occasionally cough, stridor and wheezing. Respiratory symptoms secondary to esophageal foreign body is common presentation, which is likely to be seen in a case where FB are sharp, irregular and of large size [10]. In our case, due to the large size of metallic container, it got lodged in the oropharynx as the child was not able to swallow it completely. The foreign body showed sharp edge towards the hollow surface. Notably, the sharp or jagged foreign body carries significant morbidity and mortality as they are responsible for 15% to 35% of perforations following ingestion [11]. Mostly, lodged foreign body in aero-digestive tract of child is suspected when one refuses to eat or has excessive drooling and noisy breathing. However, at times there will be more straight forward diagnosis when family member reports to have witnessed the ingestion of the foreign body like in this case.

Child suspected with ingested foreign body requires minimal laboratory investigations. Antero- posterior and lateral X-ray including neck, thorax and abdomen should be obtained in patients with the complaints of FB ingestion or suspicion of ingestion [12]. Sometimes in a suspicious case of FB ingestion/ inhalation among the unattended child, X-ray nasopharynx is also required when X-ray neck and chest is inconclusive. However, the ingested/ inhaled foreign bodies lodging in nasopharynx has rarely been reported [13]. Foreign bodies located in esophagus can be removed via flexible or rigid esophagoscopy or hypopharyngoscopy. Likewise, other techniques like Penny pincher technique, Foley catheter extraction, esophageal bougienage and removal with Magill forceps have been used for removal of esophageal foreign bodies [14]. In this case, a 13 month-old-girl presented with excessive drooling and noisy breathing with direct documented history of ingestion of a metallic container. Radiography revealed radiopaque vertically oriented circular foreign body in the region of oropharynx and hypopharynx. Under general anesthesia and direct laryngoscopy, safe removal of large circular metallic object was performed via Freer's elevator and Magill's forceps.

4. Conclusion

Foreign body ingestion is fairly common among the pediatric age group. In the absence of straight forward diagnosis witnessed by parents of the foreign body ingestion, it should be suspected in the clinical grounds when child presents with symptoms like refusal to feed, excessive drooling and noisy breathing. Prompt diagnosis and safe intervention avoids potentially grave complications among them.

References

1. Tasneem, Z., Khan, M. A. M., & Uddin, N. (2004). Esophageal foreign body in neonates. JPMA. The Journal of the Pakistan Medical Association, 54(3), 159-161.

2. Singh, N., Chong, J., Ho, J., Jayachandra, S., Cope, D., Azimi, F., ... & Wong, E. (2018). Predictive factors associated with spontaneous passage of coins: A ten-year analysis of paediatric coin ingestion in Australia. International journal of pediatric otorhinolaryngology, 113, 266-271.
3. Bekkerman, M., Sachdev, A. H., Andrade, J., Twersky, Y., & Iqbal, S. (2016). Endoscopic management of foreign bodies in the gastrointestinal tract: a review of the literature. Gastroenterology research and practice, 2016.
4. Litovitz, T. L., Klein-Schwartz, W., Rodgers Jr, G. C., Coughlin, D. J., Youniss, J., Omslaer, J. C., ... & Benson, B. E. (2002). 2001 Annual report of the American association of poison control centers toxic exposure surveillance system. The American journal of emergency medicine, 20(5), 391-452.
5. Orsagh-Yentis, D., McAdams, R. J., Roberts, K. J., & McKenzie, L. B. (2019). Foreign-body ingestions of young children treated in US emergency departments: 1995–2015. Pediatrics, 143(5).
6. Lone, S. A., Hameed, A., & Shiekh, F. A. (2021). Foreign body esophagus in a young infant. Clinical Case Reports, 9(4), 1899-1901.
7. Hernot, S., Kalra, V., Wadhwa, R., & Kaintura, M. (2019). Sharp 3-Ended Metallic Foreign Body in an Infant Hypopharynx. Indian Journal of Otolaryngology and Head & Neck Surgery, 71, 14-17.
8. Balci, A. E., Eren, Ş., & Eren, M. N. (2004). Esophageal foreign bodies under cricopharyngeal level in children: an analysis of 1116 cases. Interactive Cardiovascular and Thoracic Surgery, 3(1), 14-18.
9. Hesham A-Kader, H. (2010). Foreign body ingestion: children like to put objects in their mouth. World journal of pediatrics, 6, 301-310.
10. Pasquariello Jr, P. S., & Kean, H. (1975). Cyanosis from a foreign body in the esophagus: respiratory difficulties three months after swallowing a coin. Clinical Pediatrics, 14(3), 223-225.
11. Kountouras, J., Chatzopoulos, D., Ch, Z., Kouklakis, G., & Vrettos, M. (2001). Perforation of midpart of ileum caused by entrapment of a large, wide foreign body. Annals of Gastroenterology.
12. Gabriel, O. T., Obasa, O. T., & Osesanmi, S. S. (2014). An unusual foreign body impaction in the pharynx of a child—A case report and literature review. The Nigerian Postgraduate Medical Journal, 21(2), 193.
13. Sunkum, J. K. A. G. (2011). Nasopharyngeal foreign body in a young child. Indian Journal of Otolaryngology and Head & Neck Surgery, 63, 285-286.
14. Cetinkursun, S., Sayan, A., Demirbag, S., Surer, I., Ozdemir, T., & Arıkan, A. (2006). Safe removal of upper esophageal coins by using Magill forceps: two centers' experience. Clinical pediatrics, 45(1), 71-73.

Copyright: ©2023 Manisha Paneru, et al. This is an open-access article distributed under the terms of the Creative Commons Attribution License, which permits unrestricted use, distribution, and reproduction in any medium, provided the original author and source are credited.