

**Cauda Equina Paraganglioma: Case Report**Bekralas H<sup>1\*</sup> and Habchi N<sup>2</sup><sup>1</sup>Head of Department of Neurosurgery Bejaia Hospital, Bejaia, Algeria<sup>2</sup>Neurosurgery Department, Mustapha Pacha University Hospital, Algiers, Algeria**\*Corresponding author**

Bekralas H, Head of Department of Neurosurgery Bejaia Hospital, Bejaia, Algeria

**Submitted:** 03 Apr 2022; **Accepted:** 10 April 2022; **Published:** 28 April 2022**Citation:** Bekralas H and Habchi N (2022). Cauda Equina Paraganglioma: Case Report. *Adv Neur Neur Sci*, 5(2), 77-79.**Abstract**

Cauda equina paragangliomas are benign neuroendocrine tumors. They are rare tumors, very few cases have been reported in the literature. We report the case of a 40-year-old patient with no particular history and who has had low back pain for 3 months secondary to bilateral L5 sciatica. . The physical and neurological examination is strictly normal. The MRI shows, next to L4-L5, an oval intradural lesion in T1 and T2 isosignal, enhancing evenly after injection of gadolinium. The patient is operated on via the posterior approach; laminectomy of L4 and L5, the resection is macroscopically complete. The postoperative course is simple with disappearance of lumbosciatalgia and urinary urgency. The control MRI performed 3 months postoperatively confirms complete excision. The anatomo-pathological examination concludes with a morphological and immuno-histochemical aspect of a benign paraganglioma. Complete surgical excision remains the ideal treatment to minimize the risk of recurrence.

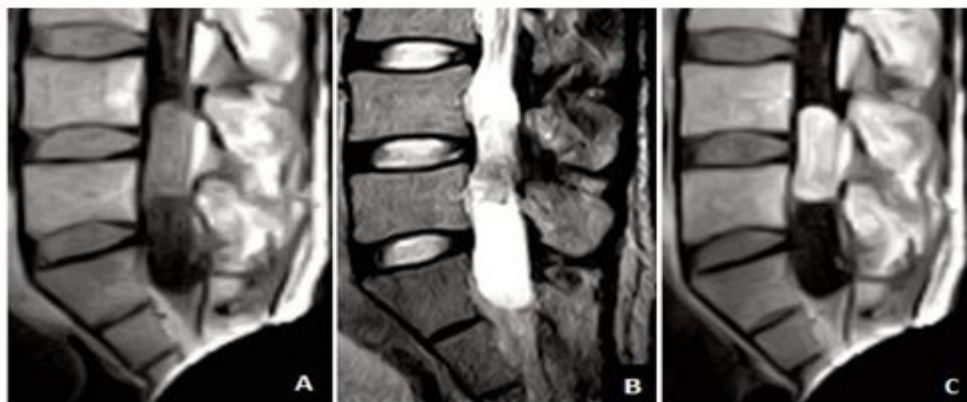
**Keywords:** Paraganglioma, Benign tumor, Filum terminal.**Introduction**

Cauda equina paragangliomas are benign neuroendocrine tumors [2, 3]. They result from the migration of cells from the neural crest to the level of the autonomic nervous system. These are rare tumours, very few cases have been reported in the literature [7, 9, 11, 15]. The reference treatment consists of complete surgical excision [7, 15].

back pain associated with bilateral L5 type sciatica for 3 months. The patient received treatment with nonsteroidal anti-inflammatory drugs and analgesics, but without significant improvement. Two months later, the appearance of urinary disorders with urgent urination is noted. The physical and neurological examination is strictly normal. The MRI shows, next to L4 and L5, an oval intradural extramedullary lesion in T1 and T2 isosignal, enhancing evenly after injection of gadolinium [Figure 1].

**Case Report**

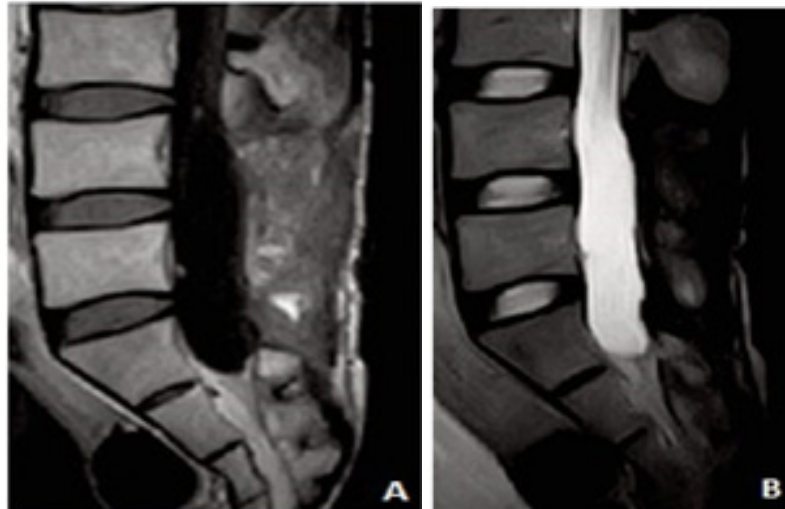
40-year-old patient, with no particular history, who has had low

**Figure 1:** Preoperative MRI showing the oval intradural lesion. A: isointense lesion on T1. B: isointense lesion on T2. C: homogeneous contrast uptake after injection of Gadolinium in T1

The patient is operated on via the posterior approach; laminectomy of L4 and L5, section of the terminal filum, excision is macroscopically complete.

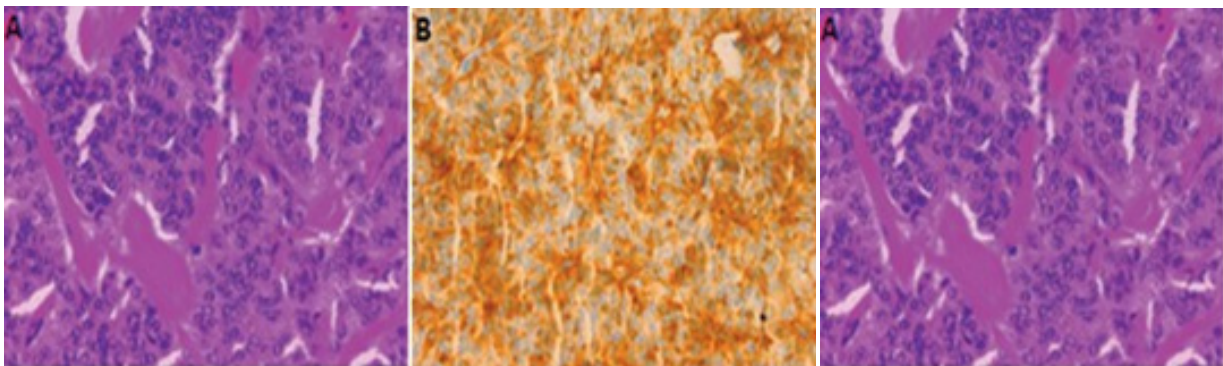
The lesion is oval with a long axis of 25 mm, encapsulated, highly

vascularized reddish developed at the expense of the filum terminale, pushing the roots laterally on each side, not invading the dura mater. The postoperative course is simple with disappearance of lumbosciatalgia and urinary urgency. Control MRI performed 3 months postoperatively confirms complete resection [Figure 2].



**Figure 2:** MRI at 3 months postoperative showing laminectomy scars, absence of tumor remnant in T1 (A) and T2 (B)

The anatomic-pathological examination concludes with a morphological and immuno-histochemical appearance of a benign paraganglioma (Fig.3).



**Figure 3:** Microscopic aspects of our patient's paraganglioma. A: Proliferation of cubo-cylindrical cells of endocrinoid architecture. Abundant vascularization (HE,  $\times 100$ ), B: Diffuse expression of chromogranin A by tumor cells ( $\times 100$ ), C: Expression of protein S100 by supratentacular cells ( $\times 100$ ).

### Discussion

Cauda equina paragangliomas are rare tumors representing 2.5 to 3.8% of cauda equina tumors [2, 11, 15]. Its incidence in the population is estimated at 0.07 per 100,000 inhabitants [6,10].

Our case concerns a young adult of 40 years. There is no difference in the distribution of this tumor according to age. Landi [10] reported a slight male predominance in his review of the literature. Cauda equina paragangliomas can be revealed by simple radiculalgia [4, 10, 15]. However, it is most often a cauda equina syndrome [9, 14, 20] like our patient. MRI confirms the diagnosis of intradural tumor, without confirming with certainty the diagnosis of paraganglioma; it is often very difficult to rule out the diagno-

sis of neuromas and ependymomas at this stage [1, 10, 17,20, 22, 23., Despite the fact that some authors retain the presence of rare calcifications as a criterion pointing towards paraganglioma [ 15]. However, the MRI aspect reported by several authors as well as in our case is that of an oval or rounded intradural lesion in T1 isosignal, taking up the contrast product homogeneously [8, 9, 10,13, 15, 16]. The diagnosis is not really established until the end of the histological and immunohistochemical study [2, 3, 7, 10]. Our therapeutic approach consists of complete surgical excision [1, 4, 5, 10, 15 19]. The difficulty of complete excision is related to the infiltrating nature of the paraganglioma often requiring the sacrifice of the supporting root [5, 15]. This complete excision considerably reduces the risk of long-term recurrence [10, 12]. On the

other hand, an incomplete excision exposes to a risk of recurrence in the first year [12, 22]. A case of dissemination in the central nervous system as well as distant metastases has also been reported [18]. The postoperative course is simple in our patient with a disappearance of lumbosciatalgia and urinary urgency.

The control MRI performed 3 months postoperatively confirms complete excision. However, long-term clinical and radiological monitoring remains essential, given the risk of recurrence [3].

## Conclusion

Cauda equina paragangliomas are benign neuroendocrine tumors. MRI diagnosis is difficult. The diagnosis of certainty is based on histological study. Complete surgical excision remains the ideal treatment to minimize the risk of recurrence.

## References

1. Agrawal, V., Rahut, M., Khan, S., & Rachana, B. (2012). Functional paraganglioma: a rare conus-cauda lesion. *Journal of Surgical Technique and Case Report*, 4(1), 43-45.
2. Ardon, H., Plets, C., Sciote, R., & Van Calenbergh, F. (2011). Paraganglioma of the cauda equina region: a report of three cases. *Surgical neurology international*, 2.
3. Corinaldesi R, Novegno f, giovenali p, lunardi t, floris R, lunardi p. Paraganglioma of the cauda equina region. *Spine J*. 2015,1,15,3, p1-8
4. Sushrut, M. F., Jagannath, L., Narasimhaiah, L., & Mishra, U. (2013). Paraganglioma of cauda equina-case report. *Journal of Orthopaedic Case Reports*, 3(1), 29.
5. Gazzaz, M., Akhaddar, A., Belhachmi, A., Naama, O., Asri, A. C., & Boucetta, M. (2007). Paragangliome de la queue de cheval: une observation. *Neurochirurgie*, 53(5), 456-457.
6. GUTPA R, NARAYAN S. Paraganglioma of the cauda equina region. *J Spinal Surg*, 2014, 1,4, p 174 - 176
7. Hong, J. Y., Hur, C. Y., MODi, H. N., Suh, S. W., & Chang, H. Y. (2012). Paraganglioma in the cauda equina. A case report *Acta Orthop Belg*, 78, 418-423.
8. HSIEH C-T ET AL. Paraganglioma of the cauda equine. *Neurology India*, 2009, 57, 6, p 833 -834
9. Kalani, M. A., Chang, S. D., & Vu, B. (2015). Paraganglioma of the filum terminale : case report, pathology and review of the literature. *Cureus*, 7(10).
10. Landi, A., Mancarella, C., Marotta, N., Tarantino, R., & Lenzi, J. (2013). Diagnosis and treatment of paragangliomas of the filum terminale, an extremely rare entity: Personal experience and literature review. *J Spine*, 3, e001.
11. Lapierre, F., Bataille, B., Vandermarcq, P., Goujon, J. M., Wager, M., & Page, P. (1999). Cauda equina tumors in adults. *Neuro-chirurgie*, 45(1), 29-38.
12. LICCARDO G, PASTORE F.S, SHERKAT S, SIGNORETTI, S, CAVAZZANA A, FRAIOLI B. Paraganglioma of the cauda equina. Case report with 33-month recurrence free follow-up and review of the literature. *J. Neurosurg. Sci*, 1999,43,2p169-173
13. Lmejjati, M., Parker, F., Lacroix, C., & Tadić, M. (2011). Paraganglioma of the sacral spinal canal. *Neurosciences Journal*, 16(3), 270-272.
14. Marcol, W., Kiwic, G., Malinowska-Kołodziej, I., Kotulska, K., Kotas, A., Adamek, D., & Wysokiński, T. (2009). Paraganglioma of the cauda equina presenting with erectile and sphincter dysfunction. *Journal of the Chinese Medical Association*, 72(6), 328-331.
15. Mathon, B., Carpentier, A., Clemenceau, S., Boch, A. L., Bitar, A., Mokhtari, K., ... & Cornu, P. (2012). Paragangliomes de la queue de cheval: à propos de six cas et revue de la littérature. *Neurochirurgie*, 58(6), 341-345.
16. Histoloji, K. E. Y. E. B. (2012). Cauda equina paraganglioma with ependymoma-like histology: a case report. *Turkish Neurosurgery*, 22(3), 353-359.
17. Mishra, T., Goel, N. A., & Goel, A. H. (2014). Primary paraganglioma of the spine: a clinicopathological study of eight cases. *Journal of Craniovertebral Junction and Spine*, 5(1), 20.
18. Moran, C. A., Rush, W., & Mena, H. (1997). Primary spinal paragangliomas: a clinicopathological and immunohistochemical study of 30 cases. *Histopathology*, 31(2), 167-173.
19. San Oh, H., Kim, T. W., & Park, K. H. (2014). Spinal paraganglioma adherent to the cauda equina. *Korean Journal of Spine*, 11(4), 252.
20. Simsek, M., Onen, M. R., Zerenler, F. G., Gozde, K. I. R., & Naderi, S. (2015). Lumbar intradural paragangliomas: report of two cases. *Turkish Neurosurgery*, 25(1).
21. Singh, N. G., Sarkar, C., Sharma, M. C., Garg, A., Gaikwad, S. B., Kale, S. S., & Mehta, V. S. (2005). Paraganglioma of cauda equina: report of seven cases. *Brain tumor pathology*, 22(1), 15-20.
22. Sundgren, P., Annertz, M., Englund, E., Strömblad, L. G., & Holtås, S. (1999). Paragangliomas of the spinal canal. *Neuroradiology*, 41(10), 788-794.

**Copyright:** ©2022 Bekralas H. This is an open-access article distributed under the terms of the Creative Commons Attribution License, which permits unrestricted use, distribution, and reproduction in any medium, provided the original author and source are credited.