

## Calcification of Stylohyoid Ligament Leading to Eagle's Syndrome: An Atypical Presentation

Vikash Sharma<sup>1</sup>, Rajaram Sharma<sup>2\*</sup>, Tapendra Tiwari<sup>3</sup>, Saurabh Goyal<sup>4</sup> and Sunil Kast<sup>5</sup>

<sup>1</sup>Resident Doctor, Pacific Institute of Medical Sciences, Umarda, Udaipur, Rajasthan, India

<sup>2,3,4,5</sup>Assistant Professor, Pacific Institute of Medical Sciences, Umarda, Udaipur, Rajasthan, India

### \*Corresponding author

Rajaram Sharma, Assistant Professor, Pacific Institute of Medical Sciences, Umarda, Udaipur, Rajasthan, India, 313001, Tel: +91-7755923389

Submitted: 23 Jul 2022; Accepted: 11 Aug 2022; Published: 26 Aug 2022

**Citation:** Vikash Sharma, Rajaram Sharma, Tapendra Tiwari, Saurabh Goyal and Sunil Kast (2022) Calcification of Stylohyoid Ligament Leading to Eagle's Syndrome: An Atypical Presentation. *J Oral Dent Health* 6(2): 141-143.

### Abstract

#### Background

Elongated styloid process is seen in 5% of individuals. This elongation presents with oropharyngeal pain and dysphagia; however 50-55% cases are asymptomatic. The proposed aetiology is osseous hyperplasia of the styloid process and styloid ligaments secondary to surgical intervention or pharyngeal trauma. Elongated styloid process or calcification of styloid ligament may impinge on cranial nerves and compress the carotid artery.

#### Case Presentation

Here we present a case of 48-year old male who presented with neck pain and foreign body sensation for last two months. To diagnose the cause of pain, the patient underwent a CT scan that revealed calcification of bilateral styloid ligaments.

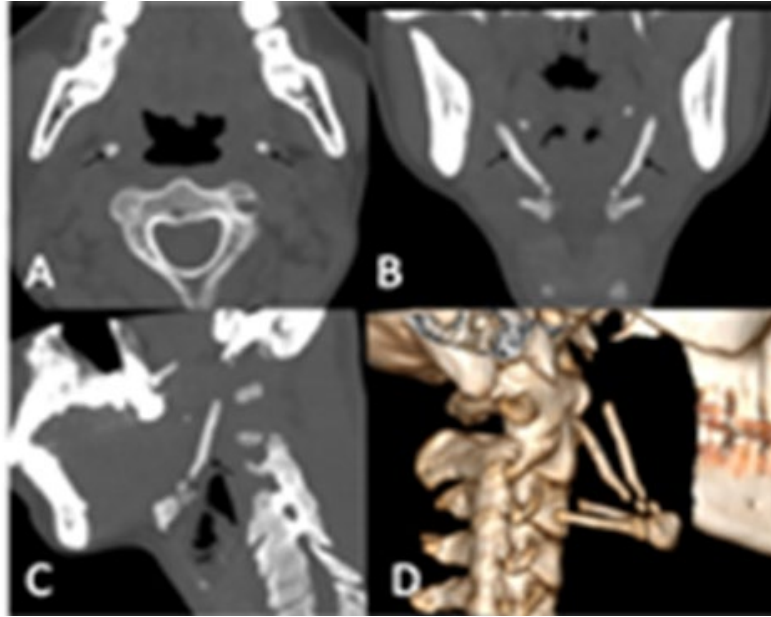
#### Conclusion

CT scan is the ideal imaging investigation in Eagle syndrome for diagnosis and surgical planning.

### Case Description

A 48-year-old male patient came to the hospital with the presentation of neck pain, foreign body sensation, swallowing difficulties and headache for two months. He did not have any related significant past medical or surgical history. There was no palpable mass or any tenderness on the extraoral examination, but tenderness on the intraoral examination could be elicited in the bilateral tonsillar fossa, and underlying hard bone-like masses were felt. A Com-

puted tomography (CT) scan of the neck was advised to evaluate bony mass and tonsillar pain that revealed calcification of bilateral styloid ligaments. CT scan nicely depicted the heavily ossified styloid ligaments extending caudally to the hyoid bone on both sides but not extending to the styloid process (Figure 1). The patient did not agree to surgery, was advised voltage-gated calcium channel inhibitor and analgesics, and kept on regular follow-up.



**Figure 1:** Non-contrast computed tomography of neck [A] axial image showing bilateral calcified styloid ligaments (Black arrow), [B] Coronal reformatted images demonstrate the heavily ossified styloid ligaments extending caudally to the hyoid bone on both sides (Black arrow), [C] Sagittal reformatted image reveals distal insertion of the calcified styloid ligaments into the anterolateral hyoid bone (Black arrow) and [D] 3D Volume rendering technique image, sagittal oblique plane illustrates calcified bilateral styloid ligaments with a small non-calcified portion.

### Discussion

Eagle described this syndromic association in 1937, representing it as a symptomatic calcified styloid ligament or elongated styloid process [1]. Anatomically, the styloid process is a bony outgrowth anterior to the stylomastoid foramen, extending downwards from the temporal bone. It is located between the internal carotid & external carotid artery, posterolateral to the tonsillar fossa, medial to the internal jugular vein, and the cranial nerves. Styloid complex comprises styloid process together with stylohyoid ligament (fibrous cord stretched between the tip of styloid process & lesser horn of hyoid bone) [2]. Ossification of this complex usually extends inferior from the base of the skull and may compress adjacent vital structures, leading to inflammatory changes that cause radiating otalgia, phantom foreign body sensation, pain in the pharyngeal region and sometimes dysphasia [3]. The combination of stylohyoid ligament ossification and these symptoms defines Eagle's syndrome. However, the diagnosis is often challenging due to the vague clinical presentation of neck pain and dysphasia. Therefore, radiological investigations play an essential role in making the diagnosis and excluding the other pathologies. The styloid process angulation, length and width with calcification of styloid ligaments characterise the symptoms of Eagle's syndrome [4]. Eagle's syndrome is classified in following types, (a) Classic type, in which elongated styloid process impinges on cranial nerves, i.e. V, VII, IX or X. (b) Variant type (Stylocarotid syndrome), the elongated styloid process compresses the carotid artery. (c) This type is the variant of stylocarotid syndrome, in which there is no caliber change in the carotid artery but due to compression and vasospasm usually results in transient ischaemic attacks [5].

Plain radiograph and computed tomography are imaging modalities used for detecting elongated styloid processes and styloid ligament calcification. CT generates a 2D image and 3D-CT image, which precisely maps the styloid angulation and peripheral anatomical structures [6]. CT is the best imaging modality for pre-operative planning for reducing injury during surgery.

### Learning Points/Take Home Messages

1. Computed tomography is the imaging modality of choice for Eagle's syndrome.
2. Isolated calcified ligaments are rare presentations that can be treated without surgery if the calcification is not reaching till the styloid process.

### References

1. WW Eagle (1937) Elongated styloid process: report of two cases. *Arch Otolaryngol* 25: 584-586.
2. Mortellaro C, Biancucci P, Picciolo G, Vercellino V (2002) Eagle's syndrome: Importance of a corrected diagnosis and adequate surgical treatment. *J Craniofac Surg* 13: 755-758.
3. Rodriguez-Vazquez JF, Merida-Velasco JR, Verdugo-Lopez LS, Sanchez-Montesinos MI, Merida-Velasco JA (2006) Morphogenesis of the second pharyngeal arch cartilage (Reichert's cartilage) in human embryos. *J Anat* 208: 179-189.
4. M Ilguy, D Ilguy, N Guler, G Bayirli (2005) Incidence of the type and calcification patterns in patients with elongated styloid process *J Int Med Res* 33: 96-102.
5. Kazmierski R, Wierzbicka M, Kotecka-Sowinska E, Banasze-

- 
- wski J, Pawlak MA (2018) Expansion of the Classification System for Eagle Syndrome. *Ann Intern Med* 168: 746-747.
6. SS Kumar, MA Kukkady, A Deena, A El Gabar Ayad (2007)

Role of three-dimensional computed tomography imaging in Eagle's syndrome. *Internet J Radiol* 7.

*Copyright:* ©2022 Rajaram Sharma. This is an open-access article distributed under the terms of the Creative Commons Attribution License, which permits unrestricted use, distribution, and reproduction in any medium, provided the original author and source are credited.