

Bone Growth After Fracture of the Femoral Shaft in Children

Ichiro Itonaga*, Tatsuya Iwasaki, Nobuhiro Kaku and Hiroshi Tsumura

Department of Orthopaedic surgery, Faculty of Medicine,
Oita University, Japan

*Corresponding Author

Itonaga Ichiro, Department of Orthopaedic surgery, Faculty of Medicine,
Oita University, Japan.

Submitted: 2023, July 06 Accepted: 2023, July 28 Published: 2023, Aug 03

Citation: Itonaga, I., Iwasaki, T., Kaku, N., Tsumura, H. (2023). Bone Growth After Fracture of the Femoral Shaft in Children. *Biomed Sci Clin Res*, 2(3), 289-294.

Abstract

Background

Overgrowth after femoral diaphyseal fractures in children has been well-known. The process and degree of overgrowth vary among patients, making it difficult to predict the length of the fractured femur at growth arrest.

Materials and Methods

3 cases aged 4-7 years (2 boys and 1 girl) with femoral diaphyseal fractures were subjected. Observation period was 6-12 years. Leg length was assessed by taking a simple X-ray of the entire lower extremities in a standing position.

Results

2 cases underwent anatomical reduction and external fixation. After the fracture had healed, there was overgrowth of the fractured femur; resulting in leg length discrepancy. Both cases were treated with an 8-plate temporal epiphysiodesis. 1 case was treated conservatively with skeletal traction, and fracture was healed with overriding of bone fragments. Overgrowth occurred and resulted in a fractured femur that became longer than opposite side. However, leg length discrepancy was gradually self-corrected and was eventually eliminated.

Conclusions

Overgrowth after femoral diaphyseal fracture was seen in all patients. Overgrowth tended to occur rapidly after the fracture and then slow down. Leg length discrepancy caused by overgrowth may be corrected during growth to some degree, and it should be decided whether patient need additional treatment.

Keywords: Overgrowth, Femoral Shaft Fracture, Leg Length Discrepancy, Temporal Epiphysiodesis

1. Introduction

Overgrowth after femoral diaphyseal fractures in children was first reported by Truesdell in 1921 and has been basic knowledge for orthopaedic surgeons [1].

The younger the age and the closer the location to the epiphyseal growth plate, the more vigorous the overgrowth occurs. It is also well-known that to some degree, shortening and dislocation are considered acceptable in the treatment of fractures [2].

In this study, we describe transverse fractures of the femoral diaphysis that we observed over a long period of time, as well as an unusual overgrowth that we also experienced.

2. Methods

Subjects were 3 cases with femoral diaphyseal fractures between 2008 and 2014, aged 4-7 years. Observation period was 6-12 years.

The radiographic images were retrieved using a picture archiving and communication system (PACS) (IMPAX; Agfa Healthcare, Mortsel, Belgium).

Leg length was assessed using PACS software with a simple x-ray of entire lower extremities in the standing position, defined as the total length of the lower extremity from the Top of the femoral head to the center of the tibial canopy. (fig.1).

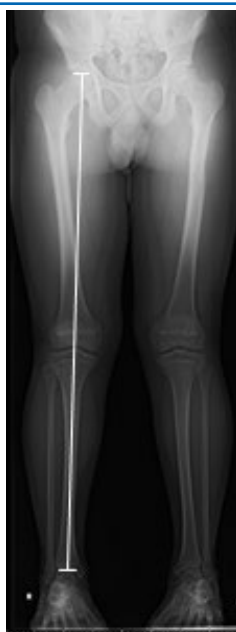

Figure 1: Whole limb length was defined as the length from the top of the femoral head to the center of the tibial plafond.

Case 1 was a 5-year-old boy and Case 2 was a 4-year-old girl, both of whom were fixed with no leg length discrepancy after anatomical realignment using Taylor spatial frame (TSF)(Smith & Nephew, Memphis, Tennessee, USA) . Case 3, a 7-year-old

boy, was conservatively treated with skeletal traction, which resulted in acceptable levels of shortening and deformation. (table1)

case	age	part	Initial treatment
1	5	left	Anatomical reduction & external fixation
2	4	right	Anatomical reduction & external fixation
3	7	left	Conservative (skeletal traction)

Table 1: Patient characteristics, fracture side and initial treatment

3. Results

Cases 1 and 2 underwent anatomical reduction and external fixation. They rapidly developed a leg length discrepancy due to overgrowth of the fractured femurs within two years postoperatively. The leg length discrepancy did not increase or decrease thereafter. Case 3, who received conservative treatment with skeletal traction, developed 11mm of shortening deformity

after bone union. Due to overgrowth after the injury, the length of the leg was reversed, resulting in a maximum discrepancy of 11mm longer on the fractured femur at 4 years after the injury, which led to an overgrowth of approximately 22mm. However, the growth of fractured femur had gradually decreased since then, and as of 9 years after the injury, the leg length discrepancy has almost disappeared. (table2)

case	LLD* (0year)	LLD (1year)	LLD (2year)	LLD (3year)	LLD (4year)	LLD (5year)	LLD (final)	Additional treatment
1	0mm	14mm	20mm	20mm	19mm	18mm	2mm	Temporary epiphysiodesis
2	0mm	11mm	16mm	15mm	16mm	15mm	3mm	Temporary epiphysiodesis
3	-11mm		3mm		11mm	8mm	1mm	none

*LLD; leg length discrepancy, fractured femur vs the other side.

Table 2: Progression of leg length discrepancy and additional treatment

4. Case Presentation


Case 2 is a 4-year-old girl who accidentally fell from the ninth floor of an apartment building and sustained a fracture of the right femoral diaphysis. (Fig.2a) An anatomical reduction and external fixation using TSF was performed and bony fusion was

achieved without leg length discrepancy. (Fig.2b) After two years of surgery, a leg length discrepancy of 16 mm was noted, and this discrepancy remained unchanged thereafter. (Fig.2c) The leg length discrepancy was corrected with the use an 8-plate (Orthofix, Verona, Italy) temporal epiphysiodesis. (Fig.2d)

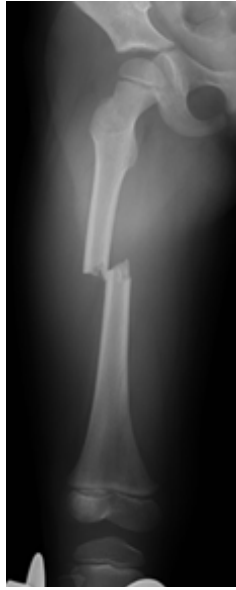
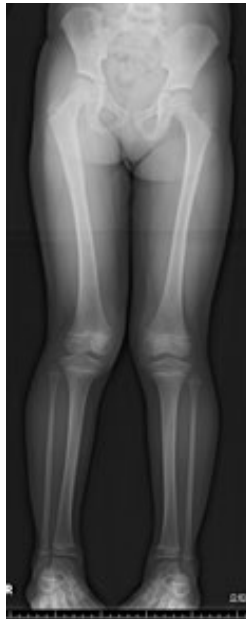
Figure 2

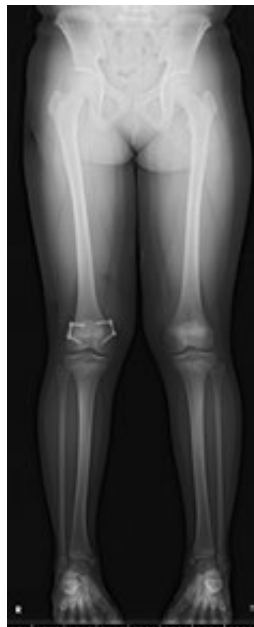A: Case 2 is a 4-year-old girl who accidentally fell from the ninth floor of an apartment building and sustained a fracture of the right femoral diaphysis



B: An anatomical reconstruction using TSF was performed



C: After two years of surgery, a leg length discrepancy of 16 mm was noted.



D: The leg length discrepancy was corrected with the use an 8-plate temporal epiphysiodesis.

Case 3 sustained a left femoral diaphyseal fracture as a result of a traffic accident. (Fig.3) After undergoing conservative treatment with skeletal traction, bony fusion was successfully achieved, however, a shortening deformity and leg length discrepancy of -11mm were observed at the time of fusion. Subsequently, the leg length discrepancy was reversed as a result of overgrowth,

and the fractured left femur became longer than the right femur, resulting in a maximum leg length discrepancy of 11 mm 4 years after injury. It was expected that the leg length discrepancy would be remain unchanged, but the discrepancy was gradually self-corrected, and as of 9 years after the injury, the leg length discrepancy was completely eliminated. (Fig.4)

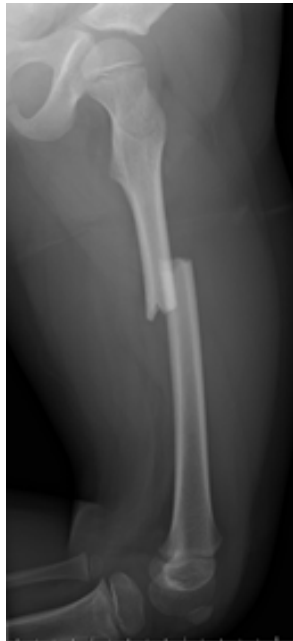

Figure 3: Case 3 sustained a left femoral diaphyseal fracture as a result of a traffic accident.

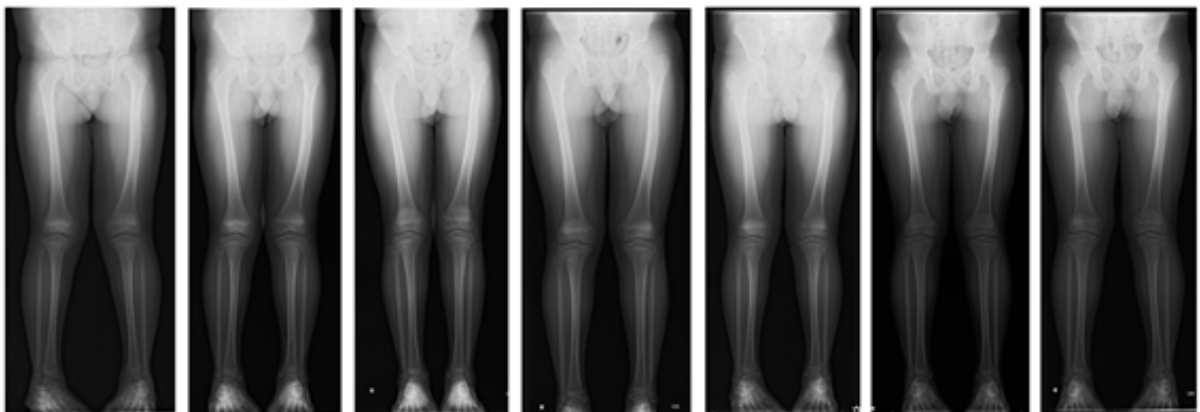


Figure 4: A maximum leg length difference of 11 mm was initially observed following the injury, but over time it gradually self-corrected. 9 years later, the leg length discrepancy had disappeared.

5. Discussion

One of the major problems after femoral diaphyseal fractures is leg length discrepancy occurred after fracture healing. Overgrowth after femoral diaphyseal fracture was reported by Truesdel in 1921[1], and it has been well recognized. There are several treatment options for femoral diaphyseal fractures in children, including conservative management, external fixation with a fixator, and internal fixation [3,4]. In this study, we treated two cases with external fixation using TSF, and one case conservatively. There was no significant difference in fracture healing and clinical outcomes.

Stilli et al. stated that overgrowth is more likely to occur within 18 months and Etchebehere et al. used bone scintigraphy to demonstrate that metabolic activity of the growth cartilage plate of the affected limb is significantly increased for 12 months after fracture and returns to normal after 18 months [5,6]. Liu et al. demonstrated in a rat model that femoral shaft fractures induce gene expression associated with bone metabolism at the growth plate. They suggested that these gene expressions

might contribute to overgrowth. [7]. Park et al. evaluated the occurrence of overgrowth following internal fixation for pediatric femur fractures. The study demonstrated that regardless of the treatment method used, overgrowth can still occur [8]. They reported an average leg length difference of 8.9 ± 6.9 mm after overgrowth.

On the other hand, the 8-plate has been reported to yield excellent results as a treatment for leg length discrepancy and bone deformities in recent years, and this device must be inserted during growth period [9,10]. Therefore, it is necessary to determine how long the overgrowth will persist and how the discrepancy in leg length will develop until the end of the growth period. In this study, epiphysiodesis using an 8-plate was performed in two cases where leg length discrepancies remained at 19mm (case 1) and 16mm (case 2). As a result, the leg length discrepancies were almost completely corrected.

Even though many cases of overgrowth occur during the first 2 years after fracture, there are no reports on how the leg length

discrepancy subsequently evolves. Although it probably does not change much, the leg length discrepancy may decrease or increase, and the precise frequency and other details are unknown. As far as we could negotiate, we could not find any report that a leg-length discrepancy was corrected by approximately 1 cm after it had widened., at least as in case 3.

Kim et al. performed a multivariate analysis to identify factors for leg length discrepancy following a femoral diaphyseal fracture. The analysis included variables such as age, gender, BMI, fracture location, whether the fracture was stable or unstable. (i.e., oblique fracture of >30 degrees or transverse fracture of <30 degrees), and high-energy or low-energy. The only significant difference observed was in leg stability (stable versus unstable), with the stable group having a 4.0-fold greater risk of having a leg length discrepancy of 1 cm or more compared to the unstable group [11].

This report is very interesting, but it still focuses on the final leg length discrepancy and does not address the process of overgrowth transition. It is difficult to predict the prognosis of overgrowth and determine whether a temporary epiphysiodesis is necessary. Therefore, careful judgement is required.

6. Conclusions

All patients showed overgrowth after femoral diaphyseal fracture. After the fracture, the overgrowth tended to occur rapidly and then gradually slowed down. The leg length discrepancy caused by overgrowth may gradually become more pronounced during growth, and this should be taken into account when determining the necessity for further treatment.

Declarations

Ethics Approval and Consent to Participate

The authors adhere to the ethical guidelines of Oita University regarding life science and medical research that involves human subjects.

Consent for Publication

Consent to publish was received from all individual patients included in the study.

Availability of Data and Material

All data analyzed during this study are included in this published article.

Competing Interests

The authors declare that they have no competing interests.

Funding

Not applicable.

Acknowledgements

Not applicable.

References

1. Truesdell, E. D. (1921). Inequality of the lower extremities following fracture of the shaft of the femur in children. *Annals of surgery*, 74(4), 498.
2. Hougaard, K. (1989). Femoral shaft fractures in children: a prospective study of the overgrowth phenomenon. *Injury*, 20(3), 170-172.
3. van Cruchten, S., Warmerdam, E. C., Kempink, D. R., & de Ridder, V. A. (2021). Treatment of closed femoral shaft fractures in children aged 2–10 years: a systematic review and meta-analysis. *European Journal of Trauma and Emergency Surgery*, 1-19.
4. Li, J., Rai, S., Ze, R., Tang, X., Liu, R., & Hong, P. (2020). Distal third femoral shaft fractures in school-aged children: a comparative study of elastic stable intramedullary nail and external fixator. *Medicine*, 99(27).
5. Stilli, S., Magnani, M., Lampasi, M., Antonioli, D., Bettuzzi, C., & Donzelli, O. (2008). Remodelling and overgrowth after conservative treatment for femoral and tibial shaft fractures in children. *La Chirurgia degli Organi di Movimento*, 91, 13-19.
6. Etchebehere, E. C., Caron, M., Pereira, J. A., Lima, M. C., Santos, A. O., Ramos, C. D., ... & Camargo, E. E. (2001). Activation of the growth plates on three-phase bone scintigraphy: the explanation for the overgrowth of fractured femurs. *European journal of nuclear medicine*, 28, 72-80.
7. Tang, Y., Tang, X., Wei, Q., & Zhang, H. (2017). Intrathecal morphine versus femoral nerve block for pain control after total knee arthroplasty: a meta-analysis. *Journal of orthopaedic surgery and research*, 12(1), 1-8.
8. Park, K. H., Park, B. K., Oh, C. W., Kim, D. W., Park, H., & Park, K. B. (2020). Overgrowth of the femur after internal fixation in children with femoral shaft fracture—a multicenter study. *Journal of Orthopaedic Trauma*, 34(3), e90-e95.
9. Stevens, P. M. (2016). The role of guided growth as it relates to limb lengthening. *Journal of Children's Orthopaedics*, 10(6), 479-486.
10. Stevens, P., Stephens, A., & Rothberg, D. (2021). Guided Growth for Tibial Recurvatum. *Strategies in Trauma and Limb Reconstruction*, 16(3), 172.
11. Kim, T. G., Park, M. S., Lee, S. H., Choi, K. J., Im, B. E., Kim, D. Y., & Sung, K. H. (2021). Leg-length discrepancy and associated risk factors after paediatric femur shaft fracture: a multicentre study. *Journal of Children's Orthopaedics*, 15(3), 215-222.

Copyright: ©2023 Itonaga Ichiro, et al. This is an open-access article distributed under the terms of the Creative Commons Attribution License, which permits unrestricted use, distribution, and reproduction in any medium, provided the original author and source are credited.