

Association of Chronic Inflammatory Bowel Diseases and Celiac Disease

Belabbes Fatima

CHU Mouhamed VI Marrakech, Morocco

*Corresponding author

Dr. Belabbes Fatima, CHU Mouhamed VI Marrakech, Morocco E-mail: fatima.belabbes121188@gmail.com

Submitted: 24 Sep 2018; Accepted: 02 Oct 2018; Published: 17 Oct 2018

Abstract

The association of celiac disease with inflammatory bowel diseases is rare. It was basically described as clinical cases. This is usually a hemorrhagic recto colitis. The purpose of our study is to assess the prevalence of CD in patients with IBD and to describe the topographic and phenotypic and progressive features of IBD in patients with CD. We report a new observation.

Keywords: Association, Celiac Disease - Chronic Inflammatory Bowel Diseases

Introduction

Inflammatory bowel diseases (IBD) result from chronic activation of the mucosal immune system under the influence of genetic and environmental factors. They include Crohn's disease and UC, and are characterized by chronic inflammation of the lining of the digestive tract [1]. Celiac disease is defined by a permanent intolerance of the intestinal mucosa to gluten. It manifests itself by a syndrome of clinical and biological malabsorption, related to total or subtotal villous atrophy of the proximal small intestine, and regressing after gluten exclusion [2, 3].

The association Inflammatory chronic diseases of the intestine (IBD) and celiac disease (MC) has been exceptionally described in the literature in the form of small series or even cases report. The etiopathogenesis of this association is complex and not known; several hypotheses have been mentioned, however none has been confirmed.

The association of the two pathologies is rarely described. We report cases with this association.

Patients and Methodes

The study was retrospective, focused on 5 cases of CM associated with IBD, recruited in 5 years (June 2012 - June 2018). The diagnosis of MC was established on the determination of specific autoantibodies, as well as a high digestive endoscopy with histopathological study of duodenal biopsies. That of the IBD was focused on a bundle of clinical, endoscopic, radiological, histological and evolutionary arguments. All patients were on a gluten-free diet for life and for specific treatment of IBD.

Results

The frequency of the MC-MICI combination was 2.5%. The mean age at the time of diagnosis of CD was 27 years (22-36 years), that of IBD was 38 years (23-40 years); we noted a clear female

predominance with a sex ratio H / F = 0.16. No pathological personal or familial antecedent notable in all cases. Diagnosis of both conditions was concomitant in 4 patients, that of CD preceded that of IBD in one case.

Three patients had Crohn's disease, 2 of whom had ileocecal localization, one patient had pancolitis with anoperineal manifestations. Two patients had a UC, one of whom had a left rectocolic localization and the other had a pancolitis.

The clinical picture was dominated by chronic diarrhea in all cases, followed by abdominal pain and weight loss which were noted in 4 cases. Extradigestive manifestations were dominated by osteoarticular pain in 4 cases. Biological abnormalities suggestive of malabsorption: a hypochromic microcytic deficiency anemia; hypoalbuminemia, hypochlesterolemia, hypoprotidemia, hypocalcemia, hypophosphoremia, and a deficiency in B12 were observed in 3 cases. Anti-transglutaminase and / or antiendomysium IgA antibodies were present in all cases. The endoscopic aspect was suggestive of MC in two cases: Rarification of folds Duodenals, a mosaic appearance in one case (Figure 1), and normal in 2 cases (Figure 2).

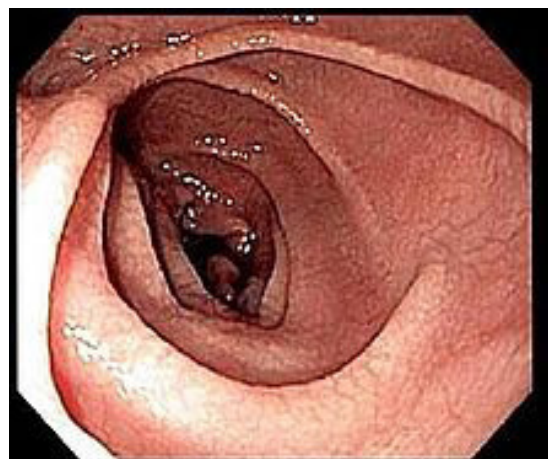


Figure 1: Aspect duodéal en mosaïque

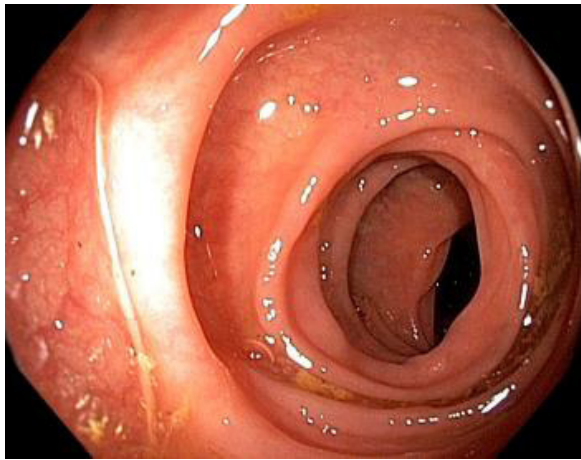


Figure 2: Aspect duodéal normal

The histopathological study of duodenal biopsies revealed stage 3 of Marsh-Oberhuber in all casent.

In our series, the Gluten Free Diet (GSR) was prescribed in all our patients, once the diagnosis is retained. A written list of banned products was given to them. It was explained to them that it was a life-long treatment and that even small deviations could be harmful to their health, combined with corticosteroid treatment adapted to the severity of the disease outbreak and a background treatment. Of MICI. Iron supplementation has been prescribed for patients with iron deficiency anemia. Calcium supplementation has been prescribed for patients with hypocalcemia.

The average duration of follow-up was 2 years [1-4]. Good progress was noted in four patients with cranial disease, with clinical improvement marked by a decrease in the number of diarrhea, regression of the anemic syndrome and weight gain, and moderate relapses of UC in one patient. However serologies of celiac disease were not realized (for lack of means). As for the endoscopic and histological explorations, a good evolution was noted en 4 patients and a therapeutic failure in the two other patients (by bad observance of the scheme).

Discussion

Inflammatory bowel diseases (IBD) that can affect the entire digestive tract and evolve by interrupted episodes of remission The diagnosis of IBD is based on several criteria: clinical, biological, endoscopic, histological and evolutive treatment [1].

Ceoliaque disease (CD) is defined by an intolerance of the intestinal mucosa to gluten, is manifested by a syndrome of clinical and biological malabsorption and a total or subtotal villous atrophy of the proximal small intestine and regressing after food exclusion gluten [2]. It may be associated with other autoimmune conditions: herpetiform dermatitis, insulin-dependent diabetes, IgA deficiency, dysthyroidism, primary biliary cirrhosis [3, 4].

The association of celiac disease with inflammatory bowel disease is rare, it has been reported mainly in the literature as clinical cases [1]. It is most often a RCH, L The association of celiac disease with Crohn's disease accounts for only 20% of cases [5-7]. In our series, the association of CD with Crohn's disease was the most frequent,

contrary to the literature data.

The prevalence of celiac disease, during cranial disease is low, it is of the order of 0.5%, this prevalence would remain lower than the population [6]. The incidence is highest in young adults, with a peak incidence between 20 and 30 years. Family forms have been described both in and in general ceoliaque disease [8].

This association is essentially an etiopathogenic problem, several hypotheses have been stated: The association of CD and cranial disease may be a fortuitous association [9]. However familial forms have been described in both CD and in cranial disease, suggesting intervention in each of these two affections of genetic factors [9].

IBD and celiac disease are responsible for a type I immune response, particularly by the involvement of T-type intra-epithelial cells [10]. Both are characterized by a decrease in cellular apoptosis that induces inflammation. A more interesting hypothesis incriminates the increase in intestinal permeability, the latter has been described during IBD, it could be related to the action of $TNF\alpha$, and could cause bacterial translocation as a consequence of bacterial growth. The increase in intestinal permeability has also been described during MC, caused by the reduction of zonulins [11].

A particular genetic predisposition that may explain this association was evoked by Cotonne et al. A more recent genetic study conducted by Garrett Lawtor et al also confirmed this genetic link of the association, which described three cases in three Sicilian families, having implicated mutation of the MYO IXB gene in both patients with CD and those with IBD, this gene codes for myosins that contribute to cytoskeletal integrity, cell polarity and intercellular junctions [9]. The mutation of this gene would result in an alteration of the intestinal permeability, which would expose many diseases including MC and IBD [12, 13].

The clinical diagnosis of the combination is difficult, since both pathologies can be manifested by diarrhea, abdominal pain, weight loss [14].

The diagnosis of this association is very often fortuitous discovery, on the occasion of the persistence of diarrhea in patients with IBD who do not respond to treatment with a different corticosteroid therapy [13]. MC is based on the combination of the following arguments: Anti-gliadin and anti-endomysium antibodies; frequent association of CD with other autoimmune diseases [2]. However, the diagnosis of IBD is based on several criteria: clinical, biological, endoscopic, histological and progressive on treatment; infiltration of the chorion by gliadin-specific CD4 T lymphocytes [3].

The treatment of the association of CD with IBD is not well codified according to the data of the literature. treatment was based on a gluten-free diet associated with the treatment of IBD according to the type of IBD, the severity of the thrust, and the location [15, 6, 7].

In our observations, all patients were put on gluten-free diet, combined with corticoid treatment adapted to the severity of the attack.

Conclusion

The association of CD with IBD is rare. Through this work and literature data, it is concluded that the aetiopathogenesis of this

association is complex especially genetic, and the need for systematic screening of celiac disease in patients with IBD by performing a high endoscopy with duodenal biopsy, at the initial colonoscopy of IBD, and a comprehensive digestive record in case of therapeutic resistance in patients with IBD.

References

1. Karoui S, Boubaker J, Hamzaoui S, Ben Yaghlene L, Filali A (2000) Association of asymptomatic celiac disease and Crohn's disease. *Ann Med Interne (Paris)* 151: 411-412.
2. Sorting JS (1998) Diagnosis of coeliac sprue. *Gastroenterology* 115: 211-216.
3. Yang A, Chen Y, Scherl E, Neugut AI, Bhagat G, et al. (2005) Inflammatory bowel disease in patients with celiac disease. *Inflamm Bowel Dis* 11: 528-532.
4. Collin P, Reunala T, Pukkala E, Laippala P, Keyriläinen O, et al. (1994) Coeliac disease associated disorders and survival. *Gut* 35: 1215-1218.
5. Snook JA, de Silva HJ, Jewell DP (1989) The association of autoimmune disorders with inflammatory bowel disease. *Q J Med* 72: 835-840.
6. Casella G, D'Inca R, Oliva L, Daperno M, Saladino V, et al. (2010) Prevalence of celiac disease in inflammatory bowel diseases: An IG-IBD multicentre study. *Dig Liver Dis* 42: 175-178.
7. I Cheikh, N Maamouri (2003) Association celiac disease and crhon disease. About an observation. *The Journal of Internal Medicine* 24 : 755-758.
8. G Kitis, GKT Holmes, BT Cooper, H Thompson, RN Allan (1980) Association of coeliac disease and inflammatory bowel disease. *Gut* 21 : 636-641.
9. Cheikh (2003) Association Celiac Disease and Crohn's Disease. About an observation. *The Journal of Internal Medicine* 24: 755-756.
10. Cominelli F, cytokine based therapies for crohns disease - new paradigms. *N Eng J med*; 2004; 351: 2045-2048
11. Levine AD, Fiocchi C (2001) regulation of life and death in lamina propria cells. *Immunology* 13: 195-199.
12. Garrett Lawlor MD, Mark A Peppercorn MD (2011) New genetic data support an association between celiac disease and inflammatory bowel disease. *Inflamm Bowel Dis* 17 : 88-81.
13. Schedel JI, Rockmann F, Bongartz T, Woenckhaus M, Schölmerich J, et al. (2005) Association of Crohn's Disease and Latent Celiac Disease: a Case Report and Review of the Literature. *International Journal of Colorectal Disease* 20 : 376-380.
14. Culliford A, Markowitz D, Rotterdam H, Green Ph (2004) Scalloping of duodenal muucosa in crohns' disease. *InflammBowel Dis* 10: 270-273.
15. Rabia Benchekroun, Ch Florent, K Nawal (2003) A rare association: Crohn's disease and celiac disease. *Acta Endoscopica* 33: 3

Copyright: ©2018 Belabbes Fatima. This is an open-access article distributed under the terms of the Creative Commons Attribution License, which permits unrestricted use, distribution, and reproduction in any medium, provided the original author and source are credited.