

Arthrogyrosis and Veptr: One Centre Case Series

Maredi E, Vommaro F, Giacomini S, Scarale A, Baioni A, Di Silvestre M, Pipola V, Pescuma G and Greggi T

Rizzoli Orthopaedic Institute

*Corresponding author

Elena Maredi, Rizzoli Orthopaedic Institute, Ist. Ortopedico Rizzoli, via Pupilli 1, Bologna (BO) 40136, Tel: +393486650558; E-mail: elena.maredi@ior.it.

Submitted: 06 Oct 2016; Accepted: 02 Oct 2016; Published: 07 Oct 2016

Abstract

As in others rare syndromes Kyphoscoliosis is the most common deformity you can find, and is a very early onset, rapidly evolving and become very stiff from early age. The incidence of scoliosis in arthrogyrosis in literature varies from 30% to 67%. Due to the complexity of the clinical is necessary a multidisciplinary approach and as soon as possible (Pediatric orthopedic surgeon, anesthesiologist, pulmonologist). There are a limited number of studies on arthrogyrosis and early onset scoliosis (EOS) surgically treated.

We reviewed our children affected by EOS in arthrogyrosis and surgically treated to describe the efficacy of rib-based distraction systems in these particular cases of deformities. We use Vertical Expandable Prosthetic Titanium Rib (VEPTR1 and 2) device.

Background

Currently there is still no consensus on the surgical treatment of kyphoscoliosis in patients with arthrogyrosis multiplex congenital (AMC) and early onset scoliosis (EOS). The urgent need to find a better treatment arises from the complexity of the clinical situation of patients suffering from these diseases. In fact, these patients need a quick multidisciplinary approach with the collaboration of the anesthetist, the pulmonologist and pediatric orthopedic surgeon, because correcting the biomechanical problems also improves systemic complications [1,2].

Moreover, due to the fact that the spine deformity in these cases is very early onset, rapidly evolving and becoming very stiff from the early age, surgical treatment must be quickly performed trying to save the physiological growth of these young patients as possible. In literature are described several options for the treatment of this disease, but there are few studies demonstrating the validity of the Vertical Expandable Prosthetic Titanium Rib (VEPTR) [3,4].

Introduction

Arthrogyrosis is a rare syndrome characterized by the replacement of skeletal muscle by dense fibrous tissue and fat that produces motion limitation of proximal and distal joints; among the others, Kyphoscoliosis is a common associated deformity with an incidence from 30% to 67% and is very early onset, evolves rapidly and becomes very stiff from the early age [4,5]. The rapid evolution of the scoliotic curve leads to respiratory and systemic problems as shown by the increased hemoglobin levels. Hemoglobin is a marker of pulmonary function in these

patients and its elevation is due to the hypoxia and the thoracic insufficiency derived from the altered biomechanics of the spine and the chest [1,2]. For this reason arthrogyrosis is a condition that requires a multidisciplinary approach with the collaboration of the anesthetist, the pulmonologist and the pediatric orthopedic surgeon.

From the surgical point of view the options for the treatment of EOS are: observation, bracing, casting, rib-based distraction instrumentation-vertical expandable prosthetic titanium rib (VEPTR™; Synthes Spine Co, West Chester, PA), spine-based distraction instrumentation (growing rods), growth guidance (Shilla technique and Luque-Trolley), growth modulation (anterior vertebral body stapling), and spinal fusion [6-10].

Because of the rarity of AMC, as well as heterogeneity in presentation, there are very few reports in the literature to help guide treatment. Growth-sparing procedures using devices such as the VEPTR may be an option for these patients with large progressive curves who are too young for definitive spinal fusion.

VEPTR technique was first described by Campbell et al. as a nonfusion implant applied with or without expansion thoracostomy in the patients with severe EOS or thoracic insufficiency syndrome (TIS); it can be used in patients aged from 6 months and up to skeletal maturity and aims at correction of the deformity with preservation of growth potential [11-13]. VEPTR has a complication rate of 9-21% and the complications are: rib fractures, proximal migration of the device, repetitive surgical interventions, and wound problems [10].

The experience of Astur N. et al. shows that VEPTR treatment can be effective, at least at short-term followup, in controlling scoliosis and maintaining thoracic growth in children with AMC with a complication rate similar to those in other patient populations [14]. Besides, VEPTR helps to regain a better respiratory function as shown by the decreasing of hemoglobin values in patients treated improving the general conditions and the quality of life [1,2].

The purpose of this study is to enhance the potential application of VEPTR in the treatment of kyphoscoliosis during Arthrogyriposis by presenting our series of patients.

Material and Methods

At our Spine Surgery Department of Rizzoli Orthopedic Institute we treated 4 patients suffering from Arthrogyriposis Multiplex Congenital from 2011 and 2014 and early onset scoliosis. The kyphoscoliosis was from beginning very stiff and rapidly worsening. The brace was performed in all young patients, but it had very bad results. These patients (1 male and 3 females) had a mean age at surgery of 5.75. Each patient was studied from the genetic point of view, brain-spinal MRI, PFT, Cardio-US and abdominal US, neuropsychiatric and neurological evaluation. No patients had brain or spinal malformations.

Surgery was performed using VEPTR system in all cases using one spinal-rib construct. Only 1 case received a double construct and 1 case underwent at final fusion with posterior instrumented arthrodesis. The most common curve was main thoracic associated to hyperkyphosis. Mean follow-up was 24 months (12-36).

Results

Thanks to first surgery, scoliosis correction was of 24.7%, from a mean value of 113.2° to a mean value of 85° and a kyphosis correction of 24,9%, from 87.2° to 65.5° (average value). After 6 lengthening procedures, 1.5 for each patient, scoliosis had a mean value of 80° and kyphosis a mean value of 81.2°, with maintenance of scoliosis correction of 6.1% and a loss of kyphosis correction of 24%. One general complication occurred in 1 patient (pneumonia) and 1 patient had an asymptomatic proximal junctional kyphosis. Children have grown on average of 2,5 cm, each follow up year. One patient underwent to final fusion at the age of 13 years old with a pedicle screw and hooks instrumentation from T2 to L3. Above all we try to correct the sagittal plane, as you can see in figure 1.

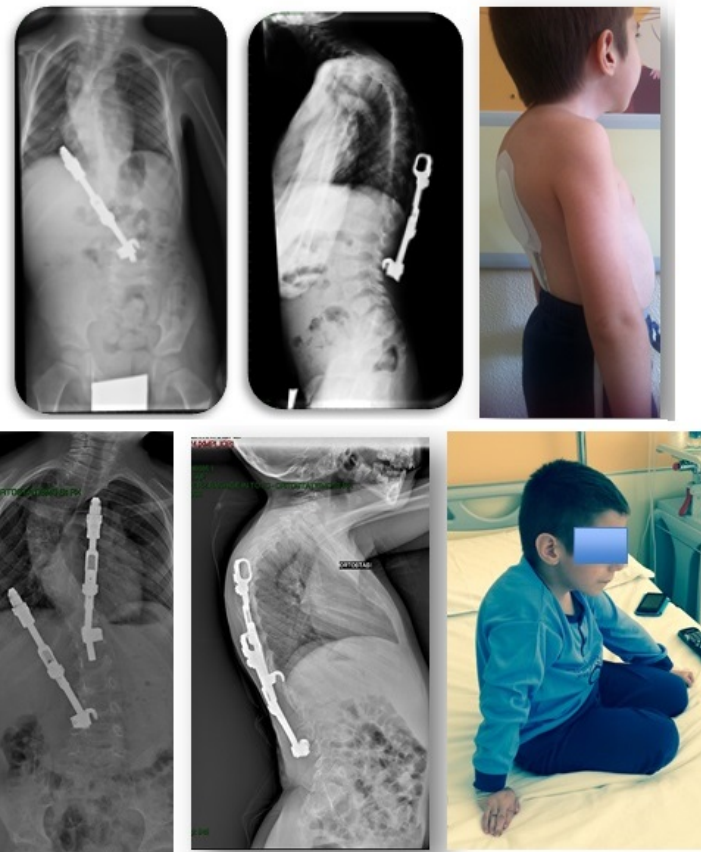
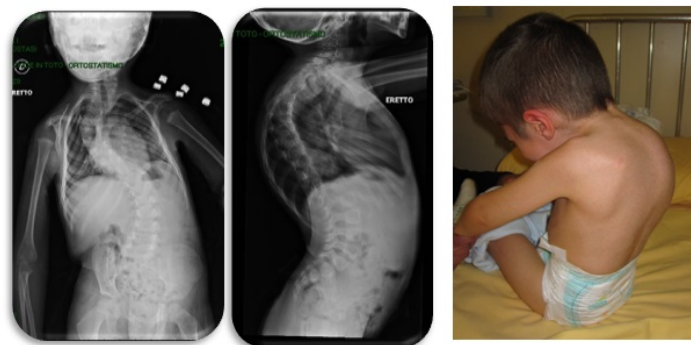

Figure 1: 2 yy and 10 mm. Body growth at the age of 2: less than 3rd centile. Respiratory deficit with frequent infections of the upper respiratory pathways. Full time braces treatment since the age of 1 year; pre and post operative x-rays and clinical view and after second VEPTR and 3 lengthening.

Discussion

Arthrogyriposis Multiplex Congenital is a rare disease that represents the phenotypical expression of more than 150 distinct entities such as Larsen syndrome, multiple pterygium syndrome or Escobar syndrome, Freeman Sheldon syndrome, Beals contractural arachnodactyly, sacral agenesis, diastrophic dysplasia, metatropic dysplasia, thrombocytopenia-absent radius (TAR) syndrome, Steinert myotonic dystrophy, spinal muscular atrophy, congenital muscular dystrophy and Moebius syndrome [15]. The incidence of scoliosis in patients with arthrogyriposis varies from 30% to 67% [4,5]. It makes difficult to find in literature case studies that describe the impact of surgical treatment in the early onset scoliosis. Scoliotic curves in these patients are typically very stiff and associated to multiple contractures and respiratory disease.

4 patients (1 male and 3 female) suffering from Arthrogyriposis Multiplex Congenital with an average age of 5,75 years at the moment of surgery have been treated at our Spine Surgery Department of Rizzoli Orthopedic Institute from 2011 to 2014. Surgery was performed using VEPTR device in all cases, 1 case with double construct. 1 case underwent to a final fusion at the age of 13 years old with pedicle screws and hooks instrumentation from T2 to L3.



Astur N, et al. realized a retrospective study on 10 patients suffering from arthrogryposis from 2011 to 2014 treated with VEPTR device in six different pediatric centers. Patients (3 male and 7 female) have been observed for a mean period of 4,3 years (range 1-7 years). 8 patients received a bilateral construct and 2 patients a unilateral construct. 2 patients received an additional thoracotomy at VEPTR moment and 1 patient with a unilateral construct received an additional rib to rib VEPTR placed. Results showed an improvement of scoliosis and kyphosis of 43 degrees (37% correction, range 15% to 61%) and 48 degrees (29% correction, range 9% to 83%) respectively. For all follow-up period there has been a mean correction of scoliosis of 17,2% (range -36,4 to 43,1) and kyphosis of 7,8% (range -30,4 to 62,9). At the end of follow up 2 patients had a progression of scoliosis and kyphosis if compared with initial X-rays. 3 patients had a Proximal Junctional Kyphosis with an average value of 33 degrees after the first procedure and 6 patients at the last control with a mean value of 45 degrees [14].

In a multi-centric study, Campbell et al. analyzed twenty-four children with nonsyndromic congenital scoliosis who were treated with VEPTR insertion and expansion thoracostomy and were followed for an average of 40.7 months (range, 25 to 78 mo). Twenty-three (95.8%) had associated rib fusions. All patients had subsequent expansion surgery; 50% had 5 or more expansions. Twenty patients (83.3%) had an improvement in Cobb angle during treatment with an average improvement of 8.9 degrees. All had an increase in thoracic height, with a mean increase of 3.41 cm. The most common adverse events were device migration in 7 patients and infection or skin problems in 6 patients [16].

Our results, instead, showed a scoliosis correction of 24,7% (from 113,2 to 85 average value) and a kyphosis correction of 24,9% (from 87,2 to 65,5 average value) after the first procedure. 6 lengthening procedures (1,5 for each patient) with a gradual improvement of scoliosis correction of 6,1% and a loss of kyphosis correction of 24%. 1 patient experienced the onset of PJK.

The small number of patients, given the rarity of disease, did not allow a statistical analysis. Although there has been a loss of correction in the sagittal plane, in the coronal we got a stable correction over time. This may be to the surgical technique and the fact that it occurred on more severe scoliotic curves and therefore with a lower evolutionary potential. Nevertheless, surgery did not affect growth potential that was of average 2,5 cm for each year of follow up.

References

1. Caubet JF, Emans JB, Smith JT, Vanbosse H, Ramirez N, et al. (2009) Increased hemoglobin levels in patients with early onset scoliosis: prevalence and effect of a treatment with Vertical Expandable Prosthetic Titanium Rib (VEPTR). *Spine* 34: 2534-2536.
2. Barrett KK, Lee C, Myung K, Johnston C, Shah SA, et al. (2016) The Effect of Growing Rod Treatment on Hemoglobin and Hematocrit Levels in Early-onset Scoliosis. *J Pediatr Orthop* 36: 618-620.

3. Balioglu MB, Albayrak A, Akman YE, Atici Y, Kargin D, et al. (2015) The effect of vertical expandable prosthetic titanium rib on growth in congenital scoliosis. *J Craniovertebr Junction Spine* 6: 200-205.
4. Greggi T, Martikos K, Pipitone E, Lolli F, Vommaro F, et al. (2010) Surgical treatment of scoliosis in a rare disease: arthrogryposis. *Scoliosis* 5: 24.
5. Drummond DS, Mackenzie DA (1978) Scoliosis in arthrogryposis multiplex congenita. *Spine (Phila Pa 1976)* 3: 146-151.
6. Campbell RM Jr, Smith MD, Hell-Vocke AK (2004) Expansion thoracoplasty: the surgical technique of opening-wedge thoracostomy. Surgical technique. *J Bone Joint Surg Am* 86-86A Suppl 1: 51-64.
7. Gomez JA, Lee JK, Kim PD, Roye DP, Vitale MG (2011) "Growth friendly" spine surgery: management options for the young child with scoliosis. *J Am Acad Orthop Surg* 19: 722-727.
8. Skaggs DL, Akbarnia BA, Flynn JM, Myung KS, Sponseller PD, et al. (2014) A classification of growth friendly spine implants. *J Pediatr Orthop* 34: 260-274.
9. Tis JE, Karlin LI, Akbarnia BA, Blakemore LC, Thompson GH, et al. (2012) Early onset scoliosis: modern treatment and results. *J Pediatr Orthop* 32: 647-657.
10. Hell AK, Campbell RM, Hefti F (2005) The vertical expandable prosthetic titanium rib implant for the treatment of thoracic insufficiency syndrome associated with congenital and neuromuscular scoliosis in young children. *J Pediatr Orthop B* 14: 287-293.
11. Campbell RM Jr, Smith MD, Mayes TC, Mangos JA, Willey-Courand DB, et al. (2003) The characteristics of thoracic insufficiency syndrome associated with fused ribs and congenital scoliosis. *J Bone Joint Surg Am* 85-85A: 399-408.
12. Campbell RM Jr, Smith MD, Mayes TC, Mangos JA, Willey-Courand DB, et al. (2004) The effect of opening wedge thoracostomy on thoracic insufficiency syndrome associated with fused ribs and congenital scoliosis. *J Bone Joint Surg Am* 86-A: 1659-1674.
13. Campbell RM (2011) VEPTR expansion thoracoplasty. In: Akbarnia BA, Yazici M, Thompson GH, editors. *The Growing Spine: Management of Spinal Disorders in Young Children*. New York: Springer 469-86.
14. Astur N, Flynn JM, Ramirez N, Glotzbecker M, et al. (2014) The efficacy of rib-based distraction with VEPTR in the treatment of early-onset scoliosis in patients with arthrogryposis. *J Pediatr Orthop* 34: 8-13.
15. Hall JG, Reed SD, Driscoll EP (1983) Part I. Amyoplasia: a common, sporadic condition with congenital contractures. *Am J Med Genet* 15: 571-590.
16. Flynn JM, Emans JB, Smith JT, Betz RR, Deeney VF, et al. (2013) VEPTR to treat nonsyndromic congenital scoliosis: a multicenter, mid-term follow-up study. *J Pediatr Orthop* 33: 679-684.

Copyright: ©2016 Maredi E, et al. This is an open-access article distributed under the terms of the Creative Commons Attribution License, which permits unrestricted use, distribution, and reproduction in any medium, provided the original author and source are credited.