

Arthrodesis of the Shoulder in Parsonage Turner Syndrome-About a Case

Mohammed Sadougui*, Soufiane Aharram, Jamal kerbal ,Amine Mechmachi, Omar Agoumi and Abdelkarim Daoudi

Department of orthopedics and trauma ,university hospital Mohammed VI, morocco

***Corresponding Author**

Mohammed Sadougui, Departement of orthopeadics and trauma ,university hospital Mohammed VI, Morrocco.

Submitted: 2023, July 04; Accepted: 2023, July 26; Published: 2023, Oct 05

Citation: Sadougui, M., Aharram, A., Kerbal, J., Mechmachi, A., Daoudi, A. et al. (2023). Arthrodesis of the Shoulder in Parsonnage Turner Syndrome -About a Case. *World J Clin Med Img*, 2(2), 72-73

Abstract

We describe a young patient who presents a paralytic shoulder secondary neurological disease it is the syndrome parsonnage turner, in whom we performed a arthrodesis of the shoulder, whose evolution has been satisfactory.

Keywords: Shoulder, Pseudoparalytic, Arthrodesis, Arthroscopy, Plate Osteosynthesis.

1. Introduction

Studies of shoulder arthrodesis have shown that arthrodesis of the shoulder results in decreased pain during normal daily activities [1, 2] and improves function and muscle strength [3].

Clinical Case:

This is a 32-year-old male patient, a manual force worker with a history of chronic smoking 20 years ago. His story begins when the patient has had a heavy load with an episode of paralysis of the right shoulder that occurred in 2006 and has reportedly declined under undocumented medical treatment for 6 months. At 7 months of evolution, the patient presented severe pain atraumatic pain in the right shoulder to burns, the pain is permanent with nocturnal recrudescence, radiating to the shoulder blade on the same side with an atrophy of the deltoid and a total impotence of this shoulder. The patient benefited in our formation from an arthroscopy of the shoulder that objectified the presence of a serumematic liquid, a transfixing lesion of the supra spinatus and a loss of the sphericity of the head with a softened cartilage, the same aspect has been observed on the glene of the scapula. During the course of the procedure, the patient received minimal debridement. After the patient has benefited several sessions of physio without any improvement. Then readmitted to our structure after 6 months for an arthrodesis of the shoulder. On clinical examination, we note an amyotrophy of the relief of the deltoid and of the supra and sub-thorn pits of the scapula on the same side of the shoulder with pain on palpation of the anterolateral aspect of the right shoulder. Painful mobility, very limited in active and passive, associated with hypoesthesia in the territory of the axillary nerve. The rest of the nerves of the upper limb are without abnormalities and the rest

of the somatic examination is without peculiarities. The patient received a radiographic assessment of a radiograph of the shoulder showing a deep destruction of the glenohumeral joint. And an MRI of the shoulder that returned in favor of a rupture of tendons of the rotator cuff including the supraspinous. (Fig.1 : A-D)

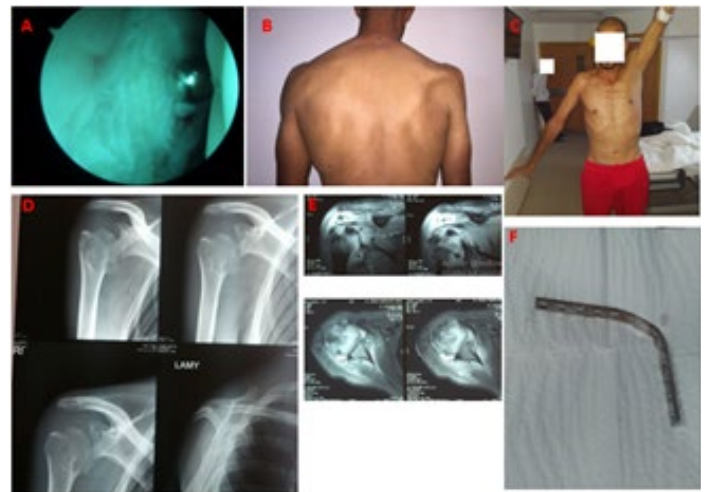


Figure 1 : A : Arthroscopic Aspect of The Glenohumeral Joint. B: Clinical Aspect on Clinica Lexamination There is An Amyotrophic Deltoid. C: Joint Mobility Very Limited to Clinical Examination. D: x-ray of the right shoulder incidence Anteroposterior and profil de lamy showing extensive destruction of the glenohumeral joint. E: irm of the shoulder showing a rupture of the rotatorcuff. F: Angle of Inclination of The Dcp Plate.

2. Surgical Technique

The installation in half-seated position by a longitudinal approach from the supra spinous fossa towards the direction of the humeral diaphysis, the deltoid muscle is dissociated in the direction of its fibers excision of the anterior and superior part of the cap. A sample was taken for cytobacteriological and pathological study. Then the capsule is opened and the articular surfaces are sharply debrided using the micro-saw as well as the vault under acromial and were resected the outer quarter of the acromioclavicular joint. Preparation of the 12-hole DCP molded plate at an angle of inclination of 100° , with a mounting position of $30^\circ/30^\circ/30^\circ$ (Antepulsion, abduction, internal rotation). Setting up of 2 spongyscrews in triangulation plated on the washers at the top of the humeral tuberosity which exerts a traction force on the glenoid. The placement of the plate with 3 screws on the spinal side of the scapula and 4 bicortical screws on the humeral shaft. Then we put in place cortical spongy graft removed from the clavicular metaphysis with a bone substitute. Then we inserted the deltoid muscle by trans-bone points and a drain of redon siphoning (Fig.2 : A-C). Postoperatively, the upper limb is immobilized by an abduction splint that has been kept for 8 weeks. The patient begins to automate the sequence and post-kinetic coordination of movements. We had active 70° active abduction, 50° internal rotation, but blocked the external rotation beyond the plane perpendicular to the body (Fig.3).

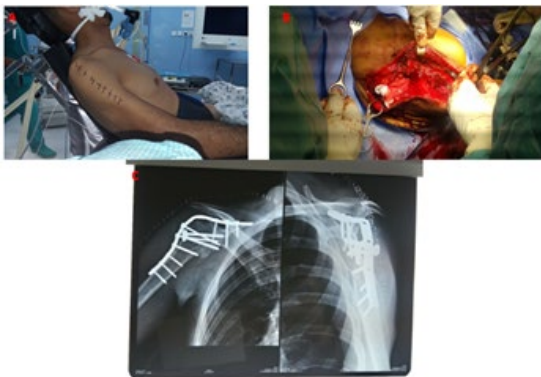

Figure 2: A : Mounting Position $30^\circ/30^\circ/30^\circ$ (Antepulsion, Abduction, Internal-Rotation). B: The Intraoperative Appearance After Placement of the Plate. C : Postoperative Control Radiography.



Figure 3: The Articular Amplitudes of The Right Shoulder After Six Months of Evolution

3. Discussion

We recommend that treatment after arthrodesis of the shoulder for a neurological lesion is also attentive to the exercises of the

not reached shoulder to optimize the functional result. For this patient, glenohumeral fusion averaged 40° , 30° and 30° degrees of abduction, direct flexion and internal rotation. The position of abduction and direct flexion is consistent with the literature on shoulder arthrodesis and the internal rotational position is inferior to that reported [4]. At fusion angles greater than 40° , the scapular belt needs a more active external rotation for the same movement. Based on these findings, it seems functionally preferable to merge the internal rotation at angles slightly below the current 40° recommendation. It is described that large flexion and forward abduction angles cause the scapula to pivot and fly away when the shoulder is at rest [5,6].

4. Conclusion

It can be concluded that the position of the fusion is an important factor for the function of the shoulder after arthrodesis of the shoulder.

Conflicts of Interest: The authors do not report any conflict of interest in this study

Contributions of the Authors: All authors contributed to this study since conception, reading, and approved the latest version.

Source of Funding For The Study : None

References

1. Sousa, R., Pereira, A., Massada, M., Trigueiros, M., Lemos, R., & Silva, C. (2011). Shoulder arthrodesis in adult brachial plexus injury: what is the optimal position?. *Journal of Hand Surgery (European Volume)*, 36(7), 541-547.
2. Wong, E. L., Kwan, M. K., Loh, W. Y., & Ahmad, T. S. (2005). Shoulder arthrodesis in brachial plexus injuries--a review of six cases. *The Medical journal of Malaysia*, 60, 72-77.
3. Chammas, M., Goubier, J. N., Coulet, B., Reckendorf, G. M. Z., Picot, M. C., & Allieu, Y. (2004). Glenohumeral arthrodesis in upper and total brachial plexus palsy: a comparison of functional results. *The Journal of Bone & Joint Surgery British Volume*, 86(5), 692-695.
4. Hudak, P. L., Amadio, P. C., Bombardier, C., Beaton, D., Cole, D., Davis, A., ... & Wright, J. (1996). Development of an upper extremity outcome measure: the DASH (disabilities of the arm, shoulder, and head). *American journal of industrial medicine*, 29(6), 602-608.
5. Safran O, Iannotti JP (2006) Arthrodesis of the shoulder. *J Am Acad Orthop Surg* 14(3):145-153.
6. JONSSON, E., LIDGREN, L., & RYDHOLM, U. (1989). Position of shoulder arthrodesis measured with Moiré photography. *Clinical Orthopaedics and Related Research* (1976-2007), 238, 117-121.

Copyright: © 2023 Mohammed Sadougui, et al. This is an open-access article distributed under the terms of the Creative Commons Attribution License, which permits unrestricted use, distribution, and reproduction in any medium, provided the original author and source are credited.