

Anatomical Study of Variations in the Branching Patterns of Neurovascular Pedicle of Latissimus Dorsi

Kshitij Naik¹, Ashel Chelsea Dsouza^{2*}, Priya Ranganath³, Meenakshi Parthasarathi⁴

¹MBBS student, BMCRI, Bangalore

²MBBS student, BMCRI, Bangalore

³Professor & Head, Department of Anatomy, BMCRI, Bangalore

⁴Professor & Head, Department of Anatomy, SABVMCRI, Bangalore

*Corresponding author

Ashel Chelsea Dsouza, MBBS student, BMCRI, Bangalore
adsouza2000@outlook.com

Submitted: 08 Aug 2022; Accepted: 15 Aug 2022; Published: 19 Aug 2022

Citation: Naik K, Dsouza A C*, Ranganath P, Parthasarathi M. (2022). Anatomical Study of Variations in the Branching Patterns of Neurovascular Pedicle of Latissimus Dorsi. *J Gene Engg Bio Res*, 4(2), 279-284.

Abstract

Introduction

Variations in the branching and position of the dominant pedicle of the Latissimus Dorsi (LD) muscle has been noted during dissection of the posterior aspect of the cadaver. Knowledge about the point of branching of the pedicle is highly valuable for the surgeon while performing various reconstructive surgeries.

Aims and Objectives

To analyze and study the insertion and branching of the dominant neurovascular pedicle of LD.

Material and Methods

A total 40 LD muscles were excised from the point of origin and retracted superior-laterally towards its insertion. The pedicle was then cleared of any unwanted fascia by strip dissection and the point of branching was identified with respect to the level of the inferior scapular angle (ISA).

Results

An anatomical variation was observed in the study of the branching of the neurovascular pedicle. Upon consideration via statistical calculations, the following levels of branching locations were noted.

~12.5% - 2.0-inch superior to level of ISA

~37.5% - 1.0-inch superior to level of ISA

~25.0% - 1.5-inch superior to level of ISA

~25.0% - 0.4-inch inferior to level of ISA

The first three types were considered as early branching whereas the last type was considered as late branching of LD.

Conclusion

This study shows the variations in the branching in the pedicle of the LD at various points that were considered. This is hence of surgical importance that must be noted to prevent surgical vascular damage that may occur during procedures and increase the methodology of pre-operative planning.

Introduction

Latissimus Dorsi (LD) is a back muscle, which is sometimes known as “climbers muscle”. The LD is commonly used in breast reconstruction surgeries by plastic surgeons. The LD muscle is a part of the posterior axio-appendicular muscles, which connect the scapula with the vertebral column. The muscle originates from inferior angle of scapula, spines of T6-T12 and thoracolumbar fascia. It inserts, varying obliquely, into the inferior angle of scapula and bicipital groove [1]. The latissimus

dorsi is supplied by a single dominant vascular pedicle formed by the thoracic-dorsal artery, a continuation of the subscapular artery. This artery and its accompanying thoracic-dorsal nerve descend in the posterior wall of axilla and enter the costal surface of the muscle at a single neuro-vascular hilum about 1–4 cm medial to the lateral border of the muscle. The presence of a single dominant vascular pedicle provides the anatomical basis for raising the muscle above, or along with the overlying skin in the form of musculocutaneous flap. The musculocutaneous flap of

latissimus dorsi is often used in reconstructing a breast following mastectomy. Further, its large size allows for no post-harvest motor deficits.

The vascular anatomy of muscles was classified into 5 types which is the most accepted classification used for choosing and designing a muscle and musculocutaneous flap for its use in reconstructive surgery. The muscle flaps have been divided into 5 types: type I: single vascular pedicle, eg. Gastrocnemius, type II: dominant pedicle(s) & other minor pedicle(s), eg. Trapezius, type III: 2 dominant pedicles each arising from a separate regional artery or opposite sides of the muscle, eg. Rectus abdominis, type IV: multiple segmental pedicles, eg sartorius and tibialis anterior, type V: one dominant pedicle with secondary segmental pedicles, eg. Latissimus dorsi & pectoralis major [2].

The aim of this study was to analyse the variations in the point of branching and branching pattern of the dominant neurovascular pedicle of latissimus Doris (type V vascular supply).

Materials and Methods

The study samples were collected from the cadavers from the Department of Anatomy, Bangalore Medical College and Research Institute. A total of 40 specimens were collected from 20 cadavers. Both female and male specimens were considered for the study. All the specimens collected were from South-Asian ethnicities.

Not all cadavers with any sort of deformity in the dorsal aspect of the thorax or damage to the neurovascular pedicle or the muscle in any way, or any atrophy of nerves or significant damage to brachial plexus were considered to be fit for the experiment.

The gender, height and approximate age of the cadaver were noted. The cadaver was placed in prone position and an oblique incision was made from the level of L2 until the bicipital groove.

The skin and fascia over the muscle were removed and the muscle was released from the point of origin at the spine and iliac crest and retracted super laterally towards its insertion. The neurovascular pedicle was exposed and was cleared of any fascia by using fine dissection. Point of branching was identified with respect to the level of ISA and measured using a measuring tape. The upper extremity of the cadavers was abducted to 90 degrees with respect to the thorax, both during the dissection procedure and while performing the measurement.

Several variations in the point of branching and the branching patterns itself were noted. Their frequency of occurrence was calculated statistically.

The point of branching and branching patterns of the dominant pedicle in the cadaver specimens was noted.

Results

In all the cadavers, the neurovascular pedicle was present and was branching below the acromion process of scapula. However, the cadavers showed variation in the branching point and pattern of branching.

The various branching point of the neurovascular pedicle to LD, was classified into types

Type 1: 0-0.5 inch inferior to ISA

Type 2: 0-1-inch superior to ISA

Type 3: 1.1-1.5-inch superior to ISA

Type 4: 1.6 to 2-inch superior to ISA

It was observed that, in 37.5% of the cadavers type 2 (figure 2) branching point was seen, this was the most common type. In this type, the neurovascular pedicle was branching 0-1 inch superior to ISA. The other types 1, 3 and 4 contributed to 22%, 26% and 12% (figure 3, 4, 5) respectively.

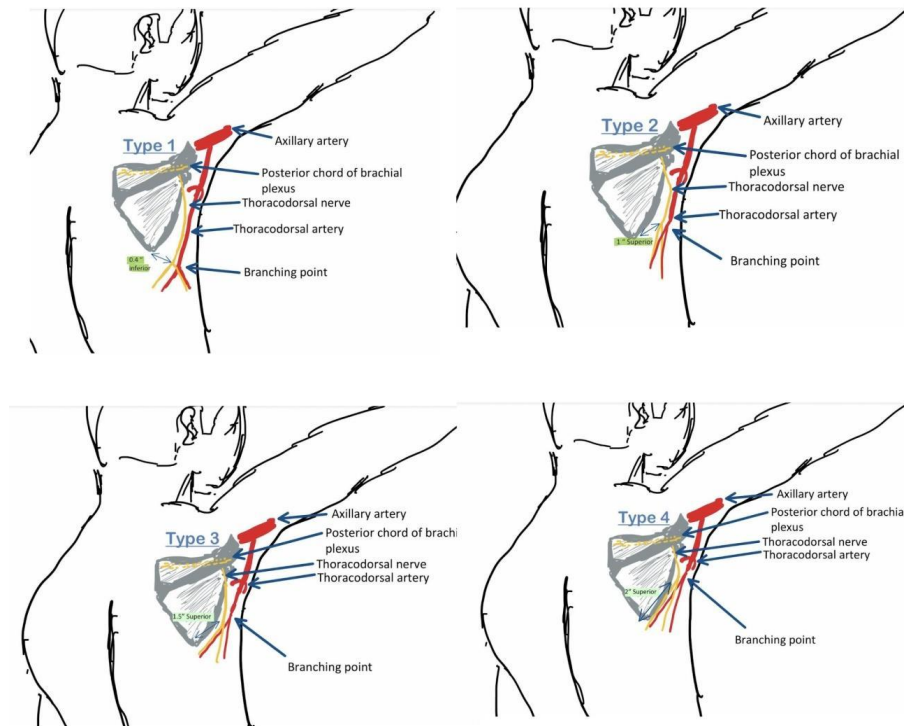


Figure 1: Types of Branching Points

Table 1: Frequencies in Types of Branching Points

Branching point	Frequency
Type 1: 0-0.5 inch inferior to ISA	9
Type 2: 0-1 inch superior to ISA	15
Type 3: 1.1-1.5 inch superior to ISA	1
Type 4: 1.6 to 2 inch superior to ISA	5

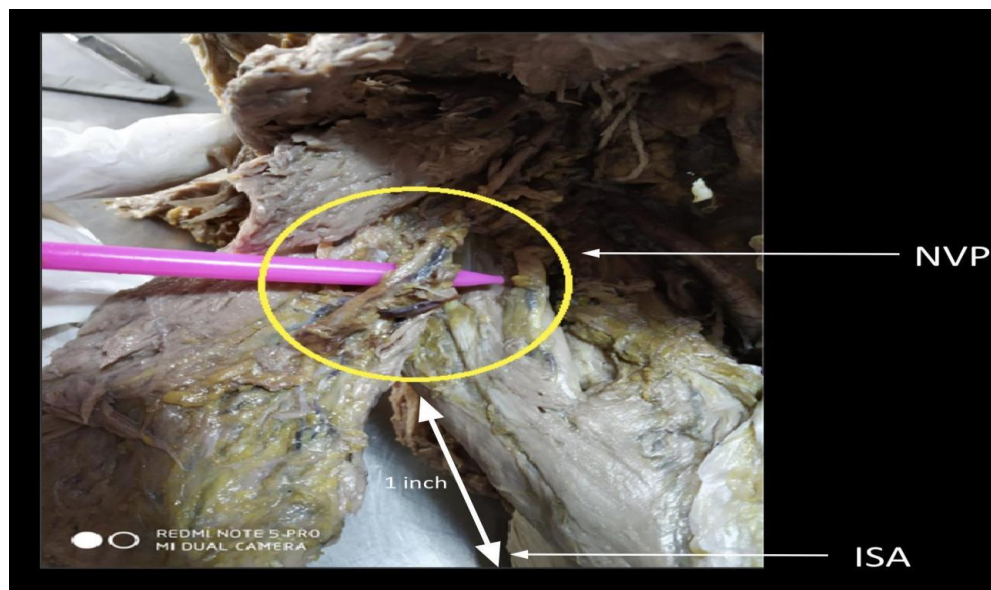


Figure 2: Type 2 Branching

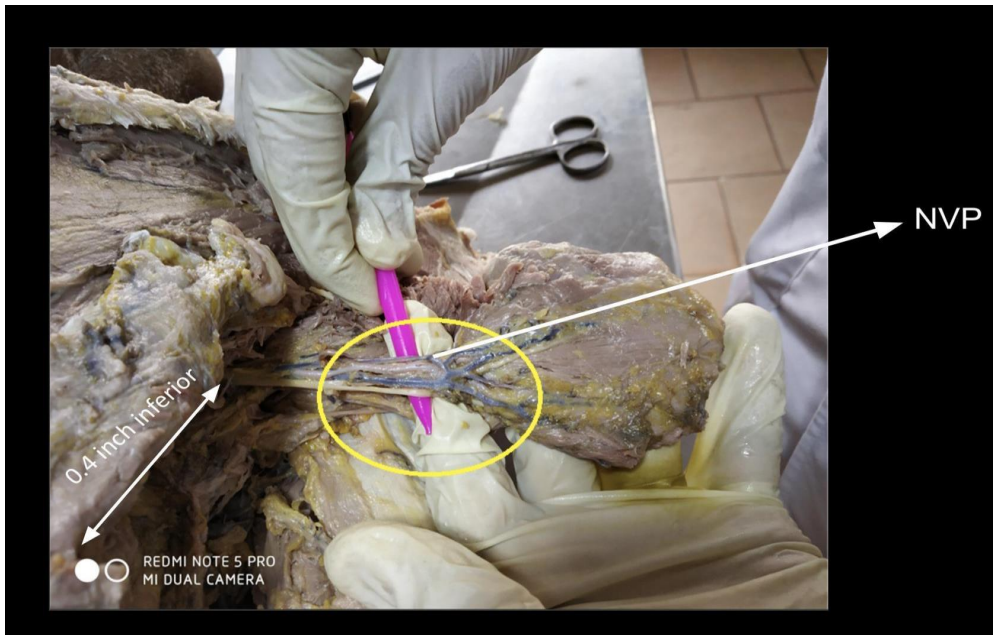

Figure 3: Type 1 Branching

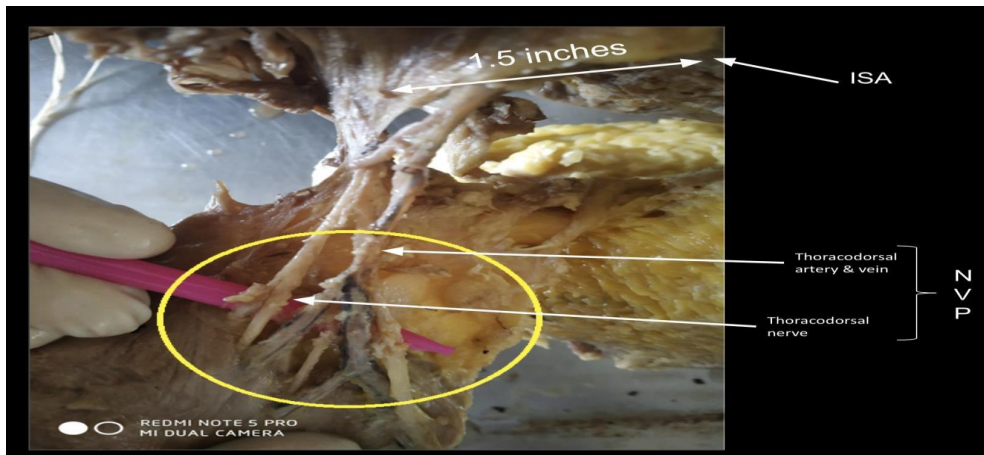


Figure 4: Type 3 Branching

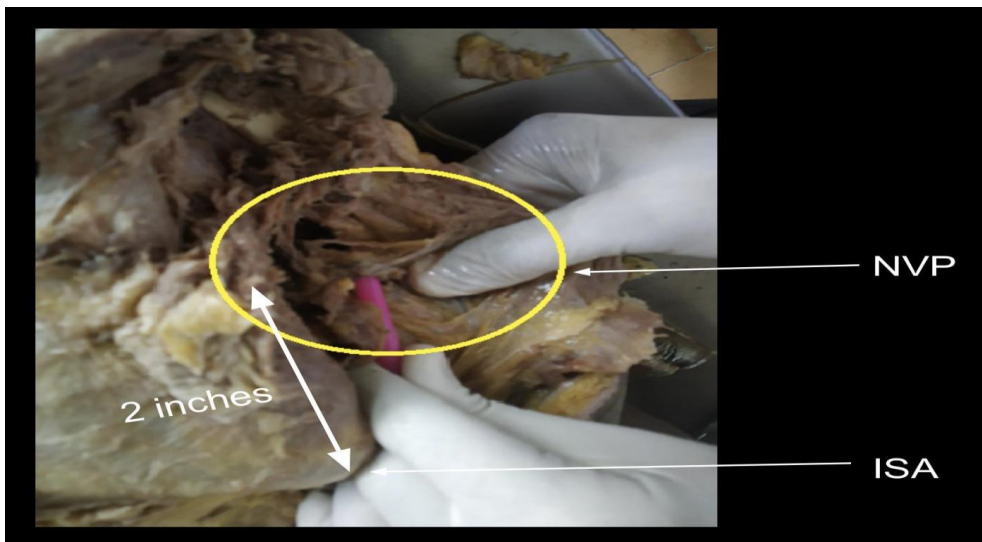


Figure 5: Type 4 Branching

The cadavers also showed variations in the type of branching pattern, based on which a new system is proposed.

Type A: V Type

Type B: spiralling type

Type C: sagumate type

The branching patterns are represented in figure 6. The frequency of branching patterns in male and female cadavers is represented in table 2. It was observed that V-type was the most

common branching pattern seen in male & female. The cadavers showed 63% v-type, 27% spiralling and 10% sagumate type of branching. The sagumate (curtain) type of branching was the most common in male cadavers, and the V-type was most common in female cadavers.

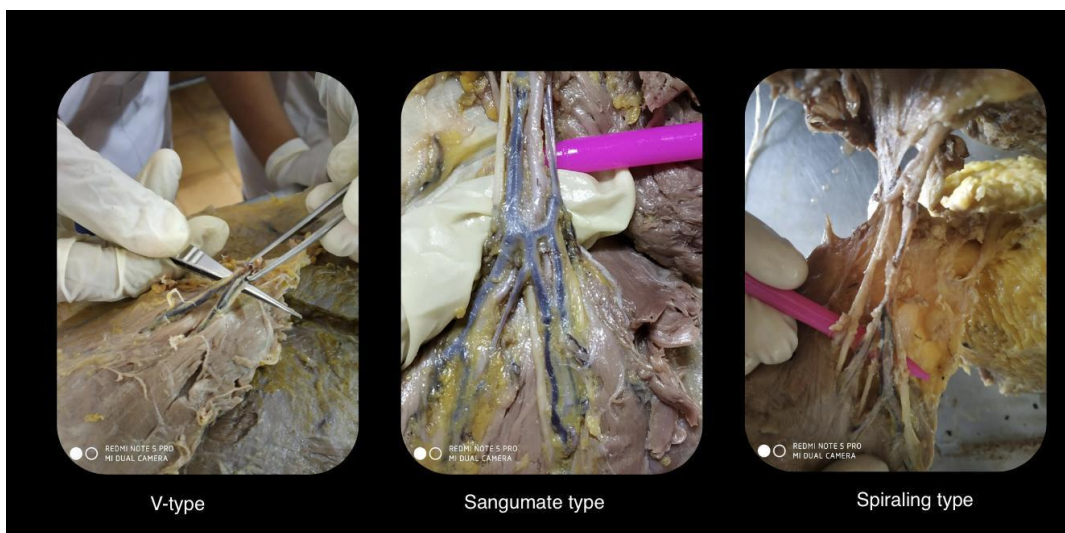

Figure 6: Types of Branching Patterns

Table 2

Branching pattern	male	female	overall
v- type	62%	38%	63%
spiralling type	25%	75%	27%
sagumate type	80%	20%	10%

Discussion

In literature, there are not enough anatomical studies, which explain the branching point and branching pattern of the neurovascular pedicle of the LD. The data of the present study were compared with the few available previous reports. Bartlett et al observed the subscapular thoracodorsal artery vascular pedicle of 11 cm mean length. He observed the long thoracic artery branches from the thoracodorsal artery. Anatomical reports are very much essential as they serve as the basis in medical research.

In the present study, the branching pattern of NVP was observed to be of V-type, Sagumate or spiralling type out of which the V-type was most common accounting for 63% of all cadavers [3].

Conclusions

2.3 million Breast cancer diagnoses are made every year with a mortality of 685000 deaths globally. The mainstay treatment includes resection of tumour and breast reconstruction [4].

Breast reconstruction after mastectomy has evolved over the last century to be an integral component in the therapy for patients with breast cancer. Breast reconstruction originally was designed to reduce post mastectomy complications and to correct chest wall deformity, but its value has been recognized to extend past this limited view of use. The goals for patients undergoing reconstruction are to correct the anatomic defect and to restore form and breast symmetry. The surgical options for breast reconstruction involve the use of endoprotheses (implants), autogenous tissue transfers, or a combination of both [5].

Iginio Tansini described the LD muscle flap technique in 1906, but it became popular only in the 1970s for breast reconstruction William Halsted included LD flap during the radical mastectomy and Schneider et al. reported the use of LDF in implant-based mammary gland reconstruction [6-8].

During the surgical mobilization of the LD muscle, all the perforating arteries from the posterior intercostal and lumbar will be divided and the only arterial supply from the thoracodorsal artery remains [9].

The present study has provided information about the various branching patterns and point of branching of the arterial supply and innervation of the LD muscle. The data of the present study may help the operating surgeons while harvesting the neurovascular pedicle flaps during the breast reconstruction procedure, a genetic correlation between branching pattern and gender can be studied, predicting post-surgical complications and recovery based on type of branching in harvested muscle.

It is described that the surgeon should have adequate knowledge of the variations in the branching of the neurovascular pedicle, which can enable the surgeon to make changes in the procedure to decrease the accidental laceration of the neurovascular pedicle, hence reducing the complications related to the surgery. V-type NVP shows a predictable, consistent and a highly organized branching, hence can be preferred over other branching patterns for more successful surgeries. Spiral Type of NVP have a greater amount of surgical risk associated with it as they branch very early and are not generally held together by a fascia once dispersed.

The study can be more accurate with a large sample size of cadavers. This study also focused on evidence gathered using cadavers from the Indian region; the results may be influenced by the ethnic predispositions in the Indian sample. Further studies, based on larger and ethnically diverse samples, may determine whether outcomes vary for different ethnic groups. The high variability in the pattern of the vascular tree between the males and females has modest clinical relevance. The variations were of a higher frequency amongst females than males, hence leading to a possibility that there is a stabilizing factor linked with the Y-Chromosome. This has multiple applications in genetic research. A physiological correlation can be made wherein LD with anastomosis-like configuration in Sagumate type NVP has a richer blood supply, hence higher efficiency and exercise tolerance.

Declarations

Ethics Approval and Consent to Participate

Not applicable

Consent for Publication

Not applicable

Availability of Data and Materials

The authors confirm that the data supporting the findings of this study are available within the article and its supplementary materials.

Conflicting Interests

The authors declare that they have no conflict of interest.

Funding

No funding was received.

Authors Contribution

K Naik and M Parthasarathi contributed to the study conception and design. K Naik and AC Dsouza performed material preparation, data collection and analysis. The first draft of the manuscript was written by K Naik and all authors commented on previous versions of the manuscript. AC Dsouza and P Ranganath wrote the final manuscript text. All authors read and approved the manuscript. K Naik took Figures 1-6 of the cadaver dissection. AC Dsouza was the author of the illustrations

Acknowledgment

The authors sincerely thank those who donated their bodies to science so that anatomical research could be performed. Results from such research can potentially increase humankind's overall knowledge that can then improve patient care. Therefore, these donors and their families deserve our highest gratitude.

References

1. Bhatt, C. R., Prajapati, B., Patil, D. S., Patel, V. D., Singh, B. G., & Mehta, C. D. (2013). Variation in the insertion of the latissimus dorsi & its clinical importance. *Journal of orthopaedics*, 10(1), 25-28.
2. Mathes, S. J. (2014). Classification of The Vascular Anatomy of Muscles: experimental and clinical correlation 1981. In *50 Studies Every Plastic Surgeon Should Know* (pp. 57-62). CRC Press.
3. Bartlett, S. P., May Jr, J. W., & Yaremchuk, M. J. (1981). The latissimus dorsi muscle: a fresh cadaver study of the primary neurovascular pedicle. *Plastic and reconstructive surgery*, 67(5), 631-636.
4. <https://www.who.int/news-room/fact-sheets/detail/breast-cancer>
5. Gust, M. J., Nguyen, K. T., Hirsch, E. M., Connor, C. M., Davila, A., Rawlani, V., & Kim, J. Y. (2013). Use of the tabbed expander in latissimus dorsi breast reconstruction. *Journal of Plastic Surgery and Hand Surgery*, 47(2), 126-129.
6. Maxwell, G. P. (1980). Iginio Tansini and the origin of the latissimus dorsi musculocutaneous flap. *Plastic and reconstructive surgery*, 65(5), 686-692.
7. Prabhu, L. V., Pai, M. M., Lakshmisha Rao, Y., Murlimanju, B. V., & Vadgaonkar, R. (2020). Female Cadaveric Study of Neurovascular Pedicle in Latissimus Dorsi Muscle Flap. *Muscles, Ligaments & Tendons Journal (MLTJ)*, 10(4).
8. Schneider, W. J., Hill Jr, H. L., & Brown, R. G. (1977). Latissimus dorsi myocutaneous flap for breast reconstruction. *British Journal of Plastic Surgery*, 30(4), 277-281.
9. Salmons, S. (2003). Invited review: avoiding ischaemic damage in latissimus dorsi muscles redeployed as functional grafts. *BAM-PADOVA-*, 13(2), 71-82.

Copyright: ©2022 Kshitij Naik. This is an open-access article distributed under the terms of the Creative Commons Attribution License, which permits unrestricted use, distribution, and reproduction in any medium, provided the original author and source are credited.