

An Unusual Cause of Chest Pain and Dyspnea in an Elderly: Giant Intrathoracic Hiatal Hernia

Richmond Ronald Gomes

Department of Medicine, Ad-din Women's Medical College and Hospital, Dhaka, Bangladesh.

Corresponding author

Richmond Ronald Gomes, Department of Medicine Ad-din Women's Medical College and Hospital, Dhaka, Bangladesh

Submitted: 01 Dec 2020; Accepted: 07 Nov 2021; Published: 17 Dec 2021

Citation: Richmond Ronald Gomes (2021) An Unusual Cause of Chest Pain and Dyspnea in an Elderly: Giant Intrathoracic Hiatal Hernia *J Gastro & Digestive Systems* 5(2): 53-56.

Abstract

Giant hiatal hernias, generally seen at advanced ages, can rarely cause cardiorespiratory symptoms such as dyspnea and chest pain. Here, we aimed to present a case with a large hiatal hernia that largely protruded to intrathoracic cavity and caused dyspnea, particularly at postprandial period. We report a case of a 74-year-old female who presented with one-month history of progressive shortness of breath and left sided chest pain. Upon arrival, the patient was found to be hypoxic with oxygen saturation 90% on room air. Physical examination also showed decreased breath sounds on left mid to basal lung with shifting of trachea and apex beat to right side. Plain radiograph demonstrated an increased opacity at the left lower lobe with retro-cardiac air fluid level; Subsequent computerized tomography of the chest revealed a giant hiatal hernia, containing stomach, duodenum, colon and spleen. This case highlights the giant hiatal hernia as an unusual cause of shortness of breath and chest pain, especially in elderly patients.

Keywords: Hiatal Hernia, Dyspnea, Chest Pain, Retro Cardiac Air Fluid Level.

Introduction

Hiatal hernia is defined as abnormal protrusion of stomach with another intra-abdominal organ, in some cases, above diaphragm from esophageal hiatus. A giant hiatal hernia is defined by a hernia that consists of >30% of the stomach herniating through the diaphragmatic hiatus into the thorax (1). Its prevalence has been reported as 0.8–2.9% in upper gastrointestinal endoscopy series. Here, we aimed to present a case with a hiatal hernia that largely protruded into thorax cavity, causing dyspnea and chest pain. Generally, patients with giant hiatal hernias often present with gastrointestinal symptoms such as dysphagia and heart burn, whereas cardio respiratory symptoms caused by hiatal hernias are extremely uncommon. Hence, we report a case of a patient with a giant hiatal hernia who presented with progressive shortness of breath chest pain and hypoxia (2).

Case Report

A 74-year-old woman, smoker presented to the outpatient clinic with increasing fatigue, shortness of breath with heaviness and pain in left side of chest over 1 month. She noted that her shortness of breath was aggravated with exertion and after the ingestion of

food but there was no history of orthopnea or paroxysmal nocturnal dyspnea. The patient did not describe an underlying chronic disease such as hypertension, diabetes mellitus or coronary artery disease and denied use of any medication within the previous 6 months apart from occasional use of proton pump inhibitors and montelukast with minimal relief of her symptoms. She also had no history of fever, cough, hemoptysis, hematemesis, melana, loss of appetite, substantial loss of weight or other constitutional symptoms. She had history of blunt compressive trauma to the chest 15 days back. She also gave history of abdominal discomfort and heart burn after taking meal for last four years. Her bowel and bladder habit was normal. On the physical examination, vital signs were stable except respiratory rate 22 breath/min and pallor was observed at conjunctiva. Cardiovascular and abdominal examinations were non-conclusive apart from shifting of apex beat towards right. On respiratory system examination, patient is mildly dyspnoeic at rest with respiratory rate 20 breaths/min. Pulse oxymetry showed SaO₂ 90% in room air. Chest examination revealed restricted movement on the left side of the chest. Trachea is shifted to the right side. Chest expansibility is restricted over the left lower chest. Percussion note is dull in left 7th intercostal space

downwards in scapular line. Breath sound and vocal resonance are diminished over the same area. In the laboratory evaluations, the following results were obtained: WBC, 7400/mm³; Hg%- 9.9 g/dL; MCV, 72.3 fL; MCH 22.2;Plt, 376.000/mm³.

Table 1: Hematological and Biochemical Parameters

Investigations	Results	Reference range
Hemoglobin(gm%)	9.9	12-16
MCV	72.3	76-96
MCH	22.2	26-32
Serum Bilirubin(mg/dl)	0.9	0.5-1.5
SGPT(U/L)	40-60	52
Alkaline phosphatase(IU/L)	76	45-150
Serum Creatinine(mg/dl)	0.83	0.5-1.3
Serum Electrolyte(mmol/L)		
a) Sodium	138	135-145
b) Potassium	4.1	3.5-5.5
c) Chloride	98	95-105
d) Bicarbonate	26.3	22-28

On chest radiograph posterior anterior view there was increased cardiothoracic index, enlarged mediastinum, and a mass appearance with an air-fluid level superposed with cardiac contours were observed (Figure 1).

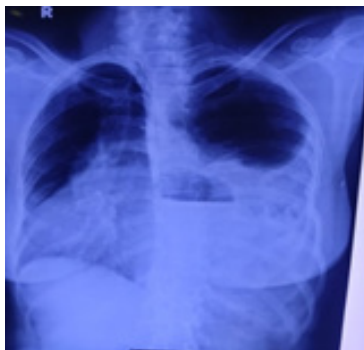

Figure 1: Plain radiography in the upright position showed a slightly enlarged heart size with a parenchymal opacity visualized in the left lower lobe, which partially silhouetted the left hemi diaphragm and obscured the cardiac apex. There is also retro cardiac gas fluid level.

A thoracic CT scan including sagittal and coronal sections was performed in the patient because of the suspicion of a large hiatal hernia with available image. It was found that the stomach, spleen, part of both small and large gut was herniated into mediastinum without any finding of incarceration and gastrointestinal obstruction (Figure 2, 3).

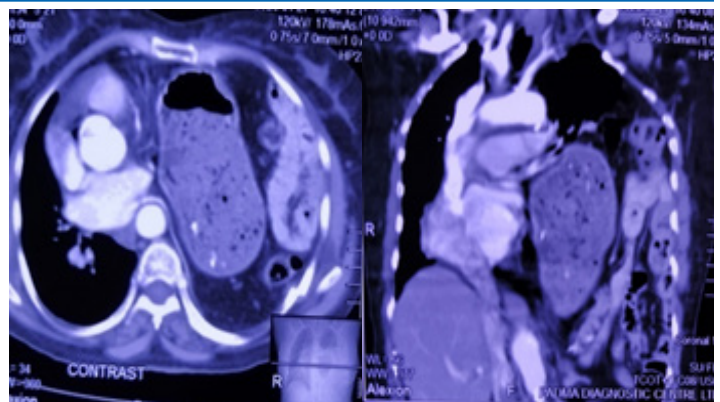


Figure 2 & 3: Computed tomography. (A) Thorax coronal view; and (B) sagittal view demonstrating a large hiatal hernia containing the entire stomach, proximal duodenum, a portion of the transverse and descending colon, and the spleen in the thoracic cavity.

On the upper gastrointestinal endoscopy, there were linear erosions at esophagogastric junction where hiatal hernia and diaphragmatic compression occurred. Active gastrointestinal bleeding was not observed (figure 4).

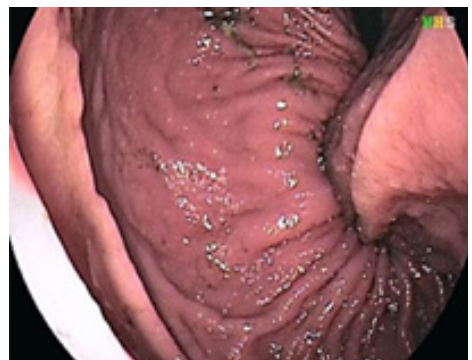

Figure 4: Endoscopy of UGIT showing large hiatus hernia with no active gastrointestinal bleeding.

ECG, color doppler echocardiography showed no evidence of cardiac disease but there was significant compression of left atrium by large hiatal hernia. Surgery and cardiology were consulted for surgical repair and pre-operative evaluation of the hernia. However, the patient refused surgery because of the high surgical risk due to advance age. The patient was discharged with frequent follow-up at the medicine clinic with life style medication advices, proton pump inhibitor and motility regulator therapy. Nutritional recommendations were also given.

Discussion

Hiatal hernia is defined as abnormal protrusion of stomach with another intra-abdominal organ, in some cases, above diaphragm from esophageal hiatus (3). Giant hiatal hernia is responsible for 0.3 to 15% of all hiatal hernias. Type I hiatal hernia (sliding type)

is the most commonly observed type in which gastroesophageal junction slides together with a part of the stomach (4). Although the cause for the development of hiatal hernia is unknown, its incidence increases by advancing age (5). It is accepted that relaxation at diaphragmatic crura resulting from aging process is the cause for the observation of more frequent and larger hiatal hernias in elder population (6). Symptoms are often related to gastroesophageal reflux disease in hiatal hernias which is usually asymptomatic. Generally, older people are unable to describe typical reflux symptoms such as burning at chest, acid regurgitation, and epigastric pain. Gastrointestinal bleeding related to ulcer or erosion, iron deficiency anemia, mucosal prolapse, incarceration, and volvulus are the main complications of hiatal hernia. Particularly, the most frightening complications are the development of incarceration or volvulus. Cardiorespiratory symptoms are considered a very uncommon clinical presentation.

Reported a case of bilateral Bochdalek hernias presenting with respiratory failure that required noninvasive ventilator support (7). Illustrated a case of an 82-year-old female who presented with dyspnea and oxygen desaturation and was found to have hiatal herniation of the stomach and pancreas (8). Chou and Sureported a case of an 86-year-old female who also presented with shortness of breath caused by giant hiatal hernia followed by Takotsubo cardiomyopathy (9). Reported that a large hiatal hernia caused cardiac failure by the compression to the left atrium in a case presenting with recurrent acute cardiac failure attacks (14). Interestingly, all reported cases were female over the age of 80 years with multiple comorbidities. None of them received surgical intervention for definite management.

In addition to shortness of breath as a rare presentation, hiatal hernia can also present with angina pectoris, arrhythmias, recurrent heart failure due to the extent of hernia and the compression to heart and pulmonary veins by organs protruded into thorax cavity and exercise impairment (10).

There is an increasing incidence of hiatal hernia with age, from approximately <10% under the age of 30 years to >60% above the age of 70 years (11). Interestingly, most of the reported cases of hiatal hernia with atypical presentation were all elderly patients, especially over the age of 80 years. Surgical intervention is considered the goal standard and definitive treatment for hiatal hernia. After the repair, spirometry has been shown to demonstrate an improvement of FEV1, FVC, and total lung capacity, resulting in an improvement in exercise capacity (12-14).

Iron deficiency anemia is one of the commonly seen complications in the setting of hiatal hernia. Association between the iron deficiency anemia and hiatal hernia has been known since the early 1930s (15). The main reason for iron deficiency anemia in hiatal hernia is the hemorrhage resulting from linear ulcers and erosions (Cameron lesion) at mucosal folds where diaphragmatic compression occurs (16-17). Bleeding is not the only factor responsible for the anemia in patients with hiatal hernia. One of the reasons for iron deficiency anemia in hiatal hernia is chronic gastritis with all the consequences. Today, although it is often missed, these lesions, one of the occult reasons for both gastrointestinal bleeding and iron deficiency anemia, are reported in 5% of the patients with hi-

atal hernia and 20% of the patients with persistent anemia and recurrent bleeding (18-19). Stated that Cameron lesions were not an uncommon cause of chronic gastrointestinal bleeding and should be kept in mind in the study of patients with iron deficiency anemia (20). In our case, it was thought that chronic iron deficiency anemia had been explained by the advanced age and impaired oral ingestion.

In our case, chronic fatigue and exertion dyspnea particularly aggravated at postprandial period. By available findings, it was thought that dyspnea aggravating after heavy meals is due to pulmonary congestion from the compression to the left atrium and the right pulmonary vein.

In summary, a giant hiatal hernia can be considered as an uncommon cause of shortness of breath and chest pain, especially in geriatric patients. Surgical intervention is the goal standard treatment for hiatal hernia.

Conclusion

In conclusion, large hiatal hernias should be considered in the differential diagnosis as a rare intra-abdominal cause of persistent iron deficiency anemia, dyspnea and chest pain. It should be kept in mind that large hiatal hernias can lead to cardiorespiratory symptoms and complications due to compression. Cases with large hiatal hernias should be assessed by physical examination, endoscopy of UGIT and imaging modalities such as CT scan of thorax.

References

1. Miteik MO, Andrade RS (2010) Giant hiatal hernia. *Ann Thorac Surg* 89: S216873.
2. Akdemir I, Davutoglu V, Aktaran S (2001) Giant hiatal hernia presenting with stable pectoris and syncope- a case report *Angiology* 52: 8635.
3. Johnson DA, Ruffin WK (1996) Hiatal hernia. *Gastrointestinal Endoscopy Clinics of North America* 6: 641-666.
4. Maziak DE, Todd TRJ, Pearson FG (1998) Massive hiatus hernia: evaluation and surgical management. *Journal of Thoracic and Cardiovascular Surgery* 115: 53-62.
5. Miho Yoshimura, Akihito Nagahara, Keiichi Ohtaka, Yuji Shimada, Daisuke Asaoka, et al. (2008) Presence of vertebral fractures is highly associated with hiatal hernia and reflux esophagitis in Japanese elderly people. *Internal Medicine* 47: 1451-1455.
6. Cole TJ, Turner MA (1993) Manifestations of gastrointestinal disease on chest radiographs. *Radiographics* 13: 1013-1034.
7. Alviar CL, Cordova JP, Korniyenko A, JavedF, Tsukayama M, et al. (2011) Bilateral Bochdalek hernias presenting as respiratory failure in an elderly patient. *Respir Care* 56: 6914.
8. Torres D, Parrinello G, Cardillo M, Bellanca M, Licata G (2013) Hiatal herniation of the stomach and pancreas in a patient with oxygen desaturations. *Libyan J Med* 8: 23288.
9. Chou CJ, Su HM (2014) An unusual cause of dyspnea: giant hiatal hernia followed by Takotsubo cardiomyopathy. *Kaohsiung J Med Sci* 30: 4845.
10. Naoum C, Falk GL, Ng AC, Lu T, Ridley L, et al. (2011) Left atrial compression and the mechanism of exercise impairment in patients with a large hiatal hernia. *J Am CollCardiol* 58: 162434.

-
11. Winans CS and Hiatus hernia (1972) Its significance in the elderly patient. *Geriatrics* 27: 6978.
 12. Khanna A, Finch G (2011) Paraoesophageal herniation: a review. *Surgeon* 9: 10411.
 13. Lim HS, Leong DP, Alasady M (2013) Massive hiatus hernia mimicking a left atrial mass. *Heart, Lung and Circulation* 22: 875-876.
 14. CW Siu, MH Jim, HH Ho, F Chu, HW Chan, et al. (2005) Recurrent acute heart failure caused by sliding hiatus hernia. *Postgraduate Medical Journal* 81: 268-269.
 15. Bock AV, Dulin JW, Brooke PA (1933) Diaphragmatic hernia and secondary anemia: 10 cases. *The New England Journal of Medicine* 209: 615.
 16. Windsor CW, Collis JL, Anaemia and hiatus hernia (1967) experience in 450 patients. *Thorax* 22: 73-78.
 17. Cameron AJ (1976) Incidence of iron deficiency anemia in patients with large diaphragmatic hernia: a controlled study. *Mayo Clinic Proceedings* 51: 767-769.
 18. Kimer N, Schmidt PN, Krag A (2010) Cameron lesions: an often overlooked cause of iron deficiency anaemia in patients with large hiatal hernias. *BMJ Case Reports* 2010:
 19. Cameron AJ, Higgins JA (1986) Linear gastric erosion. A lesion associated with large diaphragmatic hernia and chronic blood loss anemia. *Gastroenterology* 91: 338-342.
 20. Bernardo RJ, Portocarrero JP, Tagle M (2012) Cameron lesions: clinical experience. *Revista de Gastroenterología del Perú* 32: 157-160.

Copyright: ©2021 Richmond Ronald Gomes. This is an open-access article distributed under the terms of the Creative Commons Attribution License, which permits unrestricted use, distribution, and reproduction in any medium, provided the original author and source are credited.