

An Unexpected Complication: Glans Ischemia After Urethrectomy

HIMMI Yassir^{1*}, SLAOUI Amine¹, BABTY Mouftah¹, KARMOUNI Tarik¹, EL KHADDER Khalid¹, KOUTANI Abdellatif¹, IBEN ATTYA Ahmed¹.

¹Department of Urology B, IBN SINA Hospital, Mohammed V University Rabat, Morocco.

*Corresponding author

HIMMI Yassir, Department of Urology B, IBN SINA Hospital, Mohammed V University Rabat, Morocco.

Submitted: 13 Aug 2022; Accepted: 20 Aug 2022; Published: 26 Aug 2022

Citation: HIMMI Yassir, SLAOUI Amine, BABTY Mouftah, KARMOUNI Tarik and EL KHADDER Khalid, et al. (2022). An Unexpected Complication: Glans Ischemia After Urethrectomy, *World J Clin Med Img*, 1(1), 45.

Necrosis of the glans is a rare and unexpected complication of urethrectomy. The literature is poorly documented regarding this complication.

We report here the case of a 49 year old patient with a history of chronic smoking, followed for bladder tumour initially without muscle infiltration. Lost to follow-up for 3 years, his re-evaluation revealed a muscle-infiltrating bladder tumour with localization in the prostatic urethra without other secondary localizations.

The patient underwent a cystoprostatectomy with a bricker type urinary diversion completed by a urethroctomy. Seven days later he presented with glans necrosis. Examination revealed a blackish, painless glans.

Necrosis of the glans remains a rare complication of urethrectomy that should not be ignored. It is imperative to warn the patient before any surgery as this complication has a significant psychological impact on the patient's body image and consequently on his quality of life.

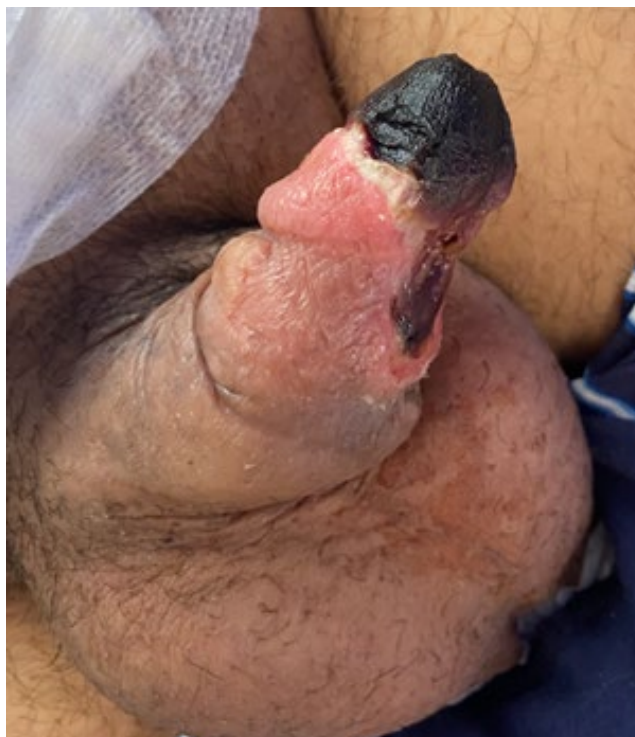


Figure 1: Necrosis of the glans

Copyright: ©2022 HIMMI Yassir. This is an open-access article distributed under the terms of the Creative Commons Attribution License, which permits unrestricted use, distribution, and reproduction in any medium, provided the original author and source are credited.