

## A Rare Case of Rickettsial Infection Presented as Febrile Delirium in a 4 Years Old Child from a Government Hospital, Andhra Pradesh, India

Rama Prasad GS<sup>1</sup>, Suhasini Mekala<sup>2</sup>, Mallikarjuna M<sup>3</sup> and Naresh Gadagani<sup>4\*</sup>

<sup>1</sup>Professor, Department of Pediatrics, Kurnool Medical College, Kurnool

<sup>2</sup>Associate Professor, Department of Pediatrics, Kurnool Medical College, Kurnool

<sup>3</sup>Assistant Professor, Department of Pediatrics, Kurnool Medical College, Kurnool

<sup>4</sup>Post Graduate, Department of Pediatrics, Kurnool Medical College, Kurnool

### \*Corresponding author

Naresh Gadagani, Post Graduate, Department of Pediatrics, Kurnool Medical College, Kurnool. E-mail: 2k5nash@gmail.com

Submitted: 11 June 2019; Accepted: 18 June 2019; Published: 24 June 2019

### Abstract

We report here a documented case of Febrile delirium in a child caused by *Rickettsiae*. Rickettsial infection is a relatively under-diagnosed entity in children with fever and rash, probably due to low index of suspicion and the lack of definitive diagnostic facilities. Rickettsial infections can be treated effectively with anti-microbials; Developing countries may use Weil Felix test as a diagnostic method, if they remain undiagnosed and untreated, they are associated with significant morbidity and mortality. This differential diagnosis should be considered when a child is seen with fever and rash.

**Keywords:** Spotted Fever, Rickettsial Infections, Weil Felix Test, Febrile Delirium, Tropical Diseases, Bacterial Infections, Reemerging Infections

### Introduction

Rickettsiae are small, non flagellate, Gram-negative pleomorphic, coccobacilli adapted to obligate intracellular parasitism and transmitted by arthropod vectors like fleas, ticks, mites and lice [1]. Vasculitis is the basic pathogenic mechanism and is responsible for skin rash, microvascular leakage, edema, and tissue hypoperfusion and end organ ischemic injury. Severe involvement of the central nervous system (CNS) has been reported in adults with Rickettsia conorii infection, but rarely in children [2-5].

### Case Report

A 4year Old, Previously healthy male Child was admitted to Government Hospital, Kurnool with history of fever for 10 days, rash for 5 days, loose stools and altered sensorium on the day of admission. There is no history of significant tick/flea bite. The maculopapular type of rash was over the face, both extremities including palms (Figure 1) and soles and over abdomen (Figure2).

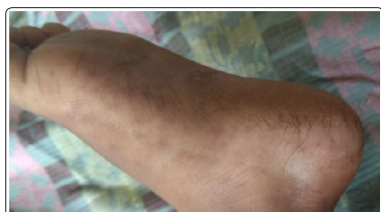

Figure 1: Showing rash over sole

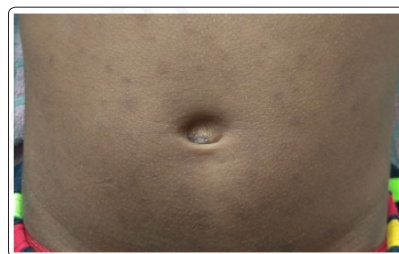


Figure 2: Showing rash over abdomen

Edema of both hands and feet present on admission, Conjunctivitis also noted on the day of admission. Liver was 3 cm; spleen was 2 cm below the costal margins. On examination child was in altered sensorium with severe irritability and significant menigismus. And no focal deficits and no cranial nerve palsies on admission. No evidence of Papilloedema on fundoscopy. Rathi, Goodman et al scoring 24 as noted on Admission (Table1). On Investigation Hemoglobin was 5.7 gram %, leukocyte count was 21,600 with 50 % polymorphs and 40% of Lymphocyte Peripheral blood smear for malaria parasite& Dengue Serology were negative. Initial blood sugars were 110 mg/dl and serum electrolytes and renal function tests were normal. Serum bilirubin is normal but Liver enzymes and Coagulation Profile was abnormal with increased enzymes SGPT is 499U/L, SGOT 105 U/L. CSF sample was obtained by Lumbar Puncture revealed WBC of 3 cells With no polymorphs and 100% lymphocytes glucose level of 35mg/dl and Protein level of 46mg/dl appears to be normal. Blood cultures for bacteria, fungi were negative.

**Table 1: Total RGA (Rathi, Good man et al) score for this child is 23/35 [6].**

Clinical Criteria	Scoring	Laboratory Criteria	Scoring
Rural	1	Hb % < 9 gr %	1
Pets	1	Platelet count <1,50,000	0
Tick Exposure	0	CRP > 50	0
Tick bite	0	Decreased S. Albumin	1
Conjunctival Congestion	2	Urine Albumin > 2	0
Maculopapular Rash	1	Raised SGPT	2
Purpura	2	Hyponatremia	0
Echymosis	3		
Rash	2		
Edema	2		
Rash on plams and soles	3		
Hepatomegaly	2		
Lymphadenopathy	0		
Total Clinical Score	19/25	Total Laboratory C.score	4/10

The patient was started on intravenous ceftriaxone (100mg/kg/day) in 2 divided doses and in view of characteristic rash and its distribution, possibility of rickettsial infection was considered and Started on Doxycycline 2.2mg/kg/Dose in 2 doses per day through feeding tube. He was Responded well to doxycycline after starting therapy.

His serum sent for Weil–Felix (WF) Test which was found positive with titers of 1:320 for OX-2, OX 19 and negative for OXK by Tube agglutination test.

## Discussion

Rickettsiae derive their name from the American researcher, Howard Ricketts, who discovered them in 1909 in Montana, USA, as the source of a serious disease [Rocky Mountain spotted fever (RMSF)]. He himself died from typhus in an epidemic in Mexico some years later. Rickettsiae multiply intracellularly. They have a Gram-negative cell wall structure, but cannot be detected by Gram staining, although they can be by Giemsa staining but with difficulty. The Cases of rickettsial infection have been documented mainly from South India [7-10]. The *R. conorii* was first described by Conor in 1910. In September 1932, at the First International Congress of Mediterranean Hygiene, the name Mediterranean spotted Fever was adopted. Other names given to this illness are Boutonneure fever, Kenya Tick-Bite Fever, African Tick Typhus, Indian Tick Typhus, Israeli Spotted fever and Marseilles fever, depending on the region [10]. *Rickettsia conorii* is an obligate intracellular parasite of Ticks [11]. In Mediterranean area, the vector is the brown dog tick *Rhipinecephalius sanguineus*, but other species of mites may act as vectors in other geographic areas [12].

Rickettsiae are wide spread in ticks and can parasitize many of their organs including ovaries, and hence can be transmitted transovarially. Thus ticks are not only vectors but also reservoir of infection; therefore physical contact with dogs is not necessary. The

initial bite passes unnoticed and in many cases the primary lesion/inoculation scar is not always present as in our case. The onset of disease is usually abrupt with headache, malaise and fever, lasting for 6–12days. Generalized myalgia, especially involving leg muscles and joint pain, is a prominent feature. The rash usually develops between 3<sup>rd</sup> and 5<sup>th</sup> febrile day with initial lesions appearing on extremities and spreading to trunk, neck, face, buttocks and palms in 24–36h.

The lesions are macular or Maculopapular and may be purpuric. Our patient had maculopapular rash with characteristic distribution. Severe involvement of CNS has been reported in adults with *R. conorii* infection but rarely in children [2-5]. Children present with various degree of impaired consciousness, delirium and convulsions. Neurologic sequelae have been observed. Our patient had no cerebrospinal fluid findings of meningoencephalitis. Other complications like pneumonia, myocarditis, acute respiratory distress syndrome, acute renal failure and disseminated intravascular coagulation have been reported.

*Rickettsia conorii* cannot be isolated from blood culture by routine laboratory procedure. The clinical features, geographic background and epidemiological considerations help to establish diagnosis. Laboratory diagnosis is an important adjunct and involves serologic identification of serum antibodies [13]. Diagnosis of rickettsial infection is mainly by serologic methods [14]. Indirect immunofluorescent assay is the reference diagnostic method for rickettsial infection, butcross-reacting antibodies of related isolates confound interpretation of the results and it becomes positive only in late phase of disease [15].

Western blot test is more sensitive than IFA test, and it is frequently positive in acute phase sera when antibodies cannot be detected by IFA [16].

Our child’s serum tested positive for Weil Felix Test (WF) at a dilution of 1:320 For OX 2. WF is inexpensive and can be performed rapidly to substantiate the diagnosis. However, low sensitivity of WF is a problem [17]. Even though the sensitivity of WF has been claimed less, there are Several reports suggesting good correlation Of WF Test with other standard tests used [18, 19]. In the study conducted in South India, the sensitivity of patient’s Antibody was 30% at a titer break point of 1:80, but specificity and positive predictive value were 100% [20]. Some authors have suggested that even though WF test is not a very sensitive test, it is quite a specific test when it is positive [21]. Thus WF test may be the only serological test available in developing countries like India. It can be used in confirming a tentative diagnosis of rickettsial fever mainly during acute phase of the disease when specific therapy can be lifesaving.

Doxycycline is the drug of choice. Other drugs are tetracycline, chloramphenicol, ciprofloxacin, azithromycin and clarithromycin [22]. The optimum duration of specific therapy has not been definitely established and different antibiotic regimens ranging from single dose to treatment for up to 15 days have been recommended. As our patient was critically ill, we used doxycycline 2.2 mg /kg/dose 2 doses per day for 10 days with which the child recovered well.

## Conclusion

In summary, early diagnosis of Rickettsial infections is important, as these Can be treated with in expensive antibiotics and can be fatal

if untreated. The availability and the cost of standard serological methods for *Rickettsia* are the major problems in developing countries like India. The diagnosis should be largely based on High index of suspicion and careful clinical, Laboratory and epidemiological evaluation Supported by cost-effective tests like WF.

## References

1. IAP Textbook of Pediatrics, 6<sup>th</sup> Edition (2016) 6: 347-349.
2. Charra B, Berrada J, Hachimi A, Judate I, Nejmi H, et al. (2005) A fatal case of Mediterranean spotted Fever. *Med Mal Infect* 35: 374-375.
3. Marcos Dolado A, Sanchez Portocarrero J, Jimenez Madrdejo R, Pontes Navarro JC, GarciaUrta D (1994) Meningoencephalitis due to *Rickettsia conorii*. Etiopathological, clinical and diagnostic aspects. *Neurologia* 9: 72-725.
4. Thijssen HS, Leroy PL, van't Hek LG, Hurkx GA (2004) An unsuspected imported disease: meningo-encephalitis contracted in Spain. *Ned Tijdschr Geneesk* 148:113-117.
5. Texier P, Rousselot JM, Quillerou D (1984) Mediterranean boutonuse fever. Apropos of a fatal Case in a new born infant. *Arch FrPediatri* 41: 51-53.
6. Pavithran S, Mathai E, Moses P(2004) ScrubTyphus Indian Pediatrics 45:1254-1256.
7. Mathai E, Lloyd G, Cherian T, Abraham OC, Cherian AM (2001) Serological evidence for the continued presence of human Rickettsioses in southern India. *Ann Trop Med Parasitol* 95: 395-398.
8. Mathai E, Rolain JM, Varghese GM (2003) Outbreak of scrub typhus in Southern India during the cooler months. *AnnNYAcadSci* 990: 359-364.
9. Murali N, Pillai S, Cherian T (2001) Rickettsial infections in South India—how to spot the spotted fever. *Indian Pediatrics* 38:1393-1396.
10. Morven S, Feigin RD (2004) Rickettsial diseases in textbook of pediatric infectious diseases. 5 thedn, Philadelphia: Saunders 2: 2497-2515.
11. Harris RL, Kaplan SL, Bradshaw MW (1986) Boutonuse fever in American travellers. *J Infect Dis* 153:126-128.
12. Montenegro MR, Mansueto S, Hegarty BC (1983) The histology of “tachesnoires” of boutonuse fever and demonstration of *Rickettsia conorii* in them by immunofluorescence. *VirchowsArch* 900: 309-317.
13. Kovacova, Kazar J (2000) Rickettsial diseases and their serological diagnosis. *ClinLab* 46: 239-245.
14. Parola P, Fenollar F, Badiaga S (2001) First documentation of *Rickettsia conorii* infection (strain Indian ticktyphus) in a traveler. *Emerg Infect Dis* 7: 909-910.
15. Lascola B, Raoult D (1997) Laboratory diagnosis of rickettsioses: current approaches to diagnosis of old and new rickettsial diseases. *JClinMicrobiol* 35: 2715-2727.
16. Bhattacharya D, Mittal V, Bhatia R (1991) Comparison between indirect fluorescent antibody and Weil-Felix tests for detecting antibodies against rickettsia. *J Commun Dis* 23:144-148.
17. Amano K, Suzuki N, Fujita M (1993) Serological reactivity of sera from scrub typhus patient against WF test antigens. *Microbiol Immunol* 37: 927-933.
18. Amano K, Suzuki N, Fujita M Thereactivity between Rickettsial and WF test antigens against sera Of Rickettsial disease patients. *Acta Virol* 33: 67-72.
19. Isaac R, Varghese GM, Mathai E (2004) Scrubtyphus: prevalence and diagnostic issues in rural southern India. *Clin Infect Dis* 39:1395-1396.
20. Saah AJ (2000) *Orientia tsutsugamushi* (scrubtyphus)s In: Mandell GL, Bennet GE, Doalin R (eds). *Principals and practice of infectious diseases*. Philadelphia: Churchill Livingstone pp.2056-2057.
21. Gross EM, Yagupsky P, Torok V (1982) Resurgence of Mediterranean spotted fever. *Lancet* 2:1107.
22. IAP Guidelines on Rickettsial Diseases In Children Narendra Rathi,\*Atul Kulkarni And# Vijay Yewale (2017) For Indian Academy Of Pediatrics Guidelines On Rickettsial Diseases In Children Committee. *Indian Pediatrics* 54.

**Copyright:** ©2019 Naresh Gadagani. This is an open-access article distributed under the terms of the Creative Commons Attribution License, which permits unrestricted use, distribution, and reproduction in any medium, provided the original author and source are credited.