

## A Case of Small Intestinal Perforation During Neoadjuvant Chemotherapy for Locally Advanced Rectal Cancer

Ziqiang Wang

Department of Gastrointestinal Surgery, West China Hospital, Sichuan University, Chengdu, China.

### \*Corresponding author

Ziqiang Wang, Department of Gastrointestinal Surgery, West China Hospital, Sichuan University, Chengdu, China.

Submitted: 25 Mar 2022; Accepted: 02 Apr 2022; Published: 14 Apr 2022

**Citation:** Ziqiang Wang (2022) A Case of Small Intestinal Perforation During Neoadjuvant Chemotherapy for Locally Advanced Rectal Cancer. *J Addict Res* 6(1): 175-179.

### Abstract

**Background:** For patients with locally advanced rectal cancer, side effects such as nausea, vomiting and loss of appetite may occur during neoadjuvant chemotherapy, but small intestinal perforation is very rare.

**Case:** We present a case of a 62-year-old man who suffered small intestinal perforation in the first cycle neoadjuvant treatment of locally advanced rectal cancer with capecitabine and oxaliplatin. Six days after the start of neoadjuvant chemotherapy, he began to develop intermittent abdominal pain, accompanied by diarrhea and abdominal distension. The CT scan revealed an abscess with free air in the pelvic cavity with proximal intestinal ileus. Then we performed a laparotomy. After enterolysis, the rectum with tumor was carefully examined with no perforative lesion, and the terminal ileum about 15cm from the ileocecum which adhere to the pelvic abscess had one about 0.8cm ulcer. The patient had a radical anterior resection and the morbid small bowel resection with protective ileostomy. The postoperative pathological examination showed the full-thickness necrosis of the intestinal wall in the ileal lesion with peripheral acute suppurative inflammation. AND the final pathological stage of the tumor was pT3N0M0 (American Joint Committee on Cancer, eighth edition).

**Conclusion:** As a chemotherapy regimen based on fluorouracil and oxaliplatin, small intestinal perforation is a very rare complication. The most common complications of these two drugs are gastrointestinal symptoms such as diarrhea. Therefore, when the complications are not relieved during chemotherapy, we should think of a more serious possibility.

**Keywords:** Intestinal Perforation; Drug Therapy; Neoadjuvant Therapy; Rectal Cancer; 5-Fluorouracil; Oxaliplatin.

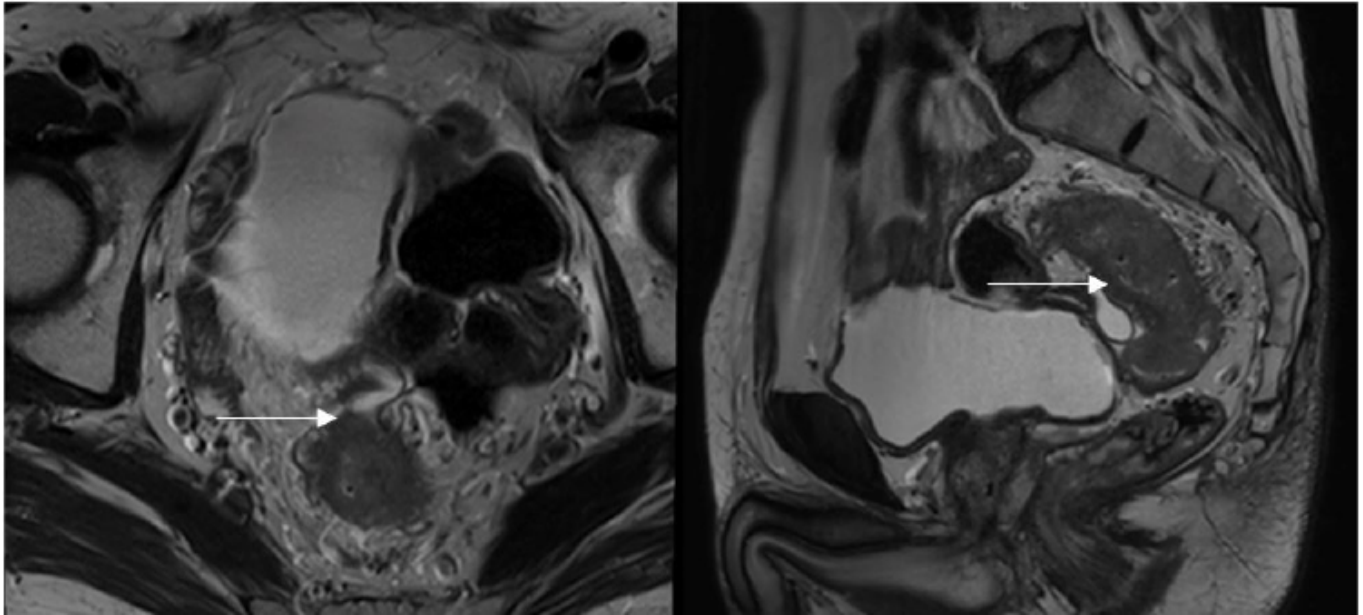
### Back Ground:

Colorectal cancer has the third highest incidence of all malignant tumors all over the world and the therapy model has made greater progress at the same time [1]. Neoadjuvant chemotherapy (NAC) is a routine method for the treatment of locally advanced rectal cancer. The first-line chemotherapy regimen consists of 5-fluorouracil (5-FU) and oxaliplatin. 5-FU, an analog of uracil, is transported into cells by the same mechanism as uracil. Then, it inhibits thymidylate synthase, incorporates into RNA and DNA, and induces cell death pathways in rapidly growing cancer cells [2]. Oxaliplatin antagonizes replication and transcription of circular double-stranded DNA with multiple targets [3]. Their side effects include nausea, vomiting, diarrhea, peripheral neurotoxicity, hand-foot syndrome, myelosuppression and so on. However, small intestinal perforation caused by these drugs have never been reported. We report a case of small intestinal perforation in a patient with locally advanced rectal cancer during neoadjuvant therapy. After an extensive liter-

ature search, we have not found any cases of small intestinal perforation reported during the treatment of locally advanced rectal cancer with neoadjuvant chemotherapy based on these drugs. We propose that this rare complication is also worthy of our attention.

### Case presentation

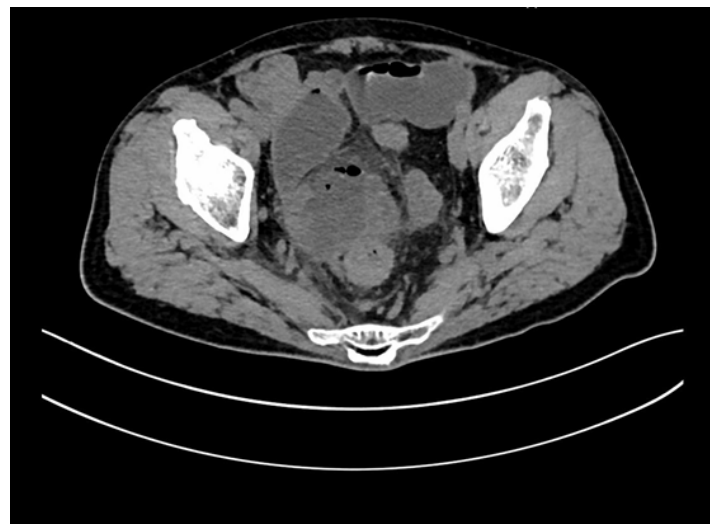A 62-year-old male was diagnosed with locally advanced rectal cancer due to hematochezia. colonoscopy found an ulcerative neoplasm on the rectum 8cm away from the anus with the biopsy showed rectal adenocarcinoma. In to the further tumor stage evaluation, the chest-abdominal CT, rectal high-resolution MRI and transanal ultrasound showed the TNM classification was low-intermediate risk cT4aN0M0, stage II (figure 1) according to the ESMO guideline [4]. His CA-199 was 7.97U/ml and CEA was 3.01ng/ml. He had no history of digestive tract ulcers or hypertension.



**Figure 1:** MRI showed that the tumor was located in the upper part of the rectum and the tumor signal broke through the visceral layer of the peritoneum (white arrow. transverse section on the left and sagittal section on the right).

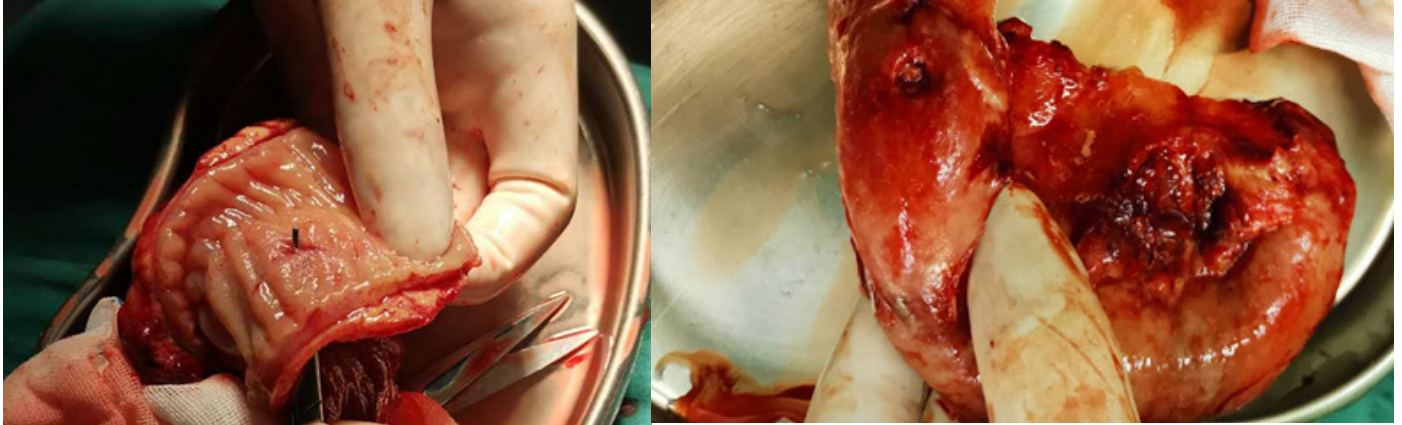
As our previous trial show shows the radiation may not benefit this low risk patients [5]. The neoadjuvant chemotherapy was suggested, with informed consent of the patient and excluding the contraindications to chemotherapy, the first cycle of NAC CAPEOX (oxaliplatin 190mg iv day1 and capecitabine 1500mg twice a day d1-d14) was initiated . Six days later, the patient developed intermittent abdominal pain, accompanied by diarrhea and abdominal distension gradually. He didn't pay too much attention at first. However, the symptoms had not alleviated at all in the next four days. Then, he stopped the capecitabine and presented to the Emergency Department. The abdomen was slightly distending the lower abdomen was deep tenderness, mild rebound pain, and the bowel sounds were active. The blood test showed WBC was 11.36 /nl. the CT scan revealed an abscess with free air in the pelvic cavity with proximal intestinal ileus. (Figure 2). Rectal cancer perforation was considered, and laparotomy was employed. In the operation, an abscess was found in the pelvic cavity surrounded by the rectum and small intestine and pelvic wall. After enterolysis, the rectum with tumor was carefully examined with no perforative lesion, and the terminal ileum about 15cm from the ileocecum which adhere to the pelvic abscess had one about 0.8cm ulcer (Figure 3), and the intestinal wall was extremely thin, which was considered as small intestinal perforation during chemotherapy. The patient had a radical anterior resection and the morbid small bowel resection with protective ileostomy. The postoperative pathological examination showed the full-thickness necrosis of the intestinal wall in the ileal lesion with peripheral acute suppurative inflammation (Figure

4). And the final pathological stage of the tumor was pT3N0M0 (American Joint Committee on Cancer, eighth edition) (Figure 5). The patient recovered smoothly after the operation and been discharged 8 days after operation. Currently, he has given two further cycles of adjuvant chemotherapy with capecitabine and oxaliplatin with no episode.

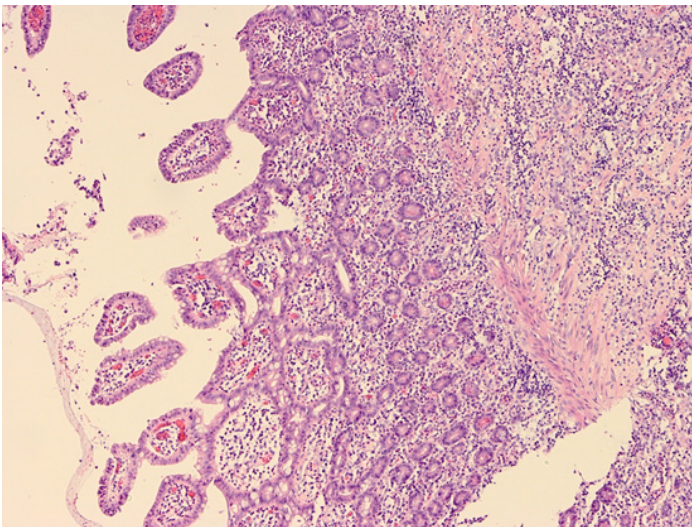


**Figure 2.** CT scan detecting a low density encapsulated fluid accumulation area in the right lower abdomen, in which a small amount of free gas could be seen(White arrow).

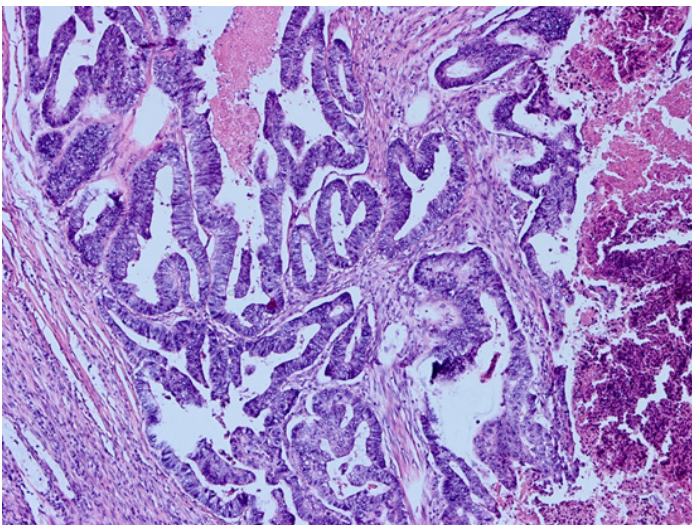




**Figure 3:** These two photos showed the site of small intestinal perforation during the operation (White arrow).



**Figure 4:** Pathological examination. The picture was the perforated site, a large number of inflammatory cells and necrotic tissue were seen.



**Figure 5:** Pathological examination. The picture was tumor cells with moderate degree of degeneration.

### Discussion

We present a case of small intestine perforation in the first cycle neoadjuvant treatment of stage II locally advanced rectal cancer with capecitabine and oxaliplatin. Intestinal perforation caused by these two chemotherapeutic drugs has never been reported before. So that, this should be the first time that we are aware of the rare complication of intestinal perforation during neoadjuvant chemotherapy for rectal cancer. According to the research of Michael et al [6] intestinal perforation most often occurs at the site of the tumor in 64.3% and 23.5% with small bowel and colon during corticosteroid treatment or chemotherapy, respectively [6]. This potentially lethal complication is defined as spontaneous perforation. And spontaneous intestinal perforation outside the location of the tumor was relatively rare. In the previously published literatures, we have not seen any reports of intestinal perforation caused by capecitabine or oxaliplatin. Especially in this case, the perforation did not occur near the primary tumor, but the intestinal contents spread directly to the tumor surface after the perforation.

5-FU, one of the most widely used chemotherapies to treat malignant tumors, interferes with DNA synthesis by inhibiting thymidylate synthase, and by incorporation of its metabolites into RNA and DNA [7]. Diarrhea is a well-known, dose-dependent side effect of the treatment with this drug. Some researchers presented terminal ileitis as a rare adverse event of 5-FU treatment [8-11]. This mechanism may be related to directly induce apoptosis via TNF- $\alpha$  and to suppress intestinal cell proliferation, thereby resulting in degradation of the epithelial barrier, as well as in secondary inflammation mediated by inflammatory cytokines [12]. A previous case of 5-FU-associated small bowel vasculitis due to arterial ischemia has also been reported [13]. Therefore, we speculate that the small intestinal perforation in this case may be on the basis of intestinal epithelial mucosal necrosis and blood vessels ischemia caused by capecitabine. Of course, the rarer complication of perforation directly caused by it cannot be ruled out. This needs to be verified by further research.

Oxaliplatin can also cause diarrhea. Previous studies had found that cisplatin-induced inflammation of ileal mucosa was related

to the induction of cyclooxygenase-2, and oxaliplatin may have a similar effect, although no studies have confirmed it. In patients treated with the combination of capecitabine and oxaliplatin, grade 3–4 diarrhea occurs in approximately 18% of cases, which was higher than the incidence of capecitabine monotherapy [14–16]. It is suggested that capecitabine combined with oxaliplatin has a synergistic effect on intestinal mucosal inflammation during chemotherapy for rectal cancer. So it will increase the potential risk of perforation.

It was previously reported that the perforation of rectal cancer during chemotherapy was related to bevacizumab [17–21]. Reported 60 (5.9%) experienced complications necessitating surgery after bevacizumab therapy and gastrointestinal perforation was the most frequently observed complication in 36(60%) patients, the mechanism of bowel perforation caused by the VEGF-targeted therapy is still uncertain and it is possible that excessive VEGF inhibition contributes directly to GI perforation by inducing regression of normal blood vessels in the GI tract [22, 23]. Capecitabine and oxaliplatin may aggravate this process.

In this case, the patient had intermittent abdominal pain and abdominal distension in the early stage, and the result of abdominal palpation was a localized sign of peritonitis, which may indicated such a complication. However, in our inherent thinking, we always thought that the perforation should occur in the tumor site. So, this case suggests that patients who receive first-line chemotherapy on the basis of 5-FU and oxaliplatin for rectal cancer are also at risk of intestinal perforation at the non-tumor site. If some common side effects of chemotherapy, such as diarrhea and abdominal pain did not relieve for a long time, we should not simply suspect diseases such as enteritis or gastrointestinal intolerance to chemotherapy drugs. Some rare complications such as intestinal perforation should also be paid attention in order to avoid serious consequences.

## References

1. Freddie Bray, Hyuna Sung, Jacques Ferlay, Rebecca L Siegel, Mathieu Laversanne, et al. (2021). Global cancer statistics 2018: GLOBOCAN estimates of incidence and mortality worldwide for 36 cancers in 185 countries. *CA Cancer J Clin* 68: 394-424.
2. DA Som Kim, Kyoungmi Min, Suk Kyeong Lee (2020). Cell Cycle Dysregulation Is Associated with 5-Fluorouracil Resistance in Gastric Cancer Cells. *Anticancer Res* 40: 3247-3254.
3. Leipeng Li, Ruisi Liu, Fengjie Xu, Yuangang Zu, Zhiguo Liu (2015). Study on the interactions between anti-cancer drug oxaliplatin and DNA by atomic force microscopy. *Micron* 76: 46-51.
4. R Glynne-Jones, L Wyrwicz, E Tiret, G Brown, C Rödel, et al. (2017). Rectal cancer: ESMO Clinical Practice Guidelines for diagnosis, treatment and follow-up. *Annals of Oncology* 28:22-40.
5. Xiangbing Deng, Ping Liu, Dan Jiang, Mingtian Wei, Xin Wang, et al. (2020). Neoadjuvant Radiotherapy Versus Surgery Alone for Stage II/III Mid-Low Rectal Cancer with or Without High-Risk Factors: A Prospective Multicenter Stratified Randomized Trial. *Ann Surg* 272: 1060-1069.
6. Torosian MH and ADM Turnbull (1988). Emergency Laparotomy for Spontaneous Intestinal and Colonic Perforations in Cancer Patients Receiving Corticosteroids and Chemotherapy. *J Clin Oncol* 6: 291-296.
7. Longley DB, DP Harkin and PG Johnston (2003). 5-fluorouracil: mechanisms of action and clinical strategies. *Nat Rev Cancer* 3: 330-338.
8. Irene E G van Hellemond, Annemarie M Thijs, Geert-Jan Creemers (2018). Capecitabine-Associated Terminal Ileitis. *Case Rep Oncol* 11: 654-659.
9. Taimoor Khan, Mohamed Mujtaba, Marcus S Flores, Kenneth Nahum, Michael P Carson (2019). A Case of Pneumatosis Intestinalis with Pneumoperitoneum as a Potential Delayed Adverse Effect of Capecitabine. *World J Oncol* 10: 151-152.
10. Shing Fung Lee, Chi Leung Chiang, Ann Shing Lee, Frank Chi Shing Wong, Stewart Yuk Tung (2015). Severe ileitis associated with capecitabine: Two case reports and review of the literature. *Mol Clin Oncol* 3: 1398-1400.
11. L Nicosia, I Russo, V de Sanctis, G Minniti, M Valeriani, et al. (2018). Two Cases of Capecitabine-Induced Ileitis in Patients Treated with Radiochemotherapy to the Pelvis and Review of the Literature. *J Gastrointest Cancer* 49: 538-542.
12. Nahla Hamouda, Tatsushi Sano, Yosuke Oikawa, Toru Ozaki, Masaki Shimakawa, et al. (2017). Apoptosis, Dysbiosis and Expression of Inflammatory Cytokines Are Sequential Events in the Development of 5-Fluorouracil-Induced Intestinal Mucositis in Mice. *Basic Clin Pharmacol Toxicol* 121: 159-168.
13. Uzair B Chaudhary, Jason D Taksey, R Duren Johnson, David N Lewin (2003). Small-cell cancers, and an unusual reaction to chemotherapy *J Clin Oncol* 21: 2441-2442.
14. Ion D Bucaloiu, Srinivasan Dubagunta, Krishna K Pachipala, Nazmi Kamal, Farid Fata (2003). Case 4. Fluorouracil-related small bowel vasculitis. *J Clin Oncol* 21: 2442-2443.
15. Yusuke Obara, Takuji Machida, Yuho Takano, Saki Shiga, Asami Suzuki, et al. (2018). Cisplatin increases the number of enterochromaffin cells containing substance P in rat intestine. *Naunyn Schmiedeberg Arch Pharmacol* 391: 847-858.
16. Roberto Iacovelli, Filippo Pietrantonio, Antonella Palazzo, Claudia Maggi, Francesca Ricchini, et al. (2014). Incidence and relative risk of grade 3 and 4 diarrhoea in patients treated with capecitabine or 5-fluorouracil: a meta-analysis of published trials. *Br J Clin Pharmacol* 78: 1228-1237.
17. R Baird, A Biondo, V Chhaya, J McLachlan, A Karpathakis, et al. (2011). Toxicity associated with capecitabine plus oxaliplatin in colorectal cancer before and after an institutional policy of capecitabine dose reduction. *Br J Cancer* 104: 43-50.
18. Fairooz F Kabbinavar, Joseph Schulz, Michael McCleod, Taral Patel, John T Hamm, et al. (2005). Addition of bevacizumab to bolus fluorouracil and leucovorin in first-line metastatic colorectal cancer: results of a randomized phase II trial.



19. Rui-Hua Xu, Kei Muro, Satoshi Morita, Satoru Iwasa, Sae Won Han, et al. (2018). Modified XELIRI (capecitabine plus irinotecan) versus FOLFIRI (leucovorin, fluorouracil, and irinotecan), both either with or without bevacizumab, as second-line therapy for metastatic colorectal cancer (AXEPT): a multicentre, open-label, randomised, non-inferiority, phase 3 trial. *The Lancet Oncology* 19: 660-671.
20. Satoshi Takada, Yoshinori Hoshino, Homare Ito, Yohei Masugi, Toshiaki Terauchi, et al. (2015). Extensive bowel necrosis related to bevacizumab in metastatic rectal cancer patient: a case report and review of literature. *Jpn J Clin Oncol* 45: 286-290.
21. Michaela Jung, Annica Holmqvist, Xiao-Feng Sun, Maria Albertsson (2014). A clinical study of metastasized rectal cancer treatment: assessing a multimodal approach. *Med Oncol* 31: 839.
22. Liu SV, R Gollard and S Iqbal (2012). Case report of perforation of an ileal neobladder after treatment of rectal cancer with bevacizumab and comment on mechanisms of intestinal perforation associated with bevacizumab. *J Clin Pharm Ther* 37: 607-609.
23. Jun Woo Bong, Jong Lyul Lee, Chan Wook Kim, Yong Sik Yoon, In Ja Park, et al. (2018). Risk Factors and Adequate Management for Complications of Bevacizumab Treatment Requiring Surgical Intervention in Patients with Metastatic Colorectal Cancer. *Clin Colorectal Cancer* 17: 639-645.
24. Tomomi Kamba, Betty Y Y Tam, Hiroya Hashizume, Amy Haskell, Barbara Sennino, et al. (2006). VEGF-dependent plasticity of fenestrated capillaries in the normal adult microvasculature. *Am J Physiol Heart Circ Physiol* 290: 560-576.

**Copyright:** ©2021 Ziqiang Wang. This is an open-access article distributed under the terms of the Creative Commons Attribution License, which permits unrestricted use, distribution, and reproduction in any medium, provided the original author and source are credited.