

A Case of Neurological Manifestations Accompanying Generalized Tuberculosis

Najada Como¹, Esmeralda Meta¹, Drini Dobi², Dhimiter Kraja¹ and Arjan Harxhi¹¹Infectious Diseases Clinic²Neurology Clinic, UHC "Mother Theresa", Tirane, Albania***Corresponding author**

Esmeralda Meta, Infectious Diseases Clinic, Albania, E-mail: esmeraldameta@yahoo.com

Submitted: 23 Jan 2018; **Accepted:** 30 Jan 2018; **Published:** 10 Feb 2018**Abstract**

Tuberculosis (TB), a multisystemic disease with variety presentations and manifestations, is the most common cause of infectious disease-related mortality worldwide [1]. A 23-year-old, male, is admitted to the Infectious diseases clinic "Mother Theresa" hospital in Tirana, after one year intermittent FUO and exudative pleural effusion treated first in Albania and then Italy. He had fever, back pain, muscular weakness, difficulty walking, urinary retention. In chest x ray radiological examination, CT scan of thorax and MRI of spinal cord are seen military form lesions, and vertebral destructions that raise suspicion of a possible pulmonary and extra pulmonary TB. The patient's condition is randomly assigned to the beginning of antitubercular therapy (ATT), manifesting disturbance of conscience and coma. LCS results with 50 cells / mm³ and the CT scan of head detects hydrocephalus; funduscopia detected papilledema on 1st stage; which mean that the case is complicated with TB meningitis. The patient passes to the intensive care unit where ATT tapered cortisone, CNS diuretics and supportive therapy. After a week the patient comes out of the coma, begins his clinical improvement, but the neurological consequences of hydrocephaly and paraplegia become clearer. Two months later the patient was better clinically, walking with support. Peripheral neurological deficits persisted up to 10 months after leaving the hospital but with progressive improvement.

The best ways to reduce mortality and morbidity associated with TBM are the timely diagnosis.

Keywords: TB meningitis, Pulmonary TB, Spondylodiscitis, Albania

Introduction

Tuberculosis (TB) is one of the top 10 causes of death worldwide. In 2016, 10.4 million people fell ill with TB, and 1.7 million died from the disease (including 0.4 million among people with HIV) [1]. About one-quarter of the world's population has latent TB, which means people have been infected by TB bacteria but are not (yet) ill with the disease and cannot transmit the disease. In Albania till 2016 accounted 408 cases with TB, notification rate per 100 000 is 14.1%.

260 of them were pulmonary form of TB and 61 cases are co infected HIV -TB (based on Institute of Public Health data) [2,3]. Nearly 3 decades, TB was eradicated in Albania after 1990 as a result of the free movement of the population outside the borders, and the emergence of HIV as a new infection, TB re-emerged with an increasing trend of cases, as mono-infection or associated in HIV-positive persons.

TB has high morbidity and mortality if it is not diagnosed and timely treated. Cerebral manifestations and spinal TB have higher severity gravitation mainly in children and adolescents [1,4]. In HIV positive subjects this risk is 20 to 37 times higher. Pulmonary TB can be complicated with spinal TB and/or meningeal TB, leading to

neurological cascades; such as hydrocephalus, cranial nerve deficit, paralysis, visual disorder, SIHAD syndrome, convulsions, hearing disorders [5,6]. In our case we discussed meningeal TB and spinal TB after 1 year intermittent FUO, complicated with hydrocephaly and paraesthesia

Case Presentation

A 23 year old male, presented in Infectious diseases clinic of "Mother Theresa" hospital Tirana with prolonged intermittent fever, for about 1 year. He referred to high temperature episodes, in June, two years ago, when he had the first episode. It was conceived as the right exudative pleurisy and treated with non steroid anti inflammatory drugs (NSAID); eight months later, in January, he repeatedly displayed a fever and in the next hospitalization, now in Naples / Italy records the left exudative pleurisy but did not give details of the treatment. In April, when he came in our clinic, he referred to the third episode of temperature, up to 39°C, fatigue, sweat, myalgia and back pain.

In admission was pale - looking, tired, vital signs normal, without neck rigidity. Cerebral functions and cranial nerve were normal. There was a decrease in sensitivity in the lower extremities. We did not distinguish cerebellar signal present such as (scanning speech, intention tremors, past pointing, nystagmus). There was no history of cardiac, genitourinary, gastrointestinal, or musculoskeletal abnormality, or TB in his family.

Meanwhile the patient began to show bodily weakness (unable to climb the stairs), the urinary retention, for which is catheterized.

Initial examinations showed a normal leukocyte count. Renal function tests, electrolytes were normal, the liver function test over twice the normal range. Erythrocyte sedimentation rate was 45 mm. Serological test for HIV, Wright, Widal and Weil Felix came back negative.

His chest x ray showed numerous military form lesions disseminated in both lungs. We performed CT scan of the thorax that supported the suspicion of disseminate TB, without pleural fluid. The bone excision of the T11-T12 vertebral bodies (spondilodiscit) was observed. MRI of vertebral column evidenced alterations in the intervertebral disc T11-T12 and in the neighboring vertebral bodies with dissection / spondilodiscitis. Spinal canal without medullary compression. Quantiferon γ was positive. He was started therapy on anti tuberculous treatment (ATT) isoniasid, rifampicin, etambutol, pyrazinamide.

The patient is transferred to the pneumology institute, where pulmonary TB cases are managed. After 5 days the patient's situation is sorted. High temperature persists, initially manifested with conscience disturbances, unpredictable in time and space, did not react to physical stimuli. The stiffness, photosensitivity, Brudzinski and Kernig signs were positive.

In Ct scan of the head realized in this new situation, resulted hydrocephalus and the fundusocopia detects papilledeme of Ist stage. LCS resulted with 50 cel / mm³. Lymphocytic pleocytosis was also seen. Myas reticulum - positive. The CSF examination revealed a raised CSF protein and a low glucose level of 40 mg / dl (reference range was 70 to 110 mg / ml). Microscopy of LCS for TB was negative, while culture positive. The case is transferred again to the Intensive care unit of Infectious diseases hospital "Mother Theresa". He remained in coma for the next five days. The situation began to be further improved.

In neurological examination: osteotendinosis reflexes were symmetric present. Hypoesthesia of left scrotum, motor deficiency of lower limbs, paraplegia. In the CT scan of the head (check) one month later - the lateral ventricular dilation was detected, hydrocephaly; as well as a hypodens lesion near the caudate dexter nucleus.

In addition to first line of ATT preparations, was added cortisone (dexamethasone 32 mg / daily dose, progressively decreasing and diuretic drugs, hydrochlortiazide, mannitol, diamox) Rehabilitation through physiotherapy as well as the treatment of plastic surgery of decubitus began. After two months he could walk with support.

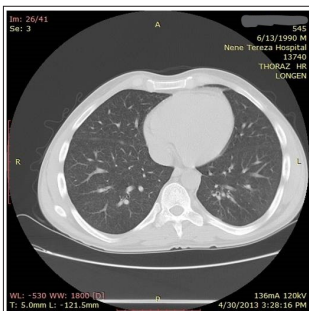


Image 1: CT scan of thorax: Supports suspicion of TB disseminating, left broncektasia, without pleural fluid. Bone excision in the vertebrate bodies T11-T12 (spondilodiscit)

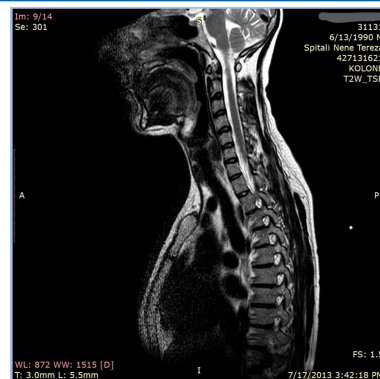
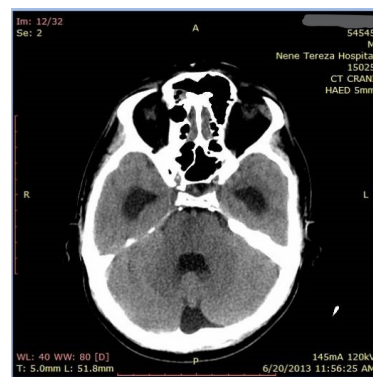


Image 2: MRI of spinal cord : Changes in the intervertebral disc T11-T12 and in the neighboring vertebral bodies with spondilodiscitis aspect.



Images 3: CT scan of head (recontrol) - Dilation of lateral ventricles. Hydrocephaly present. It is seen lesion hypodens near nucleus caudat dexter.

Discussion

Tuberculosis is a multisystemic disease with myriad presentations and manifestations, The lungs are the most common site for the development of TB; 85% of patients with TB present with pulmonary complaints [6,7]. Extrapulmonary TB can occur as part of a primary or late, generalized infection. Neurological complications of pulmonary and extrapulmonary TB are frequent and of high gravity.

Signs and symptoms of our patient suggest a generalized form of tuberculosis, with pleural infiltration, which is related to bilateral exudate in the first two episodes of temperature.

Back pain and decreased reflexes in the lower limbs associated with urinary retention are related to the infiltration of the vertebral column and the development of spondylodiscit which are confirmed through CT scan and MRI; where the destruction of the intervertebral disks and the vertebral body is concluded. TB meningitis was the most serious form of complications developed on our patient, accompanied by hydrocephalus.

The consequences remain approximately 10 months after leaving the hospital

Conclusion

TB generalized with multi-organ infiltration is not very common. is among the major causes of an FUO and when there is no epidemiological linkage to possible TB.

Short-term and especially long-term complications increase the gravity of the disease, and the neurological consequences [8,9].

Diagnosis and timely treatment as well as combined ATT treatment with corticotherapy and diuretics drugs improve the clinical and progression neurological complications of TB.

References

1. WHO Global tuberculosis report.
2. Tuberculosis surveillance and monitoring in Europe 2016-Albania Report.
3. Institute of Public Health “Draft on HIV / AIDS”.
4. Thomas E Herchline, Michael Stuart Bronze (2017) Tuberculosis (TB), Medscape.
5. Murthy JM (2010) Tuberculous meningitis: the challenges.. *Neurol India*. 58: 716-722.
6. Verma R, Patil TB, Lalla R (2012) Disseminated tuberculosis manifesting as pulmonary, meningeal and spinal tuberculosis in an immunocompetent patient.
7. AE, Reynolds AS, Gialdini G (2017) Neurological complications after tuberculous meningitis in a multi-state cohort in the United States. *Merkler Sci* 375: 460-463.
8. Leonard JM (2017) Central nervous system tuberculosis. *Microbiol Spectr* 5.
9. Prasad K, Singh MB, Ryan H (2016) Corticosteroids for managing tuberculous meningitis. *Cochrane Database Syst Rev* 4.

Copyright: ©2018 Esmeralda Meta, et al. This is an open-access article distributed under the terms of the Creative Commons Attribution License, which permits unrestricted use, distribution, and reproduction in any medium, provided the original author and source are credited.