

# The Diagnostic Yield of Upper GI Endoscopy in Patients Iron Deficiency Anemia and/or Chronic Diarrhea

Voulgaris T\*, Tampaki M, Laoudi E, Karatzas P, Karamanolis G, Vlachogiannakos J, Papaxoinis K, Kamberoglou D and Papatheodoridis G

Academic Department of Hepatology and Gastroenterology,  
National and Kapodistrian University of Athens, Greece

## \*Corresponding Author

Voulgaris Theodoros, Academic Department of Hepatology and Gastroenterology, National and Kapodistrian University, Greece.

Submitted: 2023, Dec 12; Accepted: 2023, Dec 22; Published: 2024, Jan 03

**Citation:** Voulgaris, T., Tampaki, M., Laoudi, E., Karatzas, P., Karamanolis, G., et al. (2024). The Diagnostic Yield of Upper GI Endoscopy in Patients Iron Deficiency Anemia and/or Chronic Diarrhea. *J Gastro & Digestive Systems*, 8(1), 01-05.

## Abstract

**Aim of the study:** According to published guidelines, an upper gastrointestinal (GI) endoscopy with duodenal biopsy sampling should be performed in patients with iron deficiency anemia (IDA) and/or chronic diarrhea. The cost-effectiveness of this strategy in the absence of obvious endoscopic reason explaining patients' symptoms has not been thoroughly investigated. Aim of our study was to access the clinical benefit of such a strategy.

**Patients-Methods:** All patients who underwent an upper GI endoscopy in our department due to IDA and/or chronic diarrhea during a 5-year period (1/2015-12/2019) were included in our study. Epidemiological, endoscopic and histologic data were analyzed.

**Results:** The indication for endoscopy was IDA in 350 and chronic diarrhea in 108 patients; histological reports were available in 311 and 100 patients, respectively. Visual abnormalities were observed in 157 patients (34.3% in total; IDA: 32.9%, chronic diarrhea: 38.9%) and were more frequent among males than females (44.6% vs 33.5%,  $p=0.019$ ) and among older patients (mean age 60 vs 56 years old,  $p=0.006$ ). The histology report provided a conclusive diagnosis in 71/413 patients (17.2% in total; IDA: 14.8 %, chronic diarrhea: 25%). Celiac disease (CD) was diagnosed in 7.5% of our total study group. Normal endoscopic appearance of the duodenum was observed in 33% of patients, while bulb atrophy was associated more frequently with a conclusive histological report compared to other or no endoscopic findings (23/63 or 36.5% vs 48/350 or 13.7%,  $p<0.001$ ).

**Conclusions:** Duodenal biopsy can aid significantly in the diagnosis of IDA or chronic diarrhea, even among patients without endoscopically abnormalities. Duodenal atrophy is an endoscopic marker that may lead to a conclusive histological diagnosis, most commonly CD, in 1 out of 3 patients.

**Keywords:** Upper GI Endoscopy, Chronic Diarrhea, Iron Deficient Anemia, Celiac Disease

## 1. Introduction

Upper Gastro-Intestinal (GI) endoscopy plays a cardinal role in the diagnostic algorithm of both anemia due to iron deficiency (IDA) and chronic diarrhea [1,2]. Even if duodenal biopsies are often performed routinely in patients being submitted to upper GI endoscopy due to IDA or chronic diarrhea, there is no robust data behind this practice [3]. The rationality behind such a practice resides mainly to the fact that celiac disease (CD) is responsible for a great proportion of patients with either IDA or chronic diarrhea [4]. This is also reinforced by the absence of visual abnormalities of the small intestine during upper GI endoscopy in up to 1/3 of patients with CD. Therefore, small bowel biopsies (SBB) may add to the diagnostic value of upper GI endoscopy towards a possible diagnosis of CD [4].

As far as IDA is concerned the data are conflicting. Few guidelines address this issue. According to the British guidelines for IDA, SBB should be obtained only if celiac serology was previously tested positive or not performed, while SBB should be obtained irrespective of serology in the presence of anemia or diarrhea according to the British guidelines for CD [1,5]. On the other hand, the ACG clinical guidelines for CD recommend routine SBB only when the probability for CD is at least 5% [6]. Thus, controversies about the exact prerequisites of obtaining SBB in the setting of IDA exist and the majority of studies focus in CD as this is main causative factor, though other diseases causing IDA can be diagnosed by duodenal SBB as well. Chronic diarrhea on the other hand is a common disorder affecting about 4-5% of Western population and CD is only one of its

many causes [7].

According to guidelines, upper GI endoscopy with SBB may be undertaken in patients with undetermined causative factor by laboratory studies, stool exams and lower GI endoscopy [8]. However, the additive benefit of SBB in the diagnostic pathway of chronic diarrhea has not been thoroughly investigated and biopsy sampling remains to medical practitioner' suspicion and mainly confers just to the diagnosis of celiac disease [8]. In addition, besides studies addressing the prevalence of CD among patients with chronic diarrhea, there is paucity of data about the value of duodenal biopsy sampling. Given that SBB are routinely performed in patients undergoing upper GI endoscopy for IDA and/or chronic diarrhea, the aim of our study was to evaluate the clinical significance of duodenal sampling in such patients in a real-world setting.

## 2. Methods

We retrospectively collected data from all patients submitted to upper GI endoscopy with SBB sampling in our department during a five-year period (1/2015-12/2019). In total, 458 patients were included in the study, whereas histological report was available in 413 patients. Epidemiological, endoscopic and histological data were collected. The study protocol conformed to the principles outlined in the Declaration of Helsinki. All patients signed an informed consent to undergo upper GI endoscopy. Since this study was a post hoc analysis of de-identified previously collected data from endoscopic studies with no direct link to individual patients, formal ethics approval and specific informed consent were not deemed to be necessary. All endoscopies were performed by endoscopists with more than 3 years' experience by the use of Olympus GIF-160 Adult Video Gastroscope with standard white balance analysis. A diagnosis

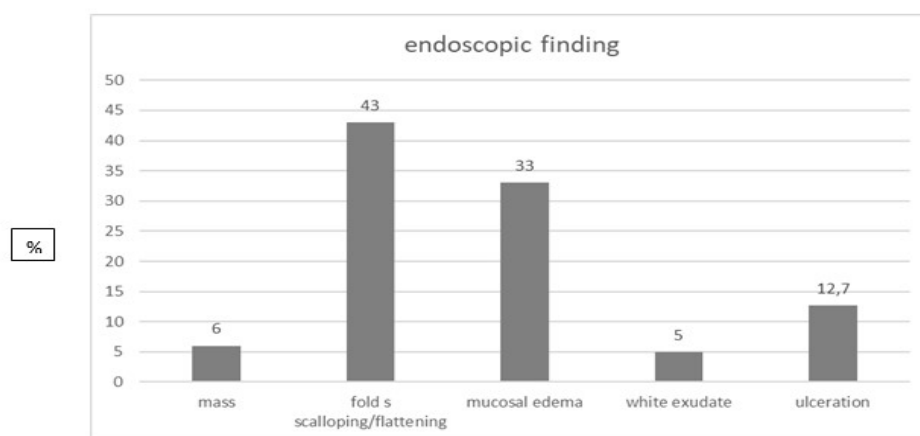
of celiac disease was made in patients with at least a Marsh III stage according to Marsh Overhear classification in the histology report. Statistical analysis was performed using SPSS software (version 27.0, IBM Corp., Armonk, NY, USA). Data were expressed as frequencies, mean with standard deviation (SD) or median with interquartile range (IQR), as appropriate. Quantitative variables were compared with Student's t-test or Mann-Whitney test for normally and non-normally distributed variables, respectively. Qualitative variables were compared with the Chi-squared test or Fisher's exact test, as appropriate. Relationships between parameters were assessed using Spearman's correlation coefficient. All tests were two-sided and p values <0.05 were considered to be significant.

## 3. Results

Among 418 patients in whom endoscopy was performed, IDA was the main indication in 350 and chronic diarrhea in 108 patients; histological reports were available in 311 [males/females: 109/202], mean age 58 (range: 15-97) years] and 100 patients [males/females: 48/52, mean age: 55 (range: 16-86) years], respectively.

### 3.1. Total Cohort

Figure 1 summarizes the endoscopic findings in the total cohort: visual abnormalities were observed in 157 patients (34.3%) with flattening of duodenal mucosa being the most commonly observed abnormality. Visual abnormalities were more frequent among males than females (44.6% vs 33.5%,  $p=0.019$ ) and among older patients (mean age: 60 vs 56 years,  $p=0.006$ ). The rate of existence of pathologic duodenal endoscopic findings did not differ between patients having IDA as the procedures' indication in comparison to patients who underwent upper GI endoscopy due to chronic diarrhea ( $p=0.249$ ).



**Figure 1:** Abnormal Endoscopic Findings in the Total Cohort

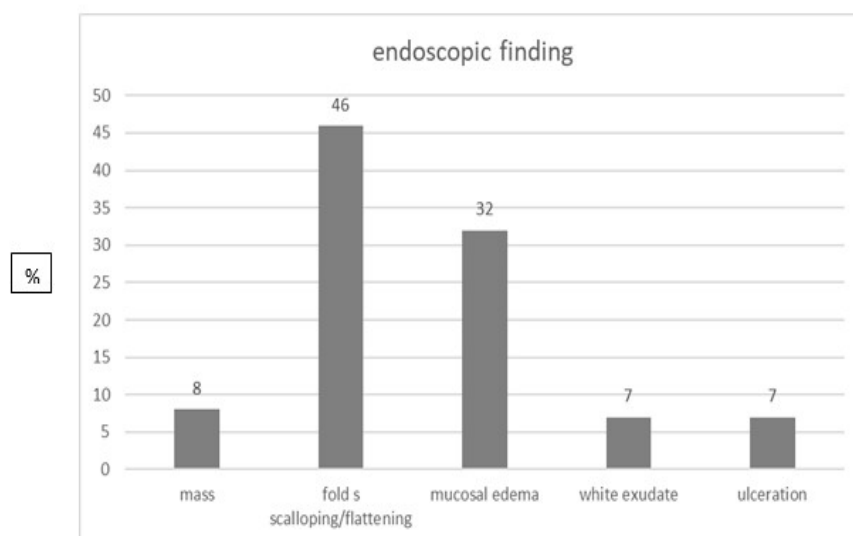
The histology report provided a conclusive diagnosis in 71/413 (17.2%) patients. Patients with a conclusive histological diagnosis tended to have older mean age (61 vs. 56 years,  $p=0.060$ ). The pathological report led to a conclusive diagnosis more frequently among patients with chronic diarrhea compared to patients with IDA (25% vs 14.8%,  $p=0.022$ ).

### 3.2. Iron Deficiency Anemia

Among 350 patients with IDA, endoscopic abnormalities were

found in 115 (32.9%), with bulb atrophy being the most common finding (Figure 2). Males compared to females tended to have more frequently visual endoscopic duodenal abnormalities (56/145 or 38.6% vs 59/204 or 28.8%,  $p=0.065$ ), while patients with pathological duodenal findings were older (mean age: 62 vs 56 years,  $p=0.001$ ). A conclusive histological diagnosis was obtained in 46 (14.8%) of 311 cases. Half of the 46 patients with a conclusive histological diagnosis were diagnosed to have CD ( $n=23$  or 50%), whereas Crohn's disease was diagnosed in only

2 cases (4.4%). A histological diagnosis was set more frequently among patients with visible duodenal abnormalities compared to patients without endoscopic findings (32/118 or 27% vs 14/195 or 7.2%,  $p<0.001$ ).

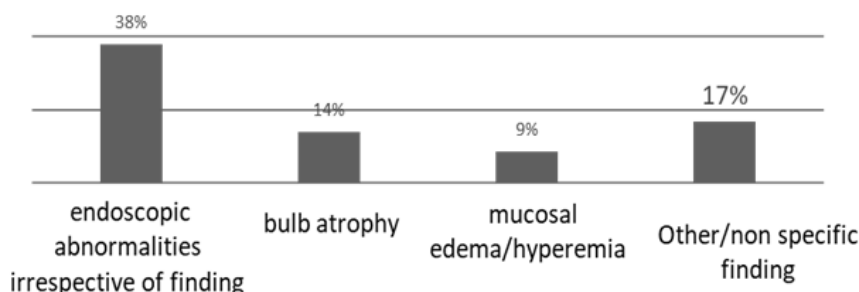


**Figure 2:** Abnormal Endoscopic Findings in Patients with IDA

### 3.3. Chronic Diarrhea

Among 108 patients with chronic diarrhea, visual duodenal abnormalities were observed in 42 (38.9%). Bulb atrophy was again the most commonly described abnormality (Figure 3). The histological report was conclusive of a specific disease in 25 (25%) of 100 cases. Among these 25 cases, the majority was diagnosed to have CD ( $n=12$  or 48%), 3 (12%) were diagnosed

to have Crohn's disease and 10 (40%) patients were found to have another diagnosis (giardia infection, drug induced enteritis, Whipple's disease, cyclostome duodenales). Among patients with chronic diarrhea, a conclusive histological diagnosis was reached more frequently in cases with compared to those without endoscopic abnormalities (18/42 or 45% vs 7/58 or 12%,  $p<0.001$ ).

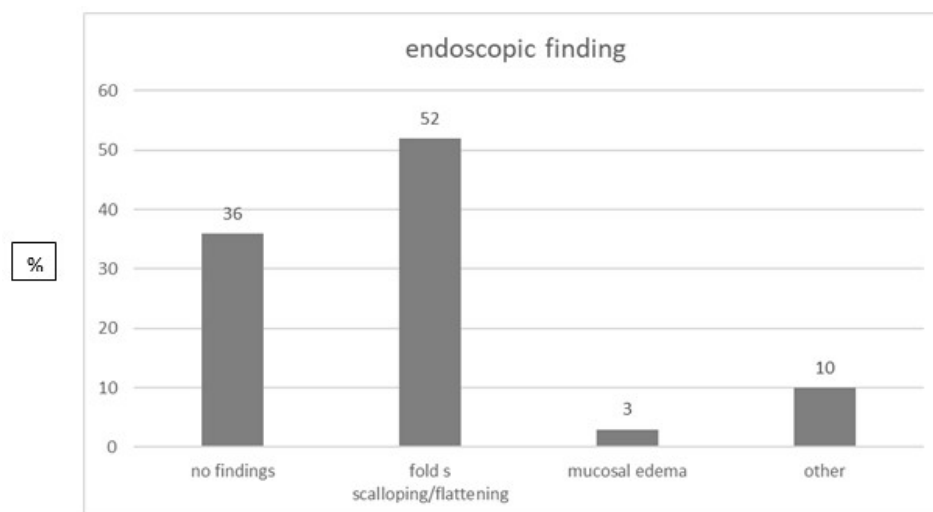


**Figure 3:** Abnormal Endoscopic Findings in Patients with Chronic Diarrhea

### 3.4. Celiac Disease

CD was diagnosed in 31 (7.54%) of the 411 patients included in our total study group. The majority of patients with CD were females (males/females: 12/19) and their mean age was 54 years (range: 18–79). A normal appearance of the duodenum was observed in 11/31 patients, whereas 16/31 patients diagnosed with CD had bulb atrophy (Figure 4). The presence of duodenal bulb atrophy in the patients of the total study group was significantly associated with the histological diagnosis of CD, as 16/63,

(25.4%) patients with bulb atrophy were diagnosed with CD compared to 15/350 (4.3%) patients with different or no endoscopic findings ( $p<0.001$ ). This observation remained among patients with IDA (12/48 or 25% vs 9/263 or 3.4%,  $p<0.001$ ) as well as among patients with chronic diarrhea (4/15 or 26.7% vs 6/85 or 7.1%,  $p=0.041$ ). In addition, bulb atrophy was observed more frequently in patients with a conclusive histological report compared to patients with other or no endoscopic findings (23/63 or 36.5% vs 48/350 or 13.7%,  $p<0.001$ ).



**Figure 4:** Endoscopic Findings in Patients with CD

#### 4. Discussion

According to our findings, duodenal biopsies may lead to a definite histological diagnosis in a significant proportion of patients with IDA or chronic diarrhea of unknown origin. More specifically, biopsy sampling could lead to a conclusive diagnosis in 14.8% of patients with IDA of unknown origin and at a much higher rate among such patients with endoscopic abnormalities. Our data disagree with a previous large German study, in which duodenal biopsies were reported to aid in the diagnosis of the cause of IDA in only 2% of patients concluding that routine duodenal biopsies cannot be recommended as a standard procedure [9]. Another small study from Turkey reported that duodenal biopsy gives an additional 5% diagnostic yield [10].

In our study, even among patients without endoscopic abnormalities, SBB sampling could lead to a conclusive diagnosis in 7.2% of patients. A more recent study focusing on the cost-effectiveness of routine duodenal sampling in patients with IDA using Markov models concluded that upper GI endoscopy with routine SBBs is a cost-effective approach with improved Quality-Adjusted Life Year (QALYs) in patients with IDA when the prevalence of CD is 5% or greater and that, in such a case, SBBs should be a routine screening tool for CD among patients with IDA, regardless of their celiac antibody status. The findings were reached even though the abovementioned study took under consideration only CD as a cause of IDA [11]. Moreover, in a recent a systematic review and meta-analysis, authors found that approximately 1 in 31 patients with IDA have histologic evidence of CD. According to the researchers, even if this prevalence value was below 5%, it justifies the practice of testing patients with IDA for CD [12].

As far as SBBs diagnostic ability in patients with chronic diarrhea is concerned, our study showed that it could lead to a conclusive diagnosis in 25% of patients. This rate is lower among patients without endoscopic abnormalities where biopsy sampling will lead to a diagnosis in 11% of such patients but it is increased to 45% among patients with endoscopic abnormalities. Once more the rate found in our study is greater than a previously reported similar rate. In a relatively old but large Spanish study including patients who underwent upper GI endoscopy with duodenal

biopsies, 8.5% of cases with chronic diarrhea were ultimately diagnosed with CD [13]. Unfortunately, even if originally 141 patients of this cohort were reported to have chronic diarrhea, no additional data were given for the diagnostic value of SBB, except for its association with CD diagnosis. In one of the few studies in this field, Indian researchers assessed the diagnosing accuracy of upper GI endoscopy in 302 patients with chronic diarrhea; they reported that a definite diagnosis was reached only in 24 (7.9%) of the 302 patients, but duodenal biopsies were obtained in only 167 (55.3%) of the 302 patients. No patient was diagnosed with CD in the latter study [14].

#### 5. Conclusion

SBB sampling can aid substantially in the diagnosis of IDA or chronic diarrhea of unknown origin even among patients without endoscopically abnormalities. Moreover, one out of three patients with endoscopic signs of duodenal atrophy will be finally diagnosed histologically with a specific disease, most commonly with CD. It must be stated that newer endoscopic visualization-magnification techniques may alter the field, although more data are needed towards that direction, up to the time that such amenities replace histopathological reports in routine clinical practice.

#### Study Limitations

Our study was retrospective and histological reports from all initially included patients could not be retrieved, whereas no other laboratory parameters or information about patients' follow-up were available.

#### References

1. Goddard, A. F., James, M. W., McIntyre, A. S., & Scott, B. B. (2011). Guidelines for the management of iron deficiency anaemia. *Gut*, 60(10), 1309-1316.
2. Shen, B., Khan, K., Ikenberry, S. O., Anderson, M. A., Banerjee, S., Baron, T., ... & Dominitz, J. A. (2010). The role of endoscopy in the management of patients with diarrhea. *Gastrointestinal endoscopy*, 71(6), 887-892.
3. Brocchi, E., Bonora, M., Epifanio, G., Tomassetti, P., Bisasco, G., & Corinaldesi, R. (2004). Routine duodenal biopsies: is it time to change our minds?. *Gastrointestinal*

- endoscopy*, 59(2), 331-332.
4. Al-Toma, A., Volta, U., Auricchio, R., Castillejo, G., Sanders, D. S., Cellier, C., ... & Lundin, K. E. (2019). European Society for the Study of Coeliac Disease (ESsCD) guideline for coeliac disease and other gluten-related disorders. *United European gastroenterology journal*, 7(5), 583-613.
  5. Ludvigsson, J. F., Bai, J. C., Biagi, F., Card, T. R., Ciacci, C., Ciclitira, P. J., ... & BSG Coeliac Disease Guidelines Development Group. (2014). Diagnosis and management of adult coeliac disease: guidelines from the British Society of Gastroenterology. *Gut*, 63(8), 1210-1228.
  6. Rubio-Tapia, A., Hill, I. D., Kelly, C. P., Calderwood, A. H., & Murray, J. A. (2013). American College of Gastroenterology clinical guideline: diagnosis and management of celiac disease. *The American journal of gastroenterology*, 108(5), 656.
  7. Talley, N. J., Weaver, A. L., Zinsmeister, A. R., & Melton III, L. J. (1992). Onset and disappearance of gastrointestinal symptoms and functional gastrointestinal disorders. *American journal of epidemiology*, 136(2), 165-177.
  8. Arasaradnam, R. P., Brown, S., Forbes, A., Fox, M. R., Hungin, P., Kelman, L., ... & Walters, J. R. (2018). Guidelines for the investigation of chronic diarrhoea in adults: British Society of Gastroenterology. *Gut*, 67(8), 1380-1399.
  9. Tischendorf, J. J., Wopp, K., Streetz, K. L., Bach, J., Meyer, M., Tischendorf, S., ... & Winograd, R. (2008). The value of duodenal biopsy within routine upper endoscopy: a prospective study in 1000 patients. *Zeitschrift für Gastroenterologie*, 46(8), 771-775.
  10. Gonen, C., Yilmaz, N., Yalcin, M., Simsek, I., & Gonen, O. (2007). Diagnostic yield of routine duodenal biopsies in iron deficiency anaemia: a study from Western Anatolia. *European journal of gastroenterology & hepatology*, 19(1), 37-41.
  11. Broide, E., Matalon, S., Kriger-Sharabi, O., Richter, V., Shirin, H., & Leshno, M. (2016). Cost effectiveness of routine duodenal biopsies in iron deficiency anemia. *World Journal of Gastroenterology*, 22(34), 7813.
  12. Mahadev, S., Laszkowska, M., Sundström, J., Björkholm, M., Lebowitz, B., Green, P. H., & Ludvigsson, J. F. (2018). Prevalence of celiac disease in patients with iron deficiency anemia—a systematic review with meta-analysis. *Gastroenterology*, 155(2), 374-382.
  13. Riestra, S., Domínguez, F., Fernández-Ruiz, E., García-Riesco, E., Nieto, R., Fernández, E., & Rodrigo, L. (2006). Usefulness of duodenal biopsy during routine upper gastrointestinal endoscopy for diagnosis of celiac disease. *World journal of gastroenterology: WJG*, 12(31), 5028.
  14. Limsrivilai, J., Sakjirapapong, C., Sattayalertyanyong, O., Geeratragool, T., Sathirawich, P., Pongpaibul, A., ... & Pausawasdi, N. (2021). Diagnostic yield of esophagogastroduodenoscopy, colonoscopy, and small bowel endoscopy in Thai adults with chronic diarrhea. *BMC gastroenterology*, 21(1), 417.